




# lichen sclerosus

## ISSVD PRACTICAL GUIDE TO DIAGNOSIS AND MANAGEMENT

Tania Day | Melissa Mauskar | Amanda Selk

September 2024





**ISBN:** 978-989-53489-8-5

**Legal deposit:** 537099/24

**DOI:** <https://doi.org/10.59153/adm.ls.001>

**Property**

ISSVD

[www.issvd.org](http://www.issvd.org)

**Edition & Pagination**

Ad Médic, Lda.

[www.admedic.pt](http://www.admedic.pt)

<b>Authors</b>	<b>13</b>
<b>Preface</b>	<b>17</b>
<b>CHAPTER 01   Pathogenesis and epidemiology</b>	<b>18</b>
Defining lichen sclerosis	18
Multifactorial pathogenesis	18
Rate estimates and age and gender distribution	19
Race and ethnicity	20
Association of lichen sclerosis with medical conditions	21
Lichen sclerosis and risk of neoplasia	22
Limitations of the literature	23
Conclusions and recommendations	23
<b>CHAPTER 02   Symptoms</b>	<b>29</b>
Asymptomatic lichen sclerosis	29
Range of symptoms	29
Limitations of the literature	31
Conclusions and recommendations	31
<b>CHAPTER 03   Examination</b>	<b>34</b>
Approach to examination	34
Vulvar findings	36
Role of colposcopy, dermoscopy, and photography	41
Assessment of severity and outcomes of treatment	42
Vulvar self-examination	42
Limitations of the literature	42
Conclusions and recommendations	43

<b>CHAPTER 04   Histopathology</b>	<b>46</b>
Clinician's approach to vulvar biopsy	46
Biopsy technique	47
Histopathology of lichen sclerosis	50
Variation in histopathologic manifestations of LS	52
Limitations of the literature	56
Conclusions and recommendations	56
<b>CHAPTER 05   Differential diagnosis and comorbid vulvar conditions</b>	<b>60</b>
Physiologic changes	60
Dermatologic conditions with architecture change	60
Dermatologic conditions that do not cause architecture change	61
Vulvar pigmented lesions	63
Infectious conditions and lichen sclerosis	64
Vaginitides	67
Psychosexual conditions	67
Neoplasia	68
Conclusions and recommendations	68
<b>CHAPTER 06   Treatment with topical corticosteroids</b>	<b>74</b>
Goals of treatment and assessment of treatment outcome	74
Primer on use of topical corticosteroids	75
Data supporting topical steroids as the mainstay of lichen sclerosis treatment	78
Initial treatment	78
Maintenance therapy	79
Adverse effects of topical steroids	80
Limited indication for cessation of topical steroids	82
Maximizing adherence and managing steroid phobia	82
Surveillance	84
Limitations of the literature	85
Conclusions and recommendations	86
<b>CHAPTER 07   General and vulvovaginal health</b>	<b>91</b>
Diet and exercise	91
Cleansing and avoidance of contact irritants and allergens	92
Toileting and bowel health	92

Clothing and undergarments	93
Hair management	93
Emollients and barrier creams	93
Vaginal and menstrual care	94
Resources for patients, social media, and support groups	96
Conclusions and recommendations	97
<b>CHAPTER 08   Psychosexual concerns and pelvic floor health</b>	<b>100</b>
Sexual impacts	100
Sex therapy, cognitive behavioral therapy, and mindfulness-based therapy	101
Comorbid depression and anxiety	102
Psychologic and interpersonal factors	103
Pelvic health physiotherapy	103
Limitations of the literature	106
Conclusions and recommendations	106
<b>CHAPTER 09   Assessment and management of non-response to topical corticosteroids</b>	<b>111</b>
Revisiting the original diagnosis	112
Categories of non-response to topical steroids	113
Generalized abnormal skin – Reasons and management	114
Focally abnormal skin – Reasons and management	117
Well controlled lichen sclerosus with persistent symptoms – Reasons and management	118
Limitations of the literature	119
Conclusions and recommendations	119
<b>CHAPTER 10   Proposed alternatives to treatment with topical corticosteroids</b>	<b>123</b>
Topical agents	123
Systemic medications	125
Medical devices and procedures	128
Limitations of the literature	131
Conclusions and recommendations	131
<b>CHAPTER 11   Neoplasia arising in lichen sclerosus</b>	<b>135</b>
Etiology of squamous neoplasia in lichen sclerosus	135
Prevention strategies for vulvar squamous neoplasia	136

Diagnosis of squamous neoplasia	138
Treatment and surveillance of neoplasia in lichen sclerosis	146
Limitations of the literature	150
Conclusions and recommendations	151
<b>CHAPTER 12   Surgery for complications of lichen sclerosis</b>	<b>157</b>
Psychosexual and musculoskeletal considerations and non-surgical management strategies	158
Preoperative considerations	158
Surgical interventions	159
Post-operative care and complications	161
Limitations of the literature	162
Conclusions and recommendations	162
<b>CHAPTER 13   Lichen sclerosis in childhood and adolescence</b>	<b>166</b>
Differences to adults in symptoms	166
Differences to adults in vulvar examination	166
Role of biopsy	168
What happens in adolescence?	169
Differences to adults in comorbid medical and dermatologic conditions	170
Treatment strategies specific to pediatric lichen sclerosis	170
Alternatives to topical steroids in children	172
Vulvar care advice specific to children	173
Long-term sequelae of undertreated pediatric lichen sclerosis	173
Limitations of the literature	174
Conclusions and recommendations	174
<b>CHAPTER 14   Lichen sclerosis during pregnancy, postpartum, and breastfeeding</b>	<b>178</b>
Lichen sclerosis during pregnancy and birth	178
Lichen sclerosis in the postpartum period	180
Lichen sclerosis during breastfeeding and estrogen supplementation	181
Limitations of the literature	182
Conclusions and recommendations	182
<b>CHAPTER 15   Lichen sclerosis and advancing age</b>	<b>184</b>
Menopause and lichen sclerosis	184
Impact of incontinence and pelvic organ prolapse on lichen sclerosis	188

Treatment considerations for lichen sclerosus with comorbidities of advancing age	190
Limitations of the literature	191
Conclusions and recommendations	192
<b>CHAPTER 16   Future directions</b>	<b>196</b>
Investigating pathogenesis to identify preventative and therapeutic targets	196
Establishing diagnostic criteria and a clinical severity scale	198
Demanding longer-term outcome data and higher quality interventional trials	198
Advocacy, education, and implementation challenges	199
Limitations of the literature	200
Conclusions and recommendations	201
<b>APPENDIX 1   Glossary of anatomic, dermatologic, and dermatopathologic terminology</b>	<b>205</b>
Vulvar anatomy	205
Dermatologic terminology	206
Dermatopathologic terminology	208



<b>CHAPTER 03   Examination</b>	<b>34</b>
Figure 1 Focal white color change at site of adherence between right labium minus and interlabial sulcus	36
Figure 2 Focal white color change at inferior inner labia minora, posterior fourchette, and perineum	36
Figure 3 Diffuse white color change over hairless and hair bearing skin from anterior commissure to perineum	36
Figure 4 Diffuse white color change over vulva, buttock, and genitocrural folds	36
Figure 5 White-pink color change and crinkly texture over inferior labia majora, perineum, and perianus	37
Figure 6 White color change and thickened texture over periclitoral structures with a vertical fissure at anterior commissure	37
Figure 7 Moderately well-demarcated circumferential erythema with edema of periclitoral structures in the setting of candida superinfection of lichen sclerosus (LS)	37
Figure 8 Thickened skin with increased skin markings and grey-pink discoloration over inferior labia majora, consistent with lichen simplex chronicus (LSC) comorbid with LS	38
Figure 9 Areas of lichenification, evidence of excoriation, and hyperkeratosis adjacent to an erosion on inner right labium minus on a background of white color change in untreated LS	38
Figure 10 Anterior architectural change with partial clitoral phimosis and total resorption of labia minora	39
Figure 11 Clitoral phimosis with clitoral pseudocyst in the setting of candidal superinfection of LS	39
Figure 12 Well-demarcated depigmented skin at outer labia majora and buttock consistent with vitiligo abutting an internal demarcation of pallor and erythema over labia majora, labia minora, perineum, and perianus consistent with LS; there are areas of near-normal pigmentation within the erythematous area	40

Figure 13	Dermoscopic findings of LS: homogeneous whitish background with white-yellowish comedo-like openings corresponding to dilated infundibula with follicular cornified plugging	41
Figure 14	Dermoscopic findings of LS: typical whitish patchy structureless areas and scattered white-yellowish comedo-like openings	41
Figure 15	Dermoscopic findings of LS: white scales at the clitoris hood with adjacent whitish patches	41
<b>CHAPTER 04  </b>	<b>Histopathology</b>	<b>46</b>
Figure 1a	Classic histopathologic appearance of LS – thinned epithelium, dermal sclerosis, and a band-like lymphocytic infiltrate; H&E x100	51
Figure 1b	Basal layer degeneration seen as vacuolar change and squamatization and edematous and hyalinized collagen change; H&E x200	51
Figure 2	LS with superimposed LSC: hyperkeratosis, hypergranulosis, acanthosis with irregular rete ridges, sclerosis, vertical papillary fibrosis, and a lymphocytic infiltrate; H&E x100	52
Figure 3	LS with superimposed LSC: marked hyperkeratosis, hypergranulosis, flat acanthosis, sclerosis, and a lymphocytic infiltrate; H&E x200	52
Figure 4	Erosive LS: loss of upper epithelium with intraepithelial neutrophils, regenerative basal layer change, edematous sclerosis, and lymphocytic infiltrate; H&E x200	53
Figure 5	Lichenoid dermatitis: thinned epithelium, basal layer degeneration, and a closely-applied band-like lymphocytic infiltrate; H&E x200	53
Figure 6	Hypertrophic lichenoid dermatitis: hyperkeratosis and parakeratosis, hypogranulosis, regular acanthosis, basal layer degeneration at tops of papillary processes, and a lymphocytic infiltrate; H&E x100	53
Figure 7a	LS with mycosis: erosion with subcorneal neutrophils, acanthosis with irregular rete ridges, sclerosis, and lymphocytic infiltrate; H&E x100	55
Figure 7b	LS with mycosis: fungal elements and neutrophils in the stratum corneum; PAS x400	55
<b>CHAPTER 06  </b>	<b>Treatment with topical corticosteroids</b>	<b>74</b>
Figure 1	One fingertip length, or 0.5g of steroid ointment. This is far more than required to cover vulvar skin.	77
Figure 2	A quarter of a fingertip unit, or a lentil-sized amount, covers hairless skin and non-keratinized squamous epithelium of the periclitoral structures, labia minora, and vestibule.	77
Figure 3	A third of a fingertip unit, or a pea-sized amount, covers hair bearing skin of labia majora, perineum, and perianus.	77

Figure 4	Signs of steroid overuse in LS: poorly-demarcated erythema, telangiectasia, and multiple large epidermal cysts	81
<b>CHAPTER 09  </b>	<b>Assessment and management of non-response to topical corticosteroids</b>	<b>111</b>
Figure 1	An algorithmic approach to non-response to topical steroids	111
<b>CHAPTER 10  </b>	<b>Proposed alternatives to treatment with topical corticosteroids</b>	<b>123</b>
Figure 1	Severe vulvar LS exposed to fractional CO2 laser with the grid-dot pattern still visible	130
<b>CHAPTER 11  </b>	<b>Neoplasia arising in lichen sclerosus</b>	<b>135</b>
Figure 1	HPV-independent (HPV-I) VIN in a field of LS with irregular red patches and white plaques on inner left labium minus and interlabial sulcus	138
Figure 2	HSIL and HPV-associated SCC in a field of LS	139
Figure 3a	Classic HPV-I VIN with thick parakeratosis, premature maturation, irregular acanthosis, acantholysis, nuclear atypia, and minimal dermal sclerosis; H&E x100	140
Figure 3b	Classic HPV-I VIN with basal overexpressed p53 pattern; x100	140
Figure 4a	Basaloid HPV-I VIN with mild flat acanthosis, minimal maturation between basal layer and surface, and nuclear atypia; H&E x200	141
Figure 4b	Basaloid HPV-I VIN with full-thickness p53 overexpression highlighting enlarged and pleomorphic nuclei; x200	141
Figure 5a	Keratinizing HSIL in LS: hyperkeratosis and parakeratosis, acanthosis with reduced rete ridges, maturation between basal layer and surface, atypical nuclei, sclerosis, and lymphocytic infiltrate; H&E x100	141
Figure 5b	Keratinizing HSIL in LS with block-positive p16, x100	141
Figure 6	Unusual acanthotic lesion in LS: thick white plaques with an irregular surface at the clitoral hood and superior labia minora	144
Figure 7a	Unusual acanthotic lesion in LS: thick hyperkeratosis, irregular acanthosis, altered maturation, and dermal fibrosis; H&E x100	144
Figure 7b	Unusual acanthotic lesion in LS: slightly enlarged vesicular nuclei of similar size and occasional mitotic figures; H&E x200	144
Figure 7c	Unusual acanthotic lesion in LS: p53 staining more than expected for wild-type but insufficient to qualify as overexpression; x200	144
Figure 8a	Subtle HPV-I VIN: thinned epithelium, normal maturation, minimal basal atypia, and sclerosis; H&E x200	147
Figure 8b	Subtle HPV-I VIN: aberrant negative p53; x200	147
Figure 9	Radiation changes in LS with induration and telangiectasia	149

**Figure 1** Prepubertal child with LS: white color change, edema, and abnormal texture ranging from crinkly to hyperkeratotic 167

**Figure 2** Pubertal child with architectural change due to LS: white color change over periclitoral structures and interlabial sulci, midline fusion of labia minora with clitoral phimosis 168

**Figure 3** Adolescent with architectural change due to LS: near normal color and texture with labial resorption and flattened prepuce 168

**Figure 4** Adolescent with LS and superimposed LSC: grey-pink color change and edema over prepuce, interlabial sulci, inner labia minora, and perineum, increased skin markings at labia majora, and thickened white color change at the anterior commissure and posterior fourchette 170

**Figure 5** Perianal telangiectasia in a prepubertal child with LS 172

**Tania Day**

Gynecology, John Hunter Hospital and University of Newcastle, Newcastle, New South Wales, Australia

**Melissa Mauskar**

Dermatology, University of Texas Southwestern, Dallas, Texas, United States of America

**Amanda Selk**

Gynecology, Women's College Hospital and Mount Sinai Hospital, University of Toronto, Toronto, Ontario, Canada

## AUTHORS (alphabetical order)

**Olushola Akinshemoyin Vaughn**

Dermatology, Medical College of Wisconsin, Milwaukee, Wisconsin, United States of America

**Veronica Boero**

Gynecology, Foundation IRCCS Ca' Granda Ospedale Maggiore Policlinico, Milan, Italy

**Alessandro Borghi**

Dermatology, University of Ferrara, Ferrara, Italy

**Katrina Bouchard**

Psychology, Department of Obstetrics & Gynecology, University of British Columbia, Vancouver, Canada

**Jennifer Bradford**

Gynecology, Sydney Adventist Hospital, Sydney, New South Wales, Australia

**Matthé Burger**

Gynecology, Academic Medical Center, Amsterdam, The Netherlands

**Carlotta Caia**

Gynecology, Foundation IRCCS Ca' Granda Ospedale Maggiore Policlinico, Milan, Italy

**Monica Corazza**

Dermatology, University of Ferrara, Ferrara, Italy

**Claire Danby**

Gynecology, Maine Medical Center and Tufts University School of Medicine, Portland, Maine, United States of America

**Shatavisha Dasgupta**

Anatomical pathology, Broad Institute of MIT and Harvard, Boston, Massachusetts, United States of America

**Emily Delpero**

Gynecology, University of Ottawa, Ottawa, Ontario, Canada

**Lois Eva**

Gynecologic oncology, Auckland City Hospital and University of Auckland, Auckland, New Zealand

**Ekene Ezenwa**

Dermatology, Northwestern University, Chicago, Illinois, United States of America

**Deana Funaro**

Dermatology, Université de Montréal, Montréal, Canada

**Andrew Goldstein**

Gynecology, Center for Vulvovaginal Disorders, Washington DC, United States of America

**Švitrigailė Grincevičienė**

Gynecology, Vilnius University, Life Sciences Centre, Institute of Biotechnology, Vilnius, Lithuania

**Pia Halonen**

Gynecology, Helsinki University Central Hospital, Helsinki, Finland

**Anna Jaeger**

Gynecologic oncology, University Medical Center Hamburg-Eppendorf and Jerusalem Hospital, Hamburg, Germany

**Carson Judkins**

Pelvic health physiotherapy, New York, New York, United States of America

**Carly Kirshen**

Dermatology, The Ottawa Hospital and University of Ottawa, Ottawa, Ontario, Canada

**Gudula Kirtschig**

Dermatology, Medical Health Centre Frauenfeld, Frauenfeld, Switzerland

**Christina Kraus**

Dermatology, University of California Irvine, Irvine, California, United States of America

**Jill Krapf**

Gynecology, Center for Vulvovaginal Disorders, Tampa, Florida, United States of America

**Jaclyn Lanthier**

Patient advocate and founder of The Lost Labia Chronicles, Toronto, Ontario, Canada

**Alicia Little**

Dermatology, Yale University, New Haven, Connecticut, United States of America

**Nina Madnani**

Dermatology, PD Hinduja National Hospital and Medical Research Centre, Mumbai, India

**Kalyani Marathe**

Pediatric dermatology, Cincinnati Children's Hospital, Cincinnati, Ohio, United States of America

**Claudia Marchitelli**

Gynecology, Hospital Italiano de Buenos Aires, Buenos Aires, Argentina

**Laura Melnik**

Dermatology, Weill Cornell Medical College, New York, New York, United States of America

**Leia Mitchell**

Physician assistant, Center for Vulvovaginal Disorders, New York, New York, United States of America

**Beth Morrel**

Gynecology, Erasmus University Medical Center, Rotterdam, The Netherlands

**Emily Murphy**

Dermatology, George Washington University, Washington DC, United States of America

**Michelle Murphy**

Dermatology, University College Cork, Cork, Ireland

**Elisabeth Quint**

Gynecology, Boston Children's Hospital and Harvard Medical School, Boston, Massachusetts, United States of America

**Sonali Patel**

Pelvic health physiotherapy, New York, New York, United States of America

**Elisa Pesce**

Gynecology, Foundation IRCCS Ca' Granda Ospedale Maggiore Policlinico, Milan, Italy

**Miriam Keltz Pomeranz**

Dermatology, New York University Grossman School of Medicine, New York, New York, United States of America

**Mario Preti**

Gynecology, Medical Oncology, University of Torino, Torino, Italy

**Sophie Rees**

Social science, University of Bristol, Bristol, United Kingdom

**Sydney Rivera Dixon**

Dermatology, University of Texas, Southwestern, Dallas, Texas, United States of America

**Natalie Saunders**

Gynecology, University of Michigan, Ann Arbor, Michigan, United States of America

**Rebecca B Saunderson**

Dermatology, Royal North Shore Hospital and University of Sydney, Sydney, New South Wales, Australia

**James Scurry**

Anatomical pathology, New South Wales Health Pathology North John Hunter Hospital and University of Newcastle, Newcastle, New South Wales, Australia

**Rosalind Simpson**

Dermatology, University of Nottingham, Nottingham, United Kingdom

**Amy Stein**

Pelvic health physiotherapy, New York, New York, United States of America

**Amy Stenson**

Gynecology, Oregon Health and Science University, Portland, Oregon, United States of America

**Dolly Taiwò**

Dermatology, Kaiser Permanente, Atlanta, Georgia, United States of America

**Irene van der Avoort**

Gynecology, Ikazia Ziekenhuis, Rotterdam, The Netherlands

**Pedro Vieira-Baptista**

Gynecology, Hospital Lusíadas Porto and Faculdade de Medicina da Universidade do Porto, Porto, Portugal

**Julieta Vera**

Gynecology, Hospital Italiano de Buenos Aires, Buenos Aires, Argentina

**Hans Verstraelen**

Gynecology, Ghent University Hospital and Ghent University, Ghent, Belgium

**Emma Veysey**

Dermatology, Royal Women's Hospital, Melbourne, Victoria, Australia

**Annarosa Virgili**

Dermatology, University of Ferrara, Ferrara, Italy

**Linn Woelber**

Gynecologic oncology, University Medical Center Hamburg-Eppendorf and Jerusalem Hospital, Hamburg, Germany



This book is dedicated to everyone affected by vulvar lichen sclerosus (LS). Our aim is to provide comprehensive education and support to all who navigate this condition, emphasizing the importance of inclusive and respectful healthcare. Throughout the book we have referred to women and girls, reflecting that most people affected by vulvar LS identify as female and this informs both our clinical experience and the scientific literature. We also recognize people with LS who identify as male or non-binary and acknowledge the challenges of their LS journey.

We wish to extend our deepest gratitude to the numerous authors and collaborators from around the globe who contributed countless hours of their expertise to this book. Your dedication and hard work have been instrumental in creating this open access resource. A special thanks goes to the International Society for the Study of Vulvovaginal Disease (ISSVD) for their unwavering support and commitment to advancing education and research in this field. For all those living with vulvar LS: your experiences and resilience inspire us every day. We hope this book will serve as a vital tool in educating healthcare providers worldwide, ultimately leading to improved patient care and better outcomes for all affected by this condition.

With sincere thanks and hopes for a brighter future,

Tania Day  
Melissa Mauskar  
Amanda Selk

# Pathogenesis and epidemiology

*Pia Halonen, Beth Morrel, Ekene Ezenwa, Monica Corazza, Melissa Mauskar*

**V**ulvar lichen sclerosis (LS) is a common chronic T-cell-mediated inflammatory dermatosis that occurs across all age groups and has major impacts on quality of life by inducing symptoms and architectural change. It is estimated to affect 1-3% of the general population, although exact prevalence is unknown.<sup>1-3</sup> As with other dermatologic autoinflammatory conditions, a comprehensive understanding of LS etiology remains elusive. Studies that document associations between LS and general medical conditions are limited by small cohort sizes, homogeneous populations, detection bias, confounding, and multiple comparisons. Increasingly, clinicians identify and treat LS before architectural change or neoplasia occurs, giving agency to prevent sequelae that previously afflicted many women with this condition.

## Defining lichen sclerosis

The disease currently called LS first appeared in medical literature in 1885 when August Breisky, a Prague-born gynecologist, reported an entity he called *kraurosis vulvae*.<sup>4</sup> His description encompassed the symptom of vulvar pruritus combined with clinical signs of white discoloration, atrophy, diminution of the labia and clitoral hood, and narrowing of the introitus.

Multiple other terms for LS have been used and abandoned to include leukoplakia, vulvar dystrophy, white spot disease, and lichen sclerosis et atrophicus.<sup>5</sup> Lichen sclerosis is a chronic T-cell-mediated disorder of genital and extragenital skin affecting people of all genders and ages.<sup>6</sup> Female genital LS may involve the vulva, perineum, anus, genitocrural folds, buttocks, and thighs.<sup>7</sup> While clinical signs and histopathologic features are usually distinct from other vulvar dermatoses, the most distinguishing characteristic of LS is white crinkly texture change.

## Multifactorial pathogenesis

Lichen sclerosis involves two parallel processes: a lichenoid tissue reaction and dermal sclerosis (see Chapter 4). The lichenoid tissue reaction results from T-cell-mediated attack on basilar keratinocytes and appears as a band-like lymphocytic infiltrate with evidence of basal layer damage. Stromal changes begin as an outpouring of fibrin-rich exudate from blood vessels into the dermis, which appears as edema.<sup>8</sup> Dehydration and cross-linking of fibrin leads to sclerosis. Fibrosis occurs when fibrin strands are replaced by thick collagen fibers.

Current knowledge points to a multifactorial pathogenesis of LS that includes genetic, immunological, hormonal, and environmental factors.<sup>5,9</sup> Reactive oxygen species and tissue damage may expose new epitopes that encourage autoantibody formation, especially ECM-1.<sup>9</sup> Women with LS endorse a familial history in 12%, rising to 20% among those with childhood onset.<sup>10,11</sup> Genes identified in affected family members potentially implicated in LS development include CD177 (neutrophil activation), CD200 (inhibitory signal to macrophages), ANKRD18A (ankyrin repeat protein, epigenetic regulation), and LATS2 (co-repressor of androgen signaling).<sup>12</sup> MicroRNAs such as MiR-155 regulate gene expression and are overexpressed in LS, leading to disruption in the self-tolerance function of T regulatory cells.<sup>6,13</sup> Concerned patients with LS may ask if their daughters or nieces will inherit the condition. Clinicians may provide reassurance that LS is not directly heritable but at least 10% of LS patients have an affected family member, so educating loved ones about vulvar health may encourage young people to disclose symptoms and seek help.

The vulvar microbiome in LS is different from controls, but it is unknown if this is cause or consequence of the disease process.<sup>14,15</sup> The genital environment is a contributor to LS development, with transplantation of unaffected skin onto the vulva often resulting in de-novo LS at that site.<sup>16</sup> Microtrauma from heat, friction, and moisture may represent a Koebner phenomenon that generates LS in susceptible patients.<sup>17</sup> In boys and men, urinary occlusion is proposed as a pathogenic factor that may be relieved by circumcision, although true curative rates for this procedure are unclear.<sup>18</sup> Multiple theories have been advanced for an infectious etiology of LS, ranging from *Borrelia burgdorferi* to human papillomavirus (HPV) to hepatitis C virus, all of which were subsequently dismissed.<sup>5,7</sup> Patients may ask if someone gave them the disease, and clinicians may inform them that LS is neither infectious nor transmissible through touch or sexual contact.

The high female-to-male ratio and premenarchal and postmenopausal incidence peaks have driven hypotheses of hormonal influences on LS development.<sup>17,19,20</sup> Androgen receptors appear diminished in sclerotic LS compared to skin showing a lichenoid tissue reaction.<sup>21</sup> Postmenopausal women with vulvar LS have increased progesterone and decreased estrone in groin skin samples compared to controls, which normalize after treatment.<sup>14</sup> Meanwhile, serum estrone is higher in LS patients than controls, suggesting a role for local rather than systemic hormonal factors.<sup>14</sup> It remains unclear how local hormone production and inflammation influence initiation, perpetuation, and severity of LS.

## Rate estimates and age and gender distribution

Lichen sclerosus is a common skin disorder in women. Estimating the true prevalence is difficult for multiple reasons: asymptomatic status of some LS patients, historical under-reporting of genital symptoms, inadequate access of diverse populations to medical care, under-recognition by clinicians, misdiagnosis, non-diagnostic biopsy, and limited research funding for vulvovaginal diseases.<sup>22-24</sup> Clinicians caring for LS are diffused across dermatology, gynecology, sexual health, urology, pediatrics, geriatrics, and primary care.<sup>1</sup> Historic lack of multidisciplinary collaboration and data sharing further complicates efforts to document the population impacts of this disease.

A prevalence of 0.05% was found among 21 million privately insured American women in 2015-2017.<sup>1</sup> Investigators calculated a prevalence of 0.18% among 250,000 women living in a single university hospital catchment.<sup>25</sup> Other estimates differ markedly because of varied study populations with rates of 25-65% in a specialized vulvar clinic, 3% among women living in longterm care, and 1.7% in a private gynecology clinic.<sup>3,26-28</sup>

Incidence of LS was estimated in a population-based study, which included all women with a clinical or histological diagnosis of LS between 2003 and 2012 in Finland.<sup>2</sup> The age-adjusted incidence rate showed a rising trend over the study period from 14 per 100,000 woman-years in 2003 to 22 per 100,000 woman-years in 2012. The likelihood of a LS diagnosis by age 80 was 1.6%.<sup>2</sup> A Dutch study of histological LS diagnoses in women from two provinces between 1991-2011 likewise showed a growing incidence.<sup>29</sup> This rise likely reflects improved detection but may also relate to increasing longevity and changes in exposures contributing to LS development.

Older observational studies describe a bimodal distribution of LS diagnosis with peaks during prepubertal or peri- and postmenopausal life phases.<sup>22,30</sup> The estimated prevalence of LS in premenarchal children is 1 in 900.<sup>31</sup> Patients diagnosed before puberty usually continue to have symptoms or signs of the disease as adults (see Chapter 13).<sup>11,32</sup> The focus on these populations may overshadow the incidence of LS in reproductive-age women and contribute to underrecognition in this group. Among patients attending vulvar clinics for LS care, 16-31% are reproductive-age women.<sup>1,33,34</sup> Diagnostic delay is common in this cohort, with younger women reporting multiple alternate diagnoses before LS is identified and treated.<sup>22,23,35-37</sup> The delay may arise from a more subtle appearance of LS in younger women, but likely also reflects entrenched clinician biases that LS is a postmenopausal phenomenon.

LS also affects men and boys with an estimated incidence of less than 0.1%.<sup>33,38</sup> There are at least three published cases of LS affecting transgender patients, but this is likely underreported.<sup>39-41</sup> These patients face body image dissatisfaction, which is closely tied to gender dysphoria, anxiety, depression, and barriers to seeking care.<sup>42</sup> Lichen sclerosus may occur in the neo-vulva formed from scrotal skin, an area not commonly affected in men.<sup>39,40</sup> Clinicians caring for transgender people may identify LS distributions distinct from those of classically described vulvar LS.

## Race and ethnicity

Lichen sclerosus affects patient populations worldwide but is said to predominantly occur in white women. The largest published LS cohorts arise from Australia, Europe, and North America. However, researchers in east and south Asia, Latin America, and the Middle East document the occurrence of LS in their local populations.<sup>27,43-47</sup> Discrepancies in recognition and reporting may stem from systemic disparities in and access to healthcare systems, variable prioritization of women's genital and sexual concerns, inadequate funding for women's health research, and cultural differences in patient and clinician willingness to acknowledge vulvar symptoms and undertake examination. Thus, the relative prevalence of LS across countries and ethnicities remains unknown. Urban university vulvar clinics report 18-45% of their patients identify as people of color and suggest differences in clinician perception of

disease severity stratified by race.<sup>48-50</sup> Asian, Indigenous, and Pacific Islander women with LS may be underrepresented in New Zealand vulvar clinics.<sup>51</sup> Under-representation in clinical care and scientific publications likely results in a knowledge gap pertaining to the spectrum of clinical presentations, quality of life impacts, and management considerations across culturally and ethnically diverse people.

## Association of LS with medical conditions

Many women with LS ask about an autoimmune pathogenesis and any association with their other medical conditions. Clinicians may inform patients that medical science does not yet have a comprehensive understanding of why and how LS develops. The validity of associations between LS and other medical conditions has not been firmly established. Patients may benefit from reassurance that many women with LS have no systemic health problems and a diagnosis of LS does not predict the development of autoimmune or other medical conditions in future. The evidence for associations between LS and general medical problems is conflicting and methodologically variable, making it difficult to draw any conclusions about disease pathogenesis, risk mitigation, or changes to routine LS care.

## Systemic autoimmune conditions

Comorbid systemic autoimmune conditions occur in 19-28% of women with LS, but these diseases are similarly common in unaffected peri- and postmenopausal women in well-resourced countries.<sup>30,52-54</sup> An increased odds ratio has been documented in thyroid disorders, systemic lupus erythematosus, type 1 diabetes, ulcerative colitis, and Crohn's disease.<sup>33</sup> A Finnish study reported an association between celiac and Crohn's disease, but not type 1 diabetes or rheumatoid arthritis.<sup>55</sup> It remains unclear if these associations are true or if they arise from methodological biases. There is no role for routine screening of autoimmune diseases in women without attributable symptoms.<sup>56,57</sup>

## Obesity and the metabolic syndrome

There are conflicting reports on the relationship between LS and obesity, hypertension, or metabolic syndrome. Several studies reported increased odds of association of obesity, hypertension, and type 2 diabetes, while others found no relationship between these entities.<sup>58-62</sup> Authors identifying an association hypothesize this finding relates to higher systemic inflammation and decreased overall daily activity level.<sup>63</sup> Studies of associations between common entities are likely to be influenced by cohort characteristics and various forms of selection and information bias.

## Anxiety and depression

Several studies report an association between anxiety/depression and LS, with the highest prevalence found in a cross-sectional study in which 40% of 158 patients had scores consistent with depression on a screening questionnaire.<sup>64-66</sup> A case-control study in the United States found a 2.2 and 2.5-fold increase, respectively, in the odds of receiving a diagnosis

of depression or anxiety in addition to LS.<sup>64</sup> Women with LS report feelings of loneliness and isolation, but engagement with support groups may increase anxiety.<sup>67</sup> Vulvar clinicians may incorporate psychosexual screening tools into routine LS care and establish referral pathways for those with positive results (see Chapter 8).

## Urinary incontinence

Clinicians often encounter more severe LS presentations when urinary incontinence is present, but studies have failed to corroborate this association. Two population based Scandinavian studies found associations between LS and urge and stress incontinence with odds calculated at 1.8 and 4.8 respectively.<sup>55,68</sup> However, a meta-analysis of 8 studies and 1,248 LS patients found no difference in the prevalence of urinary incontinence between affected cases and controls.<sup>69</sup> The presence of urinary incontinence exacerbates LS and complicates management, so vulvar clinicians employ varied strategies to mitigate its impact and facilitate treatment of incontinence when feasible (see Chapter 15).

## Lichen sclerosus and risk of neoplasia

Among 14,030 women with LS included in a systematic review, HPV-independent (HPV-I) squamous cell carcinoma (SCC) occurred in 2.2%, HPV-I vulvar intraepithelial neoplasia (VIN) also known as differentiated VIN (dVIN) in 1.2%, and high-grade squamous intraepithelial lesion (HSIL) in 0.4%, although studies did not use p16 and p53 to confirm etiology.<sup>70</sup> The absolute risk of incident SCC arising in LS varies across clinical cohorts and is dependent on demographics, referral patterns, treatment approaches, and length of follow-up, with rates of 0% to 2.8%.<sup>71</sup> Older age, likely reflecting longer duration of LS, provides an excess risk of 463 cancers per 100,000 person-years in women 80 years or over, compared to 166/100,000 personyears in women aged 30-39.<sup>29,72</sup> While many sources identify lichen planus (LP) as associated with HPV-I VIN and SCC, this has not been effectively demonstrated. The standardized incidence ratio of vulvar SCC in Finnish patients with clinical or histologic diagnosis of LS is 33.6, compared to 1.99 with any location of LP and any histologic cancer type.<sup>72,73</sup> Incidence rates for SCC in LP were not calculable in one systematic review, while another reported SCC in 0.3% and HSIL in 1.4%.<sup>70,71</sup> It is possible that the small number of cancers attributed to LP may arise from undiagnosed comorbid LS and/or HPV-associated disease.<sup>74-76</sup>

Changing demographics, HPV vaccination, population prevalence of immunosuppression, evolving care standards for LS, and improved etiology-specific diagnosis of squamous neoplasia continue to modify the relative frequency of HPV-I and HPV-associated VIN (see Chapter 11).<sup>77-79</sup> Cohort studies of HPV-I VIN reveal the impact of new diagnostic definitions on 'incidence.' Yang and Hart provided the first comprehensive description of dVIN in 2000.<sup>80</sup> Rates of dVIN began to rise about a decade later. An Italian study reported 64% (49/76) of dVIN diagnoses were made after 2011.<sup>81</sup> A Dutch database analysis identified 11 cases between 1991-2000, 12 during 2001-2010, and 91 cases from 2011-2019.<sup>29</sup> The 300% rise in dVIN incidence reported in a national database study is based on one diagnosis made between 1991-1995 and 18 diagnoses made between 2006-2010.<sup>82</sup> This study also undertook p16 and p53 immunohistochemistry in precursor lesions and reported 85% of HPV-I VIN

cases were originally misdiagnosed as HSIL. Unless historic cases all have histopathologic and immunohistochemical reassessment, it is impossible to calculate the incidence of HPV-I neoplasia using data collected before 2010.

Many studies document comorbidity of LS and oncogenic HPV, but the incidence is unknown.<sup>15,83–85</sup> Oncogenic HPV occurs in at least 10% of unvaccinated women, while LS is present in 1–3% of the female population.<sup>33,85,86</sup> The microbiome of women with LS appears to have higher rates of low- and high-risk HPV than controls.<sup>15</sup> In one cohort of LS documented by coding, 2.4% had previous vulvar HSIL and another 2.4% had cervicovaginal HSIL or SCC.<sup>68</sup> Rare LS patients have concurrent or consecutive HPV-I and HPV-associated neoplasia.<sup>76,87</sup> The reasons underlying the association between LS and HPV are unclear - it may reflect confounding by comorbid medical conditions, genetic predisposition to skin cancers, enhanced HPV entry and ineffective immune response in damaged skin, and/or the impact of topical corticosteroids.<sup>15,78,88</sup>

Counseling around prevention of squamous neoplasia is a component of the education provided at time of LS diagnosis or initial consultation. Patients may express a concern that LS is a ‘precancer’ or that development of SCC is inevitable. Clinician-led discussions must balance the reality of a <3% risk of neoplasia with reassurance that long-term adherence to treatment and surveillance reduces that risk.<sup>34,89,90</sup> The risk of cancer may serve to motivate asymptomatic patients to continue treatment and encourage women to maintain vulvar awareness with selfexamination (see Chapter 11).

## Limitations of the literature

The complex and multifactorial nature of LS etiology makes it a challenging area of scientific investigation. Epidemiologic study of LS remains limited by worldwide inequities in women’s health care, underdiagnosis by clinicians, and non-generalizability of study populations. Associations between LS and other medical conditions documented in observational studies may be spurious due to selection and information bias, or indirect due to confounding.<sup>91</sup> The Lichen Sclerosus Priority Setting Partnership highlights the persistent knowledge gaps in this area, with 5 of the top 20 research questions addressing genetic and hormonal influences on LS initiation, prevention of LS development, and links to other conditions.<sup>92</sup> Providing answers will likely require a combination of research approaches, to include basic science, translational work, and well-funded international collaborations to co-analyze multiple large datasets.

## Conclusions and recommendations

Lichen sclerosus is a chronic inflammatory dermatosis that occurs across all ages, genders, ethnicities, and health statuses. Many of the questions commonly asked by LS patients about etiology, prevalence, and associations do not have straightforward answers. Clinicians aim to inform women with LS that it is common, the condition is not infectious, they did not cause it to occur, and there is no requirement to screen for autoimmune or other medical disorders. A discussion of neoplasia and LS serves to educate regarding baseline risk and mechanisms of prevention while promoting self-efficacy in treatment and follow-up.

- Clinicians should use empathetic language and counseling to help normalize LS as a common skin condition affecting a wide range of people across the world.
- Encourage LS patients to educate their family and friends about the condition and advise their loved ones to attend a knowledgeable health care professional if they have vulvar symptoms or notice skin changes.
- Identification of squamous neoplasia etiology as HPV-independent or HPV-associated is essential to our understanding of cancer epidemiology, prevention, treatment, and surveillance.

## References

1. Melnick LE, Steuer AB, Bieber AK, Wong PW, Pomeranz MK. Lichen sclerosis among women in the United States. *Int J Womens Dermatol*. 2020;6(4):260-262. doi:10.1016/j.ijwd.2020.05.001
2. Halonen P, Jakobsson M, Heikinheimo O, Gissler M, Pukkala E. Incidence of lichen sclerosis and subsequent causes of death: a nationwide Finnish register study. *BJOG Int J Obstet Gynaecol*. 2020;127(7):814-819. doi:10.1111/1471-0528.16175
3. Leibovitz A, Kaplun V, Saposhnicov N, Habet B. Vulvovaginal examinations in elderly nursing home women residents. *Arch Gerontol Geriatr*. 2000;31(1):1-4. doi:10.1016/s0167-4943(00)00059-5
4. Breisky A. Ein wenig beobachtet Form von Hautatrophie am Pudendum muliebre. *Z Heilk*. 1885;(6):69-80.
5. De Luca DA, Papara C, Vorobyev A, et al. Lichen sclerosis: The 2023 update. *Front Med*. 2023;10:1106318. doi:10.3389/fmed.2023.1106318
6. Terlou A, Santegoets LAM, van der Meijden WI, et al. An autoimmune phenotype in vulvar lichen sclerosis and lichen planus: a Th1 response and high levels of microRNA-155. *J Invest Dermatol*. 2012;132(3 Pt 1):658-666. doi:10.1038/jid.2011.369
7. Fistarol SK, Itin PH. Diagnosis and treatment of lichen sclerosis: an update. *Am J Clin Dermatol*. 2013;14(1):27-47. doi:10.1007/s40257-012-0006-4
8. Baird P. *Lichen Sclerosis et Atrophicus*. dissertation. University of Sydney; 1981.
9. Corazza M, Schettini N, Zedde P, Borghi A. Vulvar Lichen Sclerosis from Pathophysiology to Therapeutic Approaches: Evidence and Prospects. *Biomedicines*. 2021;9(8):950. doi:10.3390/biomedicines9080950
10. Sherman V, McPherson T, Baldo M, Salim A, Gao XH, Wojnarowska F. The high rate of familial lichen sclerosis suggests a genetic contribution: an observational cohort study. *J Eur Acad Dermatol Venereol JEADV*. 2010;24(9):1031-1034. doi:10.1111/j.1468-3083.2010.03572.x
11. Morrel B, Van Der Avoort IAM, Ewing-Graham PC, et al. Long-term consequences of juvenile vulvar lichen sclerosis: A cohort study of adults with a histologically confirmed diagnosis in childhood or adolescence. *Acta Obstet Gynecol Scand*. 2023;102(11):1469-1478. doi:10.1111/aogs.14668
12. Haefner HK, Welch KC, Rolston AM, et al. Genomic Profiling of Vulvar Lichen Sclerosis Patients Shows Possible Pathogenetic Disease Mechanisms. *J Low Genit Tract Dis*. 2019;23(3):214-219. doi:10.1097/LGT.0000000000000482
13. Tran DA, Tan X, Macri CJ, Goldstein AT, Fu SW. Lichen Sclerosis: An autoimmunopathogenic and genomic enigma with emerging genetic and immune targets. *Int J Biol Sci*. 2019;15(7):1429-1439. doi:10.7150/ijbs.34613
14. Pyle HJ, Evans JC, Artami M, et al. Assessment of the Cutaneous Hormone Landscapes and Microbiomes in Vulvar Lichen Sclerosis. *J Invest Dermatol*. Published online February 2024:S0022202X24001118. doi:10.1016/j.jid.2024.01.027
15. Pagan L, Huisman BW, van der Wurff M, et al. The vulvar microbiome in lichen sclerosis and high-grade intraepithelial lesions. *Front Microbiol*. 2023;14:1264768. doi:10.3389/fmicb.2023.1264768
16. Abramov Y, Elchalal U, Abramov D, Goldfarb A, Schenker JG. Surgical Treatment of Vulvar Lichen Sclerosis: A Review. *Obstet Gynecol Surv*. 1996;51(3):193-199. doi:10.1097/00006254-199603000-00023
17. Powell JJ, Wojnarowska F. Lichen sclerosis. *Lancet Lond Engl*. 1999;353(9166):1777-1783. doi:10.1016/s0140-6736(98)08228-2
18. Snodgrass W, Blanquel JS, Bush NC. Recurrence after management of meatal balanitis xerotica obliterans. *J Pediatr Urol*. 2017;13(2):204.e1-204.e6. doi:10.1016/j.jpuro.2016.10.014
19. Kumar KS, Morrel B, Van Hees CLM, Van Der Toorn F, Van Dorp W, Mendels EJ. Comparison of lichen sclerosis in boys and girls: A systematic literature review of epidemiology, symptoms, genetic background, risk factors, treatment, and prognosis. *Pediatr Dermatol*. 2022;39(3):400-408. doi:10.1111/pde.14967



20. Wakelin SH, Marren P. Lichen sclerosus in women. *Clin Dermatol.* 1997;15(1):155-169. doi:10.1016/s0738-081x(96)00118-6
21. Clifton MM, Garner IB, Kohler S, Smoller BR. Immunohistochemical evaluation of androgen receptors in genital and extragenital lichen sclerosus: evidence for loss of androgen receptors in lesional epidermis. *J Am Acad Dermatol.* 1999;41(1):43-46. doi:10.1016/s0190-9622(99)70404-4
22. Cooper SM, Gao XH, Powell JJ, Wojnarowska F. Does treatment of vulvar lichen sclerosus influence its prognosis? *Arch Dermatol.* 2004;140(6):702-706. doi:10.1001/archderm.140.6.702
23. Kolitz E, Gammon L, Mauskar M. Vulvar lichen sclerosus in women of reproductive age. *Proc Bayl Univ Med Cent.* 2021;34(3):349-351. doi:10.1080/08998280.2021.1885093
24. Day T, Selim MA, Allbritton JI, Scurry J, Committee (DPDC) for the IDPD. Nonsclerotic Lichen Sclerosus: Definition of a Concept and Pathologic Description. *J Low Genit Tract Dis.* 2023;27(4):358. doi:10.1097/LGT.0000000000000760
25. Hieta N, Rintala M, Söderlund JM, Samu K, Orte K, Hietanen S. Comorbidity of Dermal and Cardiovascular Disorders with Lichen Sclerosus: A Case-control Study. *Acta Derm Venereol.* 2021;101(11):adv00594. doi:10.2340/actadv.101.433
26. Scurry J, Campion M, Scurry B, Kim SN, Hacker N. Pathologic Audit of 164 Consecutive Cases of Vulvar Intraepithelial Neoplasia. *Int J Gynecol Pathol.* 2006;25(2):176-181. doi:10.1097/01.pgp.0000189238.19027.df
27. Goncalves DLM, Romero RL, Ferreira PL, Santi CG. Clinical and epidemiological profile of patients attended in a vulvar clinic of the dermatology outpatient unit of a tertiary hospital during a 4-year period. *Int J Dermatol.* 2019;58(11):1311-1316. doi:10.1111/ijd.14442
28. Goldstein AT, Marinoff SC, Christopher K, Srodon M. Prevalence of vulvar lichen sclerosus in a general gynecology practice. *J Reprod Med.* 2005;50(7):477-480.
29. Bleeker MCG, Visser PJ, Overbeek LIH, van Beurden M, Berkhof J. Lichen Sclerosus: Incidence and Risk of Vulvar Squamous Cell Carcinoma. *Cancer Epidemiol Biomark Prev Publ Am Assoc Cancer Res Cosponsored Am Soc Prev Oncol.* 2016;25(8):1224-1230. doi:10.1158/1055-9965.EPI-16-0019
30. Thomas RHM, Ridley CM, Mcgibbon DH, Black MM. Lichen sclerosus et atrophicus and autoimmunity—a study of 350 women. *Br J Dermatol.* 1988;118(1):41-46. doi:10.1111/j.1365-2133.1988.tb01748.x
31. Powell J, Wojnarowska F. Childhood vulvar lichen sclerosus: an increasingly common problem. *J Am Acad Dermatol.* 2001;44(5):803-806. doi:10.1067/mjd.2001.113474
32. Boero V, Cavalli R, Caia C, et al. Pediatric vulvar lichen sclerosus: Does it resolve or does it persist after menarche? *Pediatr Dermatol.* 2023;40(3):472-475. doi:10.1111/pde.15308
33. Gulin SJ, Lundin F, Seifert O. Comorbidity in patients with Lichen sclerosus: a retrospective cohort study. *Eur J Med Res.* 2023;28(1):338. doi:10.1186/s40001-023-01335-9
34. Lee A, Bradford J, Fischer G. Long-term Management of Adult Vulvar Lichen Sclerosus: A Prospective Cohort Study of 507 Women. *JAMA Dermatol.* 2015;151(10):1061-1067. doi:10.1001/jamadermatol.2015.0643
35. Krapf JM, Smith AB, Cigna ST, Goldstein AT. Presenting Symptoms and Diagnosis of Vulvar Lichen Sclerosus in Premenopausal Women: A Cross-Sectional Study. *J Low Genit Tract Dis.* 2022;26(3):271-275. doi:10.1097/LGT.0000000000000679
36. Rivera S, Dykstra C, Flood A, Herbenick D, DeMaria AL. “Worse Than Disappointing”: Prediagnostic Health Care Challenges of Women With Inflammatory Vulvar Dermatoses. *J Low Genit Tract Dis.* 2022;26(1):53-59. doi:10.1097/LGT.0000000000000632
37. Di Giuseppe J, Delli Carpini G, Giannella L, et al. A Longitudinal Multiinstitutional Study of Vulvar Lichen Sclerosus: From Childhood to Perimenopause. *J Low Genit Tract Dis.* 2024;28(3):276-281. doi:10.1097/LGT.0000000000000816
38. Nelson DM, Peterson AC. Lichen sclerosus: epidemiological distribution in an equal access health care system. *J Urol.* 2011;185(2):522-525. doi:10.1016/j.juro.2010.09.107
39. Chaudhry SI, Craig P, Calonje E, Neill SM. Genital lichen sclerosus in a case of male-to-female gender reassignment. *Clin Exp Dermatol.* 2006;31(5):656-658. doi:10.1111/j.1365-2230.2006.02176.x
40. McMurray SL, Overholser E, Patel T. A Transgender Woman With Anogenital Lichen Sclerosus. *JAMA Dermatol.* 2017;153(12):1334-1335. doi:10.1001/jamadermatol.2017.3071
41. Imhof RL, Davidge-Pitts CJ, Miest RYN, Nippoldt TB, Tollefson MM. Dermatologic disorders in transgender patients: A retrospective cohort of 442 patients. *J Am Acad Dermatol.* 2020;83(5):1516-1518. doi:10.1016/j.jaad.2020.06.074
42. Yeung H, Kahn B, Ly BC, Tangpricha V. Dermatologic Conditions in Transgender Populations. *Endocrinol Metab Clin North Am.* 2019;48(2):429-440. doi:10.1016/j.ecl.2019.01.005
43. He Y, Liu L, Yang K, et al. Quality of life and burden of disease of vulvar lichen sclerosus: A single-center retrospective study in China. *Int J Gynecol Obstet.* Published online December 26, 2023;ijgo.15300. doi:10.1002/ijgo.15300

44. Athota K, Kolalapudi S. Vulvar lichen sclerosis in children: A prospective study over a 3 year period. *Indian J Paediatr Dermatol.* 2021;22(2):131. doi:10.4103/ijpd.ijpd\_153\_20
45. Naswa S, Marfatia Y. Physician-administered clinical score of vulvar lichen sclerosis: A study of 36 cases. *Indian J Sex Transm Dis AIDS.* 2015;36(2):174. doi:10.4103/0253-7184.167169
46. Umarji S, Ravikumar G, Antony M, Tirumalae R. Comparison of clinical diagnosis with histopathology in inflammatory skin diseases: a retrospective study of 455 cases. *Egypt J Dermatol Venerol.* 2018;38(1):37. doi:10.4103/ejdv.ejdv\_62\_16
47. Knio Z, Kurban M, Abbas O. Lichen sclerosis: clinicopathological study of 60 cases from Lebanon. *Int J Dermatol.* 2016;55(10):1076-1081. doi:10.1111/ijd.13336
48. Menta N, Nussbaum D, Khilnani A, Dowlut-McElroy T, Habeshian KA. Insights from a joint pediatric dermatology-gynecology vulvar clinic: A retrospective study. *Pediatr Dermatol.* 2024;41(1):41-45. doi:10.1111/pde.15489
49. Ngo M, Chang H, Carr C, Barnard A, Reisch J, Mauskar M. Patient Questionnaire Responses Predict Severe Clinical Signs in Patients with Vulvar Lichen Sclerosis: A retrospective cohort study. *J Am Acad Dermatol.* Published online April 2024:S0190962224006649. doi:10.1016/j.jaad.2024.04.046
50. Thyagarajan A, Prasad R, Menta N, Habeshian K, Dowlut-McElroy T. 112. Racial Differences in the Diagnosis of Juvenile Vulvar Lichen Sclerosis: A Retrospective Cohort Study. *J Pediatr Adolesc Gynecol.* 2024;37(2):293-294. doi:10.1016/j.jpjg.2024.01.119
51. Cheng HS, Kerckhoffs C, Perkins N, Eva L. Demographics of New Zealand women with vulval lichen sclerosis: is specialist care equitable? *N Z Med J.* 2020;133(1517):24-31.
52. Desai MK, Brinton RD. Autoimmune Disease in Women: Endocrine Transition and Risk Across the Lifespan. *Front Endocrinol.* 2019;10:265. doi:10.3389/fendo.2019.00265
53. Kreuter A, Wischnewski J, Terras S, Altmeyer P, Stücker M, Gambichler T. Coexistence of lichen sclerosis and morphea: A retrospective analysis of 472 patients with localized scleroderma from a German tertiary referral center. *J Am Acad Dermatol.* 2012;67(6):1157-1162. doi:10.1016/j.jaad.2012.04.003
54. Cooper SM, Ali I, Baldo M, Wojnarowska F. The association of lichen sclerosis and erosive lichen planus of the vulva with autoimmune disease: a case-control study. *Arch Dermatol.* 2008;144(11):1432-1435. doi:10.1001/archderm.144.11.1432
55. Halonen P, Heikinheimo O, Hadkhale K, Gissler M, Pukkala E, Jakobsson M. Risk Factors for Lichen Sclerosis: A Case-Control Study of 43,000 Finnish Women. *J Low Genit Tract Dis.* 2024;28(2):164-168. doi:10.1097/LGT.0000000000000796
56. Lewis FM, Tatnall FM, Velangi SS, et al. British Association of Dermatologists guidelines for the management of lichen sclerosis, 2018. *Br J Dermatol.* 2018;178(4):839-853. doi:10.1111/bjd.16241
57. Kirtschig G, Kinberger M, Kreuter A, et al. EuroGuiDerm Guideline: Lichen Sclerosis. Published online 2023. Accessed March 9, 2024. <https://www.guidelines.edf.one/edf-guidelines-and-consensus-statements>
58. Higgins CA, Cruickshank ME. A population-based case-control study of aetiological factors associated with vulval lichen sclerosis. *J Obstet Gynaecol J Inst Obstet Gynaecol.* 2012;32(3):271-275. doi:10.3109/01443615.2011.649320
59. Virgili A, Borghi A, Cazzaniga S, et al. New insights into potential risk factors and associations in genital lichen sclerosis: Data from a multicentre Italian study on 729 consecutive cases. *J Eur Acad Dermatol Venereol.* 2017;31(4):699-704. doi:10.1111/jdv.13867
60. Sideri M, Parazzini F, Rognoni MT, et al. Risk factors for vulvar lichen sclerosis. *Am J Obstet Gynecol.* 1989;161(1):38-42. doi:10.1016/0002-9378(89)90228-7
61. Luu Y, Cheng AL, Reisz C. Elevated body mass index, statin use, and cholecystectomy are associated with vulvar lichen sclerosis: A retrospective, case-control study. *J Am Acad Dermatol.* 2023;88(6):1376-1378. doi:10.1016/j.jaad.2023.01.023
62. Liu L, Zhang Q, Chang J, Yang K. Causal Association Between Diabetes, Body Mass Index and Lichen Sclerosis: A Bidirectional Two-Sample Mendelian Randomization Analysis. *Clin Cosmet Investig Dermatol.* 2024;17:931-940. doi:10.2147/CCID.S450399
63. Ranum A, Freese R, Ramesh V, Pearson DR. Lichen sclerosis in female patients is associated with an increased risk of metabolic syndrome and cardiovascular comorbidities: a retrospective cohort review. *Br J Dermatol.* 2022;187(6):1030-1032. doi:10.1111/bjd.18111
64. Fan R, Leasure AC, Maisha FI, Little AJ, Cohen JM. Depression and Anxiety in Patients With Lichen Sclerosis. *JAMA Dermatol.* 2022;158(8):953. doi:10.1001/jamadermatol.2022.1964
65. Shasi PB, Chapman HT, Evans DTP, Jaleel H. Psychological and psychiatric morbidity in lichen sclerosis in a cohort recruited from a genitourinary medicine clinic. *Int J STD AIDS.* 2010;21(1):17-18. doi:10.1258/ijsa.2009.009102
66. Vittrup G, Mørup L, Heilesen T, Jensen D, Westmark S, Melgaard D. Quality of life and sexuality in women with lichen sclerosis: a cross-sectional study. *Clin Exp Dermatol.* 2022;47(2):343-350. doi:10.1111/ced.14893

67. Arnold S, Fernando S, Rees S. Living with vulvar lichen sclerosis: a qualitative interview study. *Br J Dermatol*. 2022;187(6):909-918. doi:10.1111/bjd.21777
68. Söderlund JM, Hieta NK, Kurki SH, et al. Comorbidity of Urogynecological and Gastrointestinal Disorders in Female Patients With Lichen Sclerosis. *J Low Genit Tract Dis*. 2023;27(2):156-160. doi:10.1097/LGT.0000000000000727
69. Kirby L, Gran S, Kreuser-Genis I, Owen C, Simpson R. Is urinary incontinence associated with lichen sclerosis in females? A systematic review and meta-analysis. *Skin Health Dis*. 2021;1(1):e13. doi:10.1002/ski2.13
70. Vieira-Baptista P, Pérez-López FR, López-Baena MT, Stockdale CK, Preti M, Bornstein J. Risk of Development of Vulvar Cancer in Women With Lichen Sclerosis or Lichen Planus: A Systematic Review. *J Low Genit Tract Dis*. 2022;26(3):250-257. doi:10.1097/LGT.0000000000000673
71. Leis M, Singh A, Li C, Ahluwalia R, Fleming P, Lynde CW. Risk of Vulvar Squamous Cell Carcinoma in Lichen Sclerosis and Lichen Planus: A Systematic Review. *J Obstet Gynaecol Can JOGC J Obstet Gynecol Can JOGC*. 2022;44(2):182-192. doi:10.1016/j.jogc.2021.09.023
72. Halonen P, Jakobsson M, Heikinheimo O, Riska A, Gissler M, Pukkala E. Lichen sclerosis and risk of cancer. *Int J Cancer*. 2017;140(9):1998-2002. doi:10.1002/ijc.30621
73. Halonen P, Jakobsson M, Heikinheimo O, Riska A, Gissler M, Pukkala E. Cancer risk of Lichen planus : A cohort study of 13,100 women in Finland. *Int J Cancer*. 2018;142(1):18-22. doi:10.1002/ijc.31025
74. Lyra J, Melo C, Figueiredo R, et al. Erosive Vulvar Lichen Planus and Risk of Vulvar Neoplasia. *J Low Genit Tract Dis*. 2021;25(1):71-75. doi:10.1097/LGT.0000000000000581
75. Preti M, Micheletti L, Privitera S, et al. Vulvar Lichen Planus: A Risk Factor for Vulvar High-Grade Squamous Intraepithelial Lesion Recurrence? *J Low Genit Tract Dis*. 2018;22(3):264-265. doi:10.1097/LGT.0000000000000398
76. Lin A, Day T, Ius Y, Scurry J. Anogenital High-Grade Squamous Intraepithelial Lesion Comorbid With Vulvar Lichen Sclerosis and Lichen Planus. *J Low Genit Tract Dis*. 2020;24(3):311-316. doi:10.1097/LGT.0000000000000540
77. Eva LJ, Sadler L, Fong KL, Sahota S, Jones RW, Bigby SM. Trends in HPV-dependent and HPV-independent vulvar cancers: The changing face of vulvar squamous cell carcinoma. *Gynecol Oncol*. 2020;157(2):450-455. doi:10.1016/j.ygyno.2020.01.029
78. Thuijs NB, Van Beurden M, Duin S, et al. High-grade vulvar intraepithelial neoplasia: comprehensive characterization and long-term vulvar carcinoma risk. *Histopathology*. 2024;84(2):301-314. doi:10.1111/his.15050
79. Voss FO, Van Beurden M, Veelders KJ, et al. Incidence and Risk Factors for Recurrence and Progression of HPV-Independent Vulvar Intraepithelial Neoplasia. *J Low Genit Tract Dis*. 2024;28(2):153-159. doi:10.1097/LGT.0000000000000794
80. Yang B, Hart WR. Vulvar Intraepithelial Neoplasia of the Simplex (Differentiated) Type: A Clinicopathologic Study Including Analysis of HPV and p53 Expression. *Am J Surg Pathol*. 2000;24(3):429-441. doi:10.1097/00000478-200003000-00013
81. Gallio N, Preti M, Jones RW, et al. Differentiated vulvar intraepithelial neoplasia long-term follow up and prognostic factors: An analysis of a large historical cohort. *Acta Obstet Gynecol Scand*. 2024;103(6):1175-1182. doi:10.1111/aogs.14814
82. Thuijs NB, Van Beurden M, Bruggink AH, Steenbergen RDM, Berkhof J, Bleeker MCG. Vulvar intraepithelial neoplasia: Incidence and long-term risk of vulvar squamous cell carcinoma. *Int J Cancer*. 2021;148(1):90-98. doi:10.1002/ijc.33198
83. van der Avoort I a. M, Shirango H, Hoevenaars BM, et al. Vulvar squamous cell carcinoma is a multifactorial disease following two separate and independent pathways. *Int J Gynecol Pathol Off J Int Soc Gynecol Pathol*. 2006;25(1):22-29. doi:10.1097/01.pgp.00001177646.38266.6a
84. Aidé S, Lattario FR, Almeida G, do Val IC, da Costa Carvalho M. Epstein-Barr virus and human papillomavirus infection in vulvar lichen sclerosis. *J Low Genit Tract Dis*. 2010;14(4):319-322. doi:10.1097/LGT.0b013e3181d734f1
85. Hald AK, Blaakaer J. The possible role of human papillomavirus infection in the development of lichen sclerosis. *Int J Dermatol*. 2018;57(2):139-146. doi:10.1111/ijd.13697
86. Kombe Kombe AJ, Li B, Zahid A, et al. Epidemiology and Burden of Human Papillomavirus and Related Diseases, Molecular Pathogenesis, and Vaccine Evaluation. *Front Public Health*. 2020;8:552028. doi:10.3389/fpubh.2020.552028
87. Janke MJ, DeBlanc J, Kobernik EK, et al. Comorbid Vulvar Lichen Sclerosis and High-Grade Squamous Intraepithelial Lesions: A Management Conundrum. *J Low Genit Tract Dis*. 2022;26(4):319-322. doi:10.1097/LGT.0000000000000690
88. Giuliani E, Rollo F, Cota C, et al. Alpha, Beta, and Gamma Human Papillomaviruses in Genital Lichen Sclerosis: A Retrospective Cross-Sectional Study. *J Low Genit Tract Dis*. 2023;27(3):236-241. doi:10.1097/LGT.0000000000000741
89. Cooper SM, Madhani N, Margesson L. Reduced Risk of Squamous Cell Carcinoma With Adequate Treatment of Vulvar Lichen Sclerosis. *JAMA Dermatol*. 2015;151(10):1059-1060. doi:10.1001/jamadermatol.2015.0644

90. Renaud-Vilmer C, Cavelier-Balloy B, Porcher R, Dubertret L. Vulvar lichen sclerosis: effect of long-term topical application of a potent steroid on the course of the disease. *Arch Dermatol*. 2004;140(6):709-712. doi:10.1001/archderm.140.6.709
91. Grimes DA, Schulz KF. Bias and causal associations in observational research. *Lancet Lond Engl*. 2002;359(9302):248-252. doi:10.1016/S0140-6736(02)07451-2
92. Simpson RC, Cooper SM, Kirtschig G, et al. Future research priorities for lichen sclerosis – results of a James Lind Alliance Priority Setting Partnership. *Br J Dermatol*. 2019;180(5):1236-1237. doi:10.1111/bjd.17447

# Symptoms

*Rebecca B Saunderson, Claire Danby, Sophie Rees*

**W**omen and children with vulvar lichen sclerosis (LS) may be asymptomatic or report a range of symptoms of varied type, frequency, severity, and provoking factors. Symptoms and their impacts change over the lifespan. During adulthood, the interplay between LS symptoms, sexuality, and self-image contributes to diminished quality of life (QoL). Symptom improvement in LS may occur with emollients alone or with inadequate topical steroid regimens. This does not reliably translate to adequate control of skin manifestations (see Chapter 6). When symptoms persist despite objective suppression of LS-related skin abnormalities, clinicians should assess for additional comorbid genital or psychosexual conditions (see Chapter 9).<sup>1</sup>

## Asymptomatic lichen sclerosis

The incidence of asymptomatic LS is difficult to ascertain as non-diagnosis is common due to patient and clinician unfamiliarity with the condition. Up to one third of patients identified to have LS in a general gynecology practice are asymptomatic.<sup>2</sup> In vulvar clinic settings, 10-15% of LS patients are asymptomatic. A lack of symptoms does not reliably confer reduced risk of overall disease severity, fissures, erosions, or development of neoplasia.<sup>3,4</sup> Asymptomatic status is associated with younger age, continence, and non-adherence to treatment recommendations.<sup>3,5</sup> Long-term follow-up of childhood LS suggests a quarter of these young women are asymptomatic despite clinical signs of disease.<sup>6</sup> Establishing the rate of asymptomatic vulvar LS in children is especially challenging given limitations in history-taking, diverse reasons for presentation, and frequency of unrecognized cases (see Chapter 13).<sup>7,8</sup> Several cohorts of pediatric LS report symptom-free rates between 11 and 20%.<sup>7,9-11</sup> Use of symptoms as a primary outcome measure of treatment is inappropriate given the frequency of baseline asymptomatic status and poor correlation between symptoms and disease severity.

## Range of symptoms

Children with LS most commonly report discomfort or itch, but rates of each vary dramatically across cohorts from 19 to 86% and 20 to 70% respectively.<sup>7-13</sup> Dysuria, incontinence, and/or enuresis are more often the presenting symptom in children and most studies document rates between 30 and 72%.<sup>7-9,11,12</sup> Constipation, painful defecation, and/or abdominal

pain are reported to occur in up to two thirds of children, but most studies record rates of 7 to 16%.<sup>7-9,11,12,14</sup> Up to 26% of children with LS experience bleeding or hemorrhagic lesions, which may be mistaken for sexual abuse.<sup>7,8,11,12</sup> Sleep disturbance, also called night-time waking, may accompany vulvar, urinary, or gastrointestinal discomfort and is described in other childhood vulvovaginal conditions.<sup>9,15,16</sup> There is an inverse relationship between age of symptom initiation and delay in diagnosis.<sup>17</sup> Among premenopausal women with LS, 43% recall symptoms during childhood that they attribute to the condition.<sup>17</sup> Many girls with LS experience diminished QoL that persists into early adulthood.<sup>7,13,18</sup>

Itch is the predominant symptom of LS in adults overall, reported in up to 90%.<sup>17,19,20</sup> Half of women report nocturnal exacerbation of pruritis.<sup>3,13</sup> Other provoking factors include menses in 32%, washing in 22%, use of pads/liners in 20%, and sex in 10%.<sup>3</sup> Patients may report symptom exacerbation after consumption of certain foods.<sup>3</sup> Severity of itch likely reflects a combination of endogenous tendency, irritant exposures, and LS-specific disease activity.

While pain is the next most frequent symptom in adults across the lifespan, it is the commonest symptom in reproductive age women.<sup>17,19</sup> Rates of sexual pain in premenopausal women with LS are 50 to 68%.<sup>3,17,21</sup> Other pain-related symptoms in this age group include tearing with intercourse in 63% and vulvar fissures in 72%.<sup>17</sup> Across all life stages, pain may be the only presenting complaint. Among 525 women with a median age of 49 referred to a specialized vulvar clinic for pain or dyspareunia, 16.5% had LS.<sup>21</sup>

Changes in skin color and vulvar architecture may impact on genital self-image and sexual function, prompting patients to seek medical attention.<sup>17,22</sup> A third of premenopausal women report that white color change was a reason they attended a healthcare provider.<sup>17</sup> Altered clitoral sensation was noted in 35% of reproductive-age women but was the reason for seeking care in only 6%. Anatomic change may engender a sense of profound loss and damaged femininity.<sup>23,24</sup> Women with LS report feeling self-conscious, embarrassed, and anxious about the possibility of future anatomic changes.<sup>24-26</sup> Patients express worry about pregnancy and birth and the risk of vulvar cancer.<sup>18</sup>

Several specific symptoms or historical features may predict severe clinical signs.<sup>27</sup> Dysuria is associated with neoplasia, hyperkeratosis, erosions, and fissures with odds ratios (OR) of 8, 5, 5, and 3 respectively. The sensation of needing to rub and scratch the itch predicted hyperkeratosis (OR=10) and texture change seen as fine wrinkling (OR=3). Patients with suicidal ideation were 6 times more likely to show evidence of chronic itch-scratch cycle on examination. These findings may assist in triage of outpatient referrals with regards to urgency and provider type.

Itch, pain, skin changes, and architectural alterations all contribute to impacts on QoL and sexual function (see Chapter 8). Over 75% of LS patients rate their symptoms as severe, 40% screen positive for depression, and one third have documented severe QoL impairment.<sup>19,28-30</sup> Some women with LS experience difficulty with types of clothing, exercise, and social activities.<sup>18,31,31</sup> Cycling and swimming are common areas of concern.<sup>18</sup> Patients may meticulously plan bathroom access to allow for cleansing and moisturizing after toileting.<sup>24,31,32</sup> Lack of peer awareness, delay in diagnosis, and negative experiences in the healthcare sector exac-

erbate QoL impact, engendering feelings of isolation, stigmatization, and being dismissed by healthcare providers.<sup>24,26,29</sup> Sexual dysfunction is more common in LS patients than unaffected controls, with lower scores on all subscales within the Female Sexual Functioning Index (FSFI).<sup>28,33,34</sup> Desire is less affected than arousal, lubrication, orgasm satisfaction, and pain. Poorer scores on the Female Sexual Distress Scale correlate with severity of itch and pain.<sup>33</sup> Psychosexual counseling improves FSFI and Dermatology Life Quality Index (DLQI) scores.<sup>35</sup>

Topical corticosteroid treatment improves QoL across several measurement tools, with variation by domain.<sup>25,36,37</sup> Pictorial Representation and Self-Measure (PRISM) and DLQI scores improve after 12 weeks of daily mometasone furoate ointment, with greater positive impact in those with better objective disease control.<sup>36</sup> Scores of 0 to 5 on the Vulvar Quality of Life Index (VQLI) reflecting minimal disease impact occur in 12% of women pre-treatment and 72% after individualized steroid ointment regimens.<sup>25</sup> Greater improvement occurs in symptoms and anxiety domains compared to sexual function. Adherence to the recommended steroid regimen results in 96% of women having minimal to mild impacts, but only 10% of these patients score zero reflecting no disease impact.<sup>25,37</sup> Patient-reported inconvenience of treatment negatively affects scores in the post-treatment DLQI and VQLI 'activities of daily living' domain.<sup>32,37</sup> Perceived burden of treatment is not related to frequency of steroid application, and instead may relate to steroid phobia and inappropriate messages from healthcare professionals.<sup>38</sup> Persistent impairment in QoL despite effective treatment is associated with suboptimal engagement with treatment, urinary incontinence, guilt and distress around sexuality, and anxiety around long-term health implications of LS.<sup>32</sup>

## Limitations of the literature

While many studies report rates of various symptoms, there is scant evidence documenting the complexities of overlapping symptoms, their relationship to objective disease severity or presence of comorbid conditions, and responses of each symptom to treatment. There is minimal information about how asymptomatic status affects treatment, disease progression, and risk of neoplasia. Studies are lacking to address the impact of effective multidisciplinary treatment on sexual function and genital self-image.

## Conclusions and recommendations

Lichen sclerosus manifests with a spectrum of symptom types and severities, from none to severe itch, pain, and functional limitations from architectural change. Patient experience of symptoms varies across the lifespan, but there are negative QoL sequelae across all age groups. Children experience more urinary, gastrointestinal, and sleep-related symptoms than adults. Premenopausal women are more likely to identify sexual impacts as their primary symptom, while postmenopausal women are the most likely to experience itch. Effective treatment combined with ongoing clinical support and surveillance improves symptoms and QoL in patients with LS.

- Inform asymptomatic patients that symptom status does not reliably correlate with disease activity, severity, or risk of neoplasia.
- Ask holistic questions about the patient experience of LS, tailored to the individual's life stage.

## References

1. Yeon J, Oakley A, Olsson A, et al. Vulval lichen sclerosis: An Australasian management consensus. *Australas J Dermatol*. 2021;62(3):292-299. doi:10.1111/ajd.13594
2. Goldstein AT, Marinoff SC, Christopher K, Srodon M. Prevalence of vulvar lichen sclerosis in a general gynecology practice. *J Reprod Med*. 2005;50(7):477-480.
3. Vieira-Baptista P, Lima-Silva J, Cavaco-Gomes J, Beires J, Martinez-de-Oliveira J. What Differentiates Symptomatic from Asymptomatic Women with Lichen Sclerosis? *Gynecol Obstet Invest*. 2014;79(4):263-268. doi:10.1159/000367788
4. Day T, Marzol A, Pagano R, Jaaback K, Scurry J. Clinicopathologic Diagnosis of Differentiated Vulvar Intraepithelial Neoplasia and Vulvar Aberrant Maturation. *J Low Genit Tract Dis*. 2020;24(4):392-398. doi:10.1097/LGT.0000000000000569
5. Geisler AN, Kopteyev J, Strunk A, Shah PR, Garg A. Quality of Life and Treatment Adherence in Patients with Vulvar Lichen Sclerosis. *Dermatology*. 2023;239(3):494-498. doi:10.1159/000530108
6. Boero V, Cavalli R, Caia C, et al. Pediatric vulvar lichen sclerosis: Does it resolve or does it persist after menarche? *Pediatr Dermatol*. 2023;40(3):472-475. doi:10.1111/pde.15308
7. Lagerstedt M, Karvinen K, Joki-Erkkilä M, Huotari-Orava R, Snellman E, Laasanen S. Childhood Lichen Sclerosis—A Challenge for Clinicians. *Pediatr Dermatol*. 2013;30(4):444-450. doi:10.1111/pde.12109
8. Ismail D, Owen CM. Paediatric vulval lichen sclerosis: a retrospective study. *Clin Exp Dermatol*. 2019;44(7):753-758. doi:10.1111/ced.13894
9. Kherlopian A, Fischer G. Does compliance to topical corticosteroid therapy reduce the risk of development of permanent vulvar structural abnormalities in pediatric vulvar lichen sclerosis? A retrospective cohort study. *Pediatr Dermatol*. 2022;39(1):22-30. doi:10.1111/pde.14840
10. Patrizi A, Gurioli C, Medri M, Neri I. Childhood Lichen Sclerosis: A Long-Term Follow-up. *Pediatr Dermatol*. 2010;27(1):101-103. doi:10.1111/j.1525-1470.2009.01050.x
11. Winfrey OK, Fei YF, Dendrinis ML, Rosen MW, Smith YR, Quint EH. Lichen Sclerosis throughout Childhood and Adolescence: Not Only a Premenarchal Disease. *J Pediatr Adolesc Gynecol*. 2022;35(6):624-628. doi:10.1016/j.jpag.2022.08.011
12. Jensen LS, Bygum A. Childhood lichen sclerosis is a rare but important diagnosis. *Dan Med J*. 2012;59(5):A4424.
13. He Y, Liu L, Yang K, et al. Quality of life and burden of disease of vulvar lichen sclerosis: A single-center retrospective study in China. *Int J Gynecol Obstet*. Published online December 26, 2023;ijgo.15300. doi:10.1002/ijgo.15300
14. Maronn ML, Esterly NB. Constipation as a Feature of Anogenital Lichen Sclerosis in Children. *Pediatrics*. 2005;115(2):e230-e232. doi:10.1542/peds.2004-1544
15. Dunford A, Rampal D, Kielly M, Grover SR. Vulval Pain in Pediatric and Adolescent Patients. *J Pediatr Adolesc Gynecol*. 2019;32(4):359-362. doi:10.1016/j.jpag.2019.03.005
16. Fischer G. Chronic vulvitis in pre-pubertal girls. *Australas J Dermatol*. 2010;51(2):118-123. doi:10.1111/j.1440-0960.2010.00631.x
17. Krapf JM, Smith AB, Cigna ST, Goldstein AT. Presenting Symptoms and Diagnosis of Vulvar Lichen Sclerosis in Premenopausal Women: A Cross-Sectional Study. *J Low Genit Tract Dis*. 2022;26(3):271-275. doi:10.1097/LGT.0000000000000679
18. Morrel B, Van Der Avoort IAM, Ewing-Graham PC, et al. Long-term consequences of juvenile vulvar lichen sclerosis: A cohort study of adults with a histologically confirmed diagnosis in childhood or adolescence. *Acta Obstet Gynecol Scand*. 2023;102(11):1469-1478. doi:10.1111/aogs.14668
19. Virgili A, Borghi A, Toni G, Minghetti S, Corazza M. Prospective Clinical and Epidemiologic Study of Vulvar Lichen Sclerosis: Analysis of Prevalence and Severity of Clinical Features, together with Historical and Demographic Associations. *Dermatology*. 2014;228(2):145-151. doi:10.1159/000356163
20. Lee A, Bradford J, Fischer G. Long-term Management of Adult Vulvar Lichen Sclerosis: A Prospective Cohort Study of 507 Women. *JAMA Dermatol*. 2015;151(10):1061. doi:10.1001/jamadermatol.2015.0643
21. Harris V, Fischer G, Bradford JA. The aetiology of chronic vulval pain and entry dyspareunia: a retrospective review of 525 cases. *Aust N Z J Obstet Gynaecol*. 2017;57(4):446-451. doi:10.1111/ajo.12613
22. Hodges KR, Wiener CE, Vyas AS, Turrentine MA. The Female Genital Self-image Scale in Adult Women With Vulvar Lichen Sclerosis. *J Low Genit Tract Dis*. 2019;23(3):210-213. doi:10.1097/LGT.0000000000000481
23. Sadownik LA, Koert E, Maher C, Smith KB. A Qualitative Exploration of Women's Experiences of Living With Chronic Vulvar Dermatoses. *J Sex Med*. 2020;17(9):1740-1750. doi:10.1016/j.jsexm.2020.06.016
24. Arnold S, Fernando S, Rees S. Living with vulval lichen sclerosis: a qualitative interview study. *Br J Dermatol*. 2022;187(6):909-918. doi:10.1111/bjd.21777



25. Wijaya M, Lee G, Fischer G, Lee A. Quality of Life in Vulvar Lichen Sclerosus Patients Treated With Long-Term Topical Corticosteroids. *J Low Genit Tract Dis.* 2021;25(2):158-165. doi:10.1097/LGT.0000000000000599
26. Bentham GL, Manley K, Halawa S, Biddle L. Conversations between women with vulval lichen sclerosus: a thematic analysis of online forums. *BMC Womens Health.* 2021;21(1):71. doi:10.1186/s12905-021-01223-6
27. Ngo M, Chang H, Carr C, Barnard A, Reisch J, Mauskar M. Patient Questionnaire Responses Predict Severe Clinical Signs in Patients with Vulvar Lichen Sclerosus: A retrospective cohort study. *J Am Acad Dermatol.* Published online April 2024;S0190962224006649. doi:10.1016/j.jaad.2024.04.046
28. Vittrup G, Mørup L, Heilesen T, Jensen D, Westmark S, Melgaard D. Quality of life and sexuality in women with lichen sclerosus: a cross-sectional study. *Clin Exp Dermatol.* 2022;47(2):343-350. doi:10.1111/ced.14893
29. Lansdorp CA, Van Den Hondel KE, Korfage IJ, Van Gestel MJ, Van Der Meijden WI. Quality of life in Dutch women with lichen sclerosus: Quality of life in Dutch women with lichen sclerosus. *Br J Dermatol.* 2013;168(4):787-793. doi:10.1111/bjd.12137
30. Saunderson RB, Harris V, Yeh R, Mallitt K, Fischer G. Vulvar quality of life index (VQLI) – A simple tool to measure quality of life in patients with vulvar disease. *Australas J Dermatol.* 2020;61(2):152-157. doi:10.1111/ajd.13235
31. Olsen SB, Odgaard H, Glavind K. Does treatment of lichen sclerosus improve overactive bladder symptoms? *Int Urogynecology J.* 2023;34(6):1203-1209. doi:10.1007/s00192-022-05318-y
32. Wijaya M, Lee G, Fischer G. Why do some patients with vulval lichen sclerosus on long-term topical corticosteroid treatment experience ongoing poor quality of life? *Australas J Dermatol.* 2022;63(4):463-472. doi:10.1111/ajd.13926
33. Van De Nieuwenhof HP, Meeuwis KAP, Nieboer TE, Vergeer MCM, Massuger LFAG, De Hullu JA. The effect of vulvar lichen sclerosus on quality of life and sexual functioning. *J Psychosom Obstet Gynecol.* 2010;31(4):279-284. doi:10.3109/0167482X.2010.507890
34. Pope R, Lee MH, Myers A, et al. Lichen Sclerosus and Sexual Dysfunction: A Systematic Review and Meta-Analysis. *J Sex Med.* 2022;19(11):1616-1624. doi:10.1016/j.jsexm.2022.07.011
35. Vittrup G, Westmark S, Riis J, et al. The Impact of Psychosexual Counseling in Women With Lichen Sclerosus: A Randomized Controlled Trial. *J Low Genit Tract Dis.* 2022;26(3):258-264. doi:10.1097/LGT.0000000000000669
36. Borghi A, Flacco ME, Zedde P, Toni G, Schettini N, Corazza M. Does Clearance of Vulvar Lichen Sclerosus after a Corticosteroid Treatment Correspond to a Decrease in Disease-Related Burden? Results from a Cohort Study Using Pictorial Representation of Illness and Self-Measure and the Dermatology Life Quality Index. *Dermatology.* 2023;239(1):81-90. doi:10.1159/000526257
37. Wu M, Kherlopian A, Wijaya M, Fischer G. Quality of life impact and treatment response in vulval disease: Comparison of 3 common conditions using the Vulval Quality of Life Index. *Australas J Dermatol.* 2022;63(4). doi:10.1111/ajd.13898
38. O'Grady C, O'Connor C, Al Moosa A, Murphy M, Nic Dhonncha E. Burden of treatment in vulval lichen sclerosus. *Skin Health Dis.* 2022;2(3):e125. doi:10.1002/ski2.125

# Examination

*Amanda Selk, Alessandro Borghi, Nina Madnani, Olushola Akinshemoyin Vaughn*

**E**xamination is fundamental to diagnosis and management of lichen sclerosus (LS). Explanation, consent, positioning, and lighting are key components of vulvar examination. Some practitioners use a colposcope or dermatoscope for magnification. Key features of LS include abnormal skin color, altered texture, and vulvar anatomic change. Targeted extragenital skin examination aids in evaluation for other locations of LS and comorbid conditions. Sensitivity in language and written documentation supports patients and primary care providers to better understand LS and its treatment. Clinical photography aids in monitoring of progress, clinicopathologic correlation, and research endeavors.

## Approach to examination

Trauma-informed genital and pelvic examination begins with an assumption that all patients may have experienced sexual violence.<sup>1</sup> The process of creating a sense of safety during examination starts in the consultation room with gender-neutral language, open-ended questions, and active listening. While the patient is dressed, a member of the clinical team provides an overview of the steps and aims of vulvar examination. The consent discussion includes positioning, the mechanism of vulvar inspection, and the possibility of other procedures that may be indicated based on findings, such as speculum assessment, microbiology swabs or scrapings, or biopsy. The clinician may then identify limits of consent and individualized supports that may aid in exam completion. Patients who decline examination may be willing to schedule it in future with a support person and psychologic and/or pharmacologic preparation. Clinicians may offer self-collection of human papillomavirus (HPV), chlamydia, gonorrhea, and trichomonas if relevant, but explain it is not possible to diagnose genital skin conditions without examination.

In many healthcare settings, attendance of a chaperone provides reassurance to the patient simultaneous to assisting the provider with procedures. The patient need not make any special preparations for vulvar examination, although many request to empty their bladder beforehand. Some women remove pubic hair and/or use ‘hygiene’ wipes, both of which are unnecessary and should be discouraged. After removing clothing from the waist down in a private setting, the patient uses a sheet to cover between waist and knees and transition from the changing area to the examination table. There are several examination positions that allow for thorough inspection of the vulva, perineum, and perianal area. These include

supine lithotomy, supine frog-leg, prone knee-chest, and lateral knee-chest. Lithotomy is a common strategy for adults while the other positions are often useful in children. Lighting may be provided through a gooseneck or other overhead spot lamp, a headlamp, and/or a colposcope.

There are several ways during examination to facilitate women seeing their own vulva. With consent, a clinical image may be taken and reviewed with the patient. Alternatively, the patient uses a mirror to visualize the vulva. This usually requires back support, the legs bent at the knees and abducted at the hips, and the mirror between the legs facing the vulva. Long-handled mirrors are available through a variety of suppliers and are ergonomically superior to standard vanity mirrors. Use of a mirror is associated with an increased sense of control, knowledge, and a desire to use it again during future examinations.<sup>2</sup> Optional colposcope accessories include a camera connected to a screen positioned in view of the patient. This allows for real-time demonstration of affected areas and patient-provider engagement throughout the examination process. More detailed review of findings and their implications occurs after the patient has dressed, permitting time for questions<sup>3</sup>

Vulvar examinations at each clinical visit are essential to monitor disease status and guide therapy. A systematic approach includes the mons pubis and anterior commissure, clitoral hood, glans clitoris, labia majora and minora, vestibule, perineum, perianal area, and natal cleft.<sup>3</sup> All areas are inspected for loss of architecture, white color change, hyper- or hypopigmentation, purpura, ecchymosis, abnormal texture, excoriations, erosions, and scars. The term 'figure of 8 distribution' is used to describe simultaneous vulvar and perianal white color change. This is common but not universal as many LS patients have localized disease or non-contiguous involvement of several sites. The rate of perianal LS involvement is unknown. In one series, 42% of perianal biopsies done for vulvar skin abnormalities showed LS.<sup>4</sup>

The subpannus, inguinal, and genitocrural folds should also be inspected for skin changes. While LS may occur here, these moist sites are often the site of cutaneous candidiasis or dermatophytosis. Other common intertriginous conditions include psoriasis inversus, erythrasma, seborrheic dermatitis, irritant contact dermatitis, and hidradenitis suppurativa.

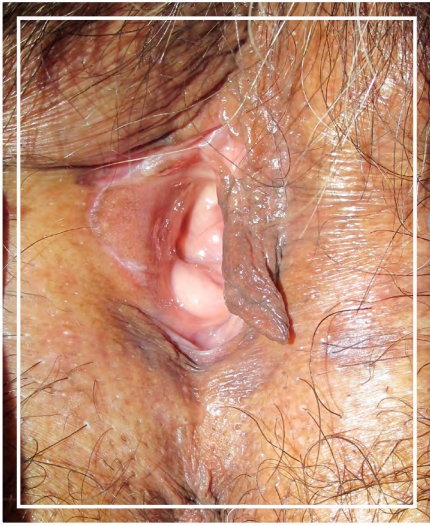Lichen sclerosus may rarely occur in the vagina and tends to be contiguous with vulvar disease.<sup>5</sup> Two reports describe vaginal LS occurring where keratinization occurred due to pelvic organ prolapse.<sup>6,7</sup> There is also a case report of an asymptomatic white plaque identified as LS at the vaginal vault after hysterectomy.<sup>8</sup>

Extragenital LS occurs in up to 15-20% of LS patients, most commonly reported on the neck and shoulders but also trunk, arms, palms, soles, breasts, and face including the eyelid.<sup>9,10</sup> It appears to occur across all age groups, more often in women than men.<sup>11</sup> Ivory-white macules often coalesce to form larger patches sometimes with a thinned texture, purpura, and/or ecchymosis.<sup>11</sup> Oral involvement is unusual but has been reported. A case series of 34 patients described asymmetric porcelain white papules or plaques usually involving the gingiva, orolabial mucosa, or lips.<sup>12</sup> Urethral and nail bed involvement also occurs rarely.<sup>13,14</sup>

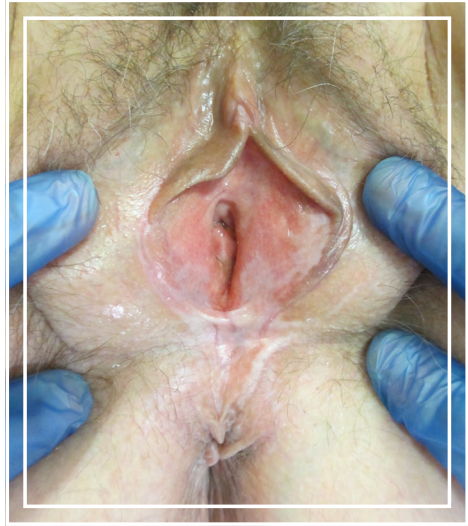## Vulvar findings

### Changes in color and texture

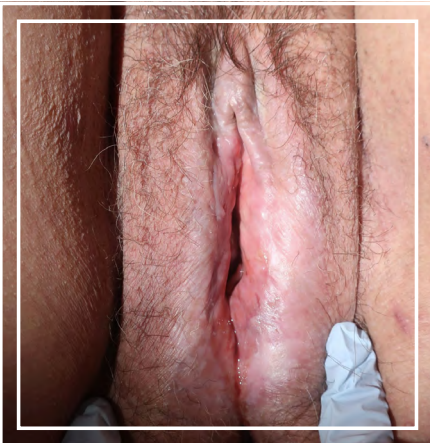White color change is the most common clinical feature of LS. The reported frequency varies across publications from over half to almost universal.<sup>15,16</sup> The color is often described as ivory or porcelain and pale areas are usually well-demarcated and may coalesce or enlarge over time.<sup>17,18</sup> White areas may be discrete or confluent, unifocal or multifocal, subtle or obvious, localized or extensive (Fig 1-4). Color change may in part arise from reduced epidermal melanocytes and melanin, demonstrated through histological and immunohistochemical assessment.<sup>19,20</sup>



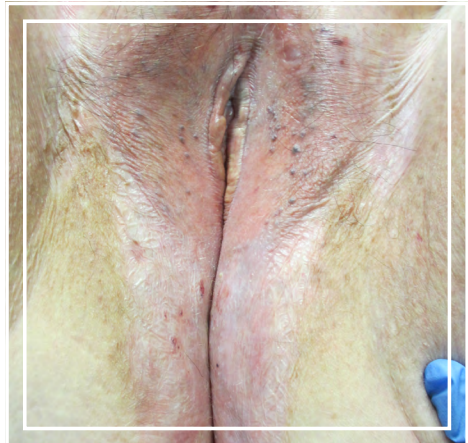**FIGURE 1.** Focal white color change at site of adherence between right labium minus and interlabial sulcus.



**FIGURE 2.** Focal white color change at inferior inner labia minora, posterior fourchette, and perineum.

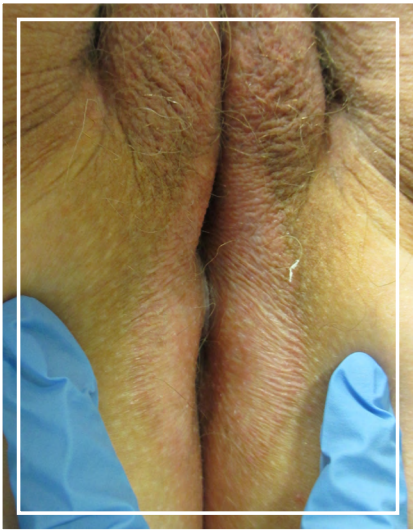

**FIGURE 3.** Diffuse white color change over hairless and hair bearing skin from anterior commissure to perineum.

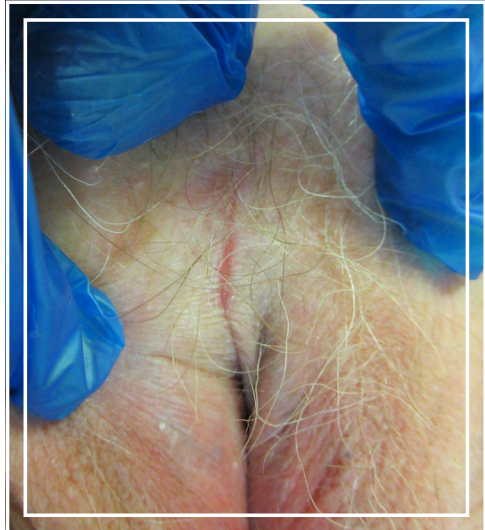

**FIGURE 4.** Diffuse white color change over vulva, buttock, and genitocrural folds.

White color change due to LS may be difficult to distinguish from genital skin depigmentation seen in vitiligo or scar.<sup>21</sup> Findings more indicative of LS include pale patches that appear thinned, atrophic, fragile, or crinkly (Fig 5). White plaques also signal LS rather than other conditions and may show increased skin markings or a rough surface (Fig 6). Texture changes arise from disease-related epidermal alterations (see Chapter 4). These skin abnormalities result in propensity towards fissuring and erosions with minor trauma. Dermal microvascular damage may lead to purpuric and ecchymotic patches visible clinically and/or dermoscopically.<sup>22</sup> Chronic inflammation with related tissue and microvascular injury underlies the adhesive and fibrotic phenomena of progressive vulvar architectural change.

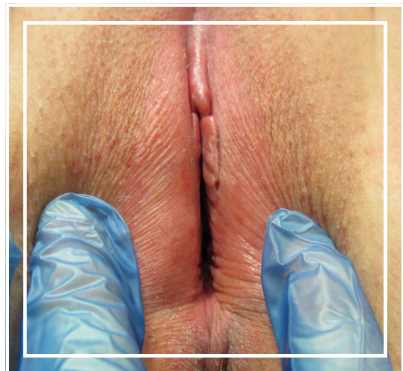

**FIGURE 5.** White-pink color change and crinkly texture over inferior labia majora, perineum, and perianus.



**FIGURE 6.** White color change and thickened texture over periclitoral structures with a vertical fissure at anterior commissure.

Erythema may accompany findings of pallor and texture change. Some authors hypothesize this represents emerging areas of LS.<sup>23</sup> Inflammation with corresponding papillary dermal microvascular dilation may produce erythema but redness may also arise from rubbing or scratching, reaction to topical therapies, contact dermatitis, or mycotic superinfection (Fig 7).<sup>23</sup> If erythema is prominent or extensive, clinicians may consider comorbid or alternative diagnoses such as lichen planus, plasma cell vulvitis, psoriasis, or cancer. Microbiology testing and biopsies can assist in delineating the diagnosis (see Chapter 5).

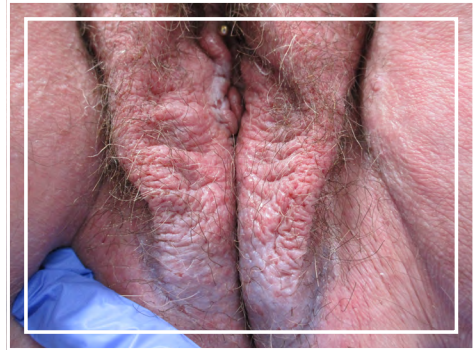

**FIGURE 7.** Moderately well-demarcated circumferential erythema with edema of periclitoral structures in the setting of candida superinfection of lichen sclerosis (LS).



## Evidence of rubbing or scratching

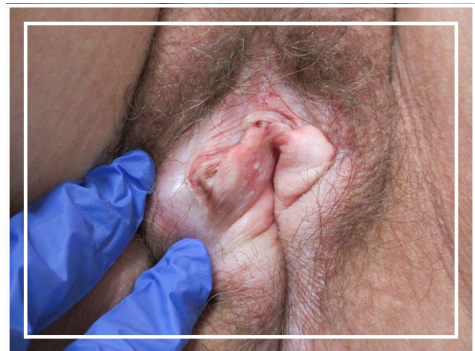The itch-scratch cycle is common in many skin conditions and results in accentuation of natural skin lines and thickening of the epidermis (Fig 8).<sup>24</sup> The clinicopathologic term for this phenomenon is lichen simplex chronicus (LSC), which does not signal the underlying etiology of pruritus. Lichenification is both a clinical and histopathologic term for skin manifestations of chronic rubbing and scratching, seen on biopsy as hyperkeratosis, hypergranulosis, acanthosis, and papillary dermal fibrosis (see Chapter 4). 'Lichenification' is often used by clinicians interchangeably with 'hyperkeratosis' to denote thickened skin texture. However, a more accurate clinical description of hyperkeratosis is a raised 'stuck-on' white to yellow plaque that feels firm to touch and is unable to be removed with gentle cleansing. This finding may correlate on biopsy with the pathologic definition of hyperkeratosis - increased thickness of the layers of non-nucleated corneocytes that comprise the stratum corneum - or it may reflect thick parakeratosis and/or scale crust (see Chapter 4). A clinicopathologic study of perianal biopsies found one-third of specimens with LS had superimposed LSC.<sup>4</sup>



**FIGURE 8.** Thickened skin with increased skin markings and grey-pink discoloration over inferior labia majora, consistent with lichen simplex chronicus (LSC) comorbid with LS.

Thickened skin texture was identified as an important marker of disease severity in a Delphi consensus exercise, but experts have not agreed on what constitutes lichenification and how that correlates with disease severity when evaluating photographs of LS.<sup>25,26</sup> This lack of agreement may be due to confusion around terminology and the relative contributions of color and texture when assessing an image rather than palpating the skin.

Excoriation is exogenous injury to all or part of the epidermis and is a secondary feature in pruritic dermatoses including LS (Fig 9). Excoriations, compared to erosions, are always from an external force like picking or scratching with nails.<sup>24</sup> Biopsy of excoriated skin often shows a linear erosion on a background of LS with superimposed LSC. The differential diagnosis for treatment-resistant plaques, erosions, or ulcers also includes candidiasis, herpes simplex virus, and both HPV-associated and HPV-independent neoplasia.



**FIGURE 9.** Areas of lichenification, evidence of excoriation, and hyperkeratosis adjacent to an erosion on inner right labium minus on a background of white color change in untreated LS.

## Architectural changes

Anatomic changes resulting from LS include scarring between the clitoral hood and glans clitoris, flattening or phimosis of the clitoral hood to cover the glans, resorption of the labia minora, and introital narrowing due to fibrotic changes of the clitoral frenulum and posterior fourchette. Changes at the vestibule may produce dyspareunia, recurrent fissuring, and alteration to the urinary stream.<sup>27</sup> The end result in some patients is a smooth contour from labia majora to vagina lacking in other discernible structures (Fig 10).

Clitoral phimosis may be asymptomatic or symptomatic. Smegma, made up of sebum and desquamated epithelial cells, may get trapped between the glans and hood, leading to clitoral pseudocyst formation (Fig 11).<sup>28</sup> Infection may result and require antibiotic therapy, surgical drainage, and/or clitoral adhesiolysis (see Chapter 12). Keratin pearls, made up of firm millimeter-sized dense keratin, may also become trapped and lead to clitoral pain.<sup>29</sup>

The relationship between disease severity, as measured by examination findings and architectural changes, and quality of life (QoL) remains unclear and merits further study (see Chapter 8).<sup>30,31</sup> Qualitative research suggests patients may experience a range of negative emotions relating to anatomic change. There may be anger at delayed diagnosis contributing to progression, a feeling of horror at the altered appearance, or a sense of lost femininity and identity.<sup>32</sup> Architectural alteration and the desire to avoid a 'point of no return' may motivate use of long-term treatment.<sup>33</sup> When discussing anatomic findings with patients, clinicians should avoid words with negative connotations like destruction, obliteration, or disfigurement. When there is clitoral phimosis, providers may provide education about clitoral anatomy with reassurance that the glans, crura, and erectile tissue remain functional and are unchanged by LS.

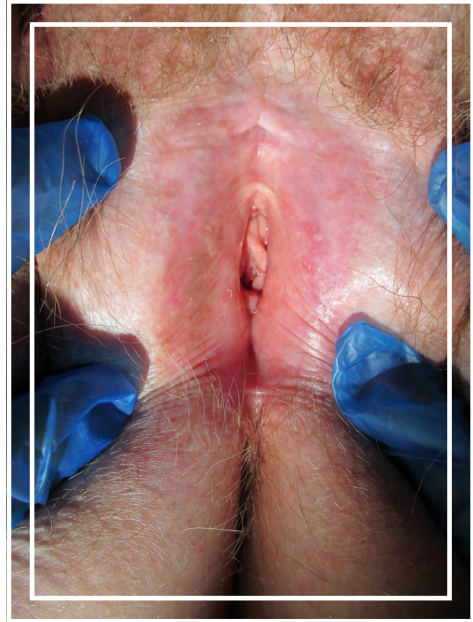

FIGURE 10. Anterior architectural change with partial clitoral phimosis and total resorption of labia minora.

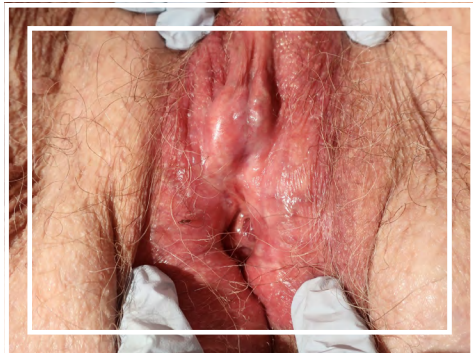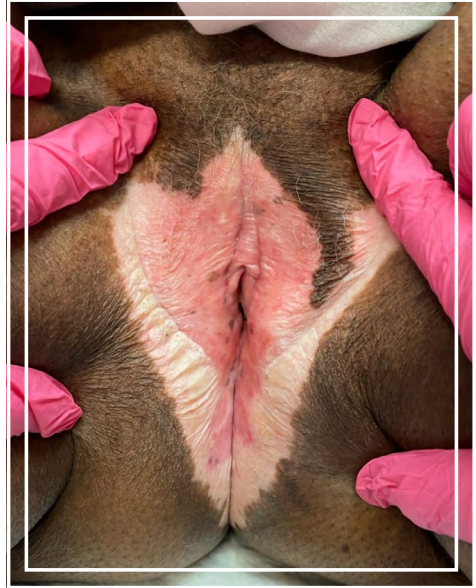


FIGURE 11. Clitoral phimosis with clitoral pseudocyst in the setting of candidal superinfection of LS.

## Appearance of lichen sclerosus in skin of color

The appearance of vulvar LS is highly variable and the role of race, ethnicity, and skin color is uncertain. Perceived differences may be related to the clinician's ability to discern classic findings in skin of color.<sup>34</sup> Darker skin tones are underrepresented in gynecology textbooks depicting vulvar conditions and dermatology journals.<sup>35,36</sup> Inadequate exposure to images of skin of color at all training levels may propagate disparities in recognition.

Color change is important for diagnosis, severity assessment, and monitoring of LS, but this is likely universal and not related to the underlying skin tone. In a Delphi consensus, several color-related items did not reach consensus for inclusion in an adult vulvar LS severity scale, including ecchymosis, pallor, hypopigmentation, hyperpigmentation, and erythema.<sup>25</sup> While 'whitening' and telangiectasia did reach consensus, neither is influenced by skin tone and it is unclear how 'whitening' is different from pallor or hypopigmentation. The term depigmentation typically refers to the appearance of vitiligo and is the result of extensive autoimmune destruction of melanocytes. Genital vitiligo and LS may be comorbid and distinguishing between the two is particularly challenging in skin of color, as both conditions contrast dramatically with adjacent normal skin (Fig 12).<sup>37</sup> Anecdotally, vitiligo often spares the clitoral hood while LS frequently involves periclitoral structures.<sup>38</sup>



**FIGURE 12.** Well-demarcated depigmented skin at outer labia majora and buttock consistent with vitiligo abutting an internal demarcation of pallor and erythema over labia majora, labia minora, perineum, and perianus consistent with LS; there are areas of near-normal pigmentation within the erythematous area.

In darker skin, erythema may appear more violaceous, hyperpigmented, or subtle.<sup>39</sup> Lichen simplex chronicus appears ashen to purple in darker skin tones, rather than pale pink-gray in lighter-skinned people. Itch and skin manifestations of rubbing and scratching may be more severe due to race-related variations in skin physiology.<sup>40</sup> Black patients are more likely to experience pruritus, possibly due to increased transepidermal water loss and other structural variations.<sup>41</sup> Asian patients with atopic dermatitis are more likely to demonstrate thickened skin texture, possibly due to variable regulation of inflammatory cytokines.<sup>39</sup>

Cultural sensitivity and careful use of language is important when discussing examination with women of color. Comfort with the process of examination varies across cultures and skin pigment may be strongly associated with identity. Further research into the intersection of vulvar disease with race, ethnicity, cultural practices, sexual behaviors, and vulvovaginal microbiome may help guide diagnosis and treatment.



## Role of colposcopy, dermoscopy, and photography

Magnification can be useful in assessment of smaller structures or lesions. Gynecologists commonly use a colposcope while some dermatologists use a dermatoscope for vulvar examination. Neither are necessary for examination of LS. Use of the colposcope facilitates whole lower genital tract assessment. Acetic acid 3-5% is applied only when assessing for HPV-associated neoplasia of cervix, vagina, vulva, and anus.<sup>42</sup> Acetic acid is not useful for diagnosis of other dermatologic conditions and does not provide additional information beyond that available with lighting and magnification.<sup>43</sup> Application of acetic acid is uncomfortable for patients, especially over broken skin. Gynecologists unfamiliar with vulvovaginal conditions may apply acetic acid universally, without realizing acetowhite change occurs at the normal mucocutaneous junction and with dermatitis or mycosis.<sup>44,45</sup> This may provoke an unnecessary or misplaced biopsy. Acetic acid is not recommended for routine examination of a patient with LS.

Lichen sclerosus exhibits a characteristic dermoscopic pattern of a pale background and patchy structureless areas that vary in color from white to white-yellow to milky-pink (Fig 13-15).<sup>22,46</sup> Short white, shiny lines are sometimes observed.<sup>22</sup> There is a marked decrease in vessel concentration, called vascular desertification, when compared with surrounding unaffected surfaces. Sparse vessels are polymorphic or dotted, without specific arrangement.<sup>22,47</sup> Gray dots arranged in a peppering pattern may be observed in genital LS and other genital inflammatory diseases.<sup>48</sup> Red to purpuric, structureless, well-circumscribed dots, globules, or blotches, corresponding to blood spots, are common in LS. Yellow comedo-like openings are sometimes observed in vulvar LS, but nearly universal at extragenital sites.<sup>49,50</sup>

A baseline photograph of the entire anogenital area at the initial consultation provides documentation of initial disease severity and a reference for future examinations. Photo documentation provides a more accurate record than a diagram. Pictures must be securely stored for archiving and easy retrieval during each patient follow-up. Some electronic health records

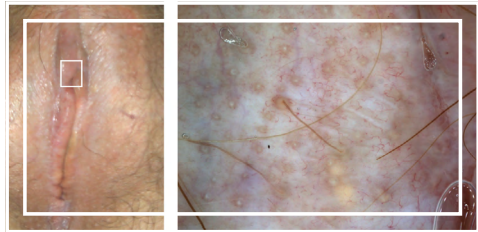


FIGURE 13. Dermoscopic findings of LS: homogeneous whitish background with white-yellowish comedo-like openings corresponding to dilated infundibula with follicular cornified plugging.

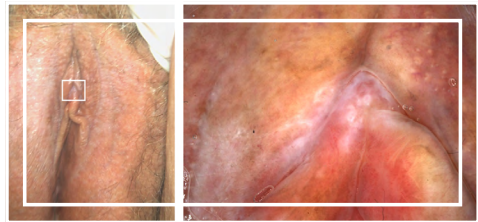


FIGURE 14. Dermoscopic findings of LS: typical whitish patchy structureless areas and scattered white-yellowish comedo-like openings.

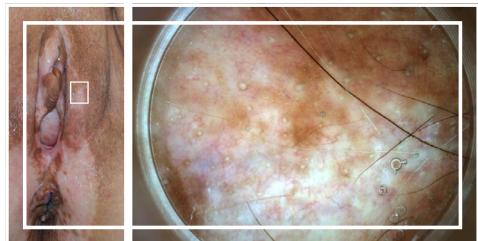


FIGURE 15. Dermoscopic findings of LS: white scales at the clitoris hood with adjacent whitish patches.

can embed photographs directly into patient files. Despite poor inter-provider agreement in assessment of disease severity via photograph, interval images allow individual clinicians-patient dyads to identify changes over time, aiding in titration of the treatment regimen.<sup>26</sup>

## Assessment of severity and outcomes of treatment

To date there are no consensus-based measurement tools for LS, in part due to marked intra- and inter-provider variation in assessment of clinical features.<sup>25,51</sup> International experts could not agree on the severity of color and texture changes, architectural alterations, or global impression using vulvar photographs.<sup>26</sup> There have been several scales showing good agreement between raters at single centers that have not yet been tested for reliability outside of these publications. The “Clinical Lichen Sclerosus Scale - CLISSCO” assesses 3 symptoms, 3 signs, and 6 architectural changes rated on a scale of 0-3 (absent, mild, moderate, severe).<sup>52</sup> The signs in CLISSCO are whitening, petechiae/ecchymosis, and fissures. The Vulvar Architecture Severity Scale (VASS) was developed using published photos from an education website.<sup>53</sup> This tool divides the vulva into 6 regions, scores architectural changes as none, mild, moderate, and severe, and records the presence of atrophy, pallor, ecchymosis, hyperkeratosis, scarring, and/or fissure. A third proposed architectural grading system, the CIV classification, identifies clitoral phimosis, interlabial sulci involvement, and introital narrowing.<sup>54</sup> The CIV authors found improved agreement between raters when assessing patients in person rather than from photographs.

While assessment of the severity of LS is essential for high-quality clinical research, the ideal tools to achieve this have not yet been identified or validated (see Chapter 16). Visible clinical signs of LS are one of three core domains agreed upon by the international working group Core Outcomes for Research in Lichen Sclerosus (CORALS), alongside symptoms and LS-specific quality of life.<sup>55</sup> Work is ongoing on the subdomains and measurement tools for these areas.

## Vulvar self-examination

Some organizations and authors recommend vulvar self-examination to monitor disease progression and to detect cancer at earlier stages.<sup>56</sup> Among Italian women attending a lower genital disease clinic, 76% had not heard of self-examination, 61% described shame and embarrassment about their genitals, and only 23% would obtain medical opinion after identifying a possible abnormality.<sup>56</sup> The British Society of Vulvovaginal Disease has a patient-oriented booklet that describes self-examination and when to seek help.<sup>57</sup> Recruitment has concluded in a pilot clinical trial of face-to-face training in self-examination for women at increased risk of vulvar cancer, accompanied by written information, and reminders.<sup>58</sup> While effectiveness of self-examination to detect disease exacerbation or neoplasia has not been demonstrated, the potential benefit likely outweighs risks of anxiety or over-intervention.

## Limitations of the literature

Expert opinion rather than clinical research underlies most recommendations on examination practices. Information is lacking about variation in LS features across racial and ethnic groups. Translating examination findings of white color change, texture abnormality, and ar-

chitectural alteration to a disease severity score is difficult and a work in progress. There are multiple descriptors in the literature of white color change to include 'pallor,' 'whitening,' and 'hypopigmentation,' each with subtly different meanings but likely used interchangeably by clinicians. Words used to convey thickened texture, like 'hyperkeratosis' and 'lichenification,' have different clinical and histopathologic definitions and the relationship between these descriptors and LS appearance lacks reproducibility. Consistent and accurate nomenclature to describe clinical findings of LS would likely enhance inter-provider communication, improve research quality, and facilitate consensus and validation of severity scoring systems.

## Conclusions and recommendations

Vulvar examination is a multifaceted skill that requires sensitive communication, competent use of equipment, knowledge of common and unusual features of LS, and a consistent strategy for description and documentation. Patient involvement in vulvar skin assessment is empowering and likely improves medication adherence and proper use of topical treatment.

- Consent, appropriate positioning, good lighting, and a systematic approach are fundamental to quality genital examination.
- Initial examination includes genital and extragenital sites to achieve LS diagnosis and document its distribution and appearance.
- Vulvar examination is required at each subsequent visit to assess for color and texture abnormalities, changes in vulvar architecture, and evidence of superimposed, comorbid, or neoplastic skin conditions, ideally documented with serial photographs.
- Vulvar self-examination may be helpful in disease monitoring and for early detection of neoplasia.

## References

1. Gorfinkel I, Perlow E, Macdonald S. The trauma-informed genital and gynecologic examination. *Can Med Assoc J*. 2021;193(28):E1090-E1090. doi:10.1503/cmaj.210331
2. Tam T, Crisp CC, Hill AM, et al. Utilization of a Mirror During Pelvic Examinations: Does it Improve the Patient's Experience? *Female Pelvic Med Reconstr Surg*. 2021;27(3):208-213. doi:10.1097/SPV.0000000000000975
3. Cohen Sacher B. The Normal Vulva, Vulvar Examination, and Evaluation Tools. *Clin Obstet Gynecol*. 2015;58(3):442-452. doi:10.1097/GRF.0000000000000123
4. Day T, Bohl TG, Scurry J. Perianal lichen dermatoses: A review of 60 cases. *Australas J Dermatol*. 2016;57(3):210-215. doi:10.1111/ajd.12308
5. Day T, Burston K, Dennerstein G, Pagano R, Scurry J. Vestibulovaginal Sclerosis Versus Lichen Sclerosis. *Int J Gynecol Pathol*. 2018;37(4):356-363. doi:10.1097/PGP.0000000000000441
6. Zendell K, Edwards L. Lichen sclerosis with vaginal involvement: report of 2 cases and review of the literature. *JAMA Dermatol*. 2013;149(10):1199-1202. doi:10.1001/jamadermatol.2013.4885
7. Xavier J, Vieira-Baptista P, Moreira A, Portugal R, Beires J, Tanos V. Vaginal lichen sclerosis: report of two cases. *Facts Views Vis ObGyn*. 2017;9(3):171-173.
8. Longinotti M, Schieffer YM, Kaufman RH. Lichen sclerosis involving the vagina. *Obstet Gynecol*. 2005;106(5 Pt 2):1217-1219. doi:10.1097/01.AOG.0000161058.02449.e8
9. Hargis A, Ngo M, Kraus CN, Mauskar M. Systemic Therapy for Lichen Sclerosis: A Systematic Review. *J Low Genit Tract Dis*. 2024;28(1):84-90. doi:10.1097/LGT.0000000000000775
10. Radke PM, Maltry AC, Mokhtarzadeh A, Harrison AR. A Unique Ocular Presentation of Extragenital Lichen Sclerosis. *Ophthal Plast Reconstr Surg*. 2017;33(3S Suppl 1):S56-S58. doi:10.1097/IOP.0000000000000662
11. Arif T, Fatima R, Sami M. Extragenital lichen sclerosis: A comprehensive review. *Australas J Dermatol*. 2022;63(4):452-462. doi:10.1111/ajd.13890

12. Tomo S, Santos IS, de Queiroz SA, Bernabé DG, Simonato LE, Miyahara GI. Uncommon oral manifestation of lichen sclerosus: critical analysis of cases reported from 1957 to 2016. *Med Oral Patol Oral Cirugia Bucal*. 2017;22(4):e410-e416. doi:10.4317/medoral.21606
13. Kumar D, Mittal A, Panwar VK, Agrawal O. Female Urethral Stricture Caused by Lichen Sclerosus: An Uncommon Presentation. *Cureus*. 2023;15(7):e42551. doi:10.7759/cureus.42551
14. Ramrakha-Jones VS, Paul M, McHenry P, Burden AD. Nail dystrophy due to lichen sclerosus? *Clin Exp Dermatol*. 2001;26(6):507-509. doi:10.1046/j.1365-2230.2001.00878.x
15. Virgili A, Borghi A, Toni G, Minghetti S, Corazza M. Prospective clinical and epidemiologic study of vulvar lichen sclerosus: of prevalence and severity of clinical features, together with historical and demographic associations. *Dermatol Basel Switz*. 2014;228(2):145-151. doi:10.1159/000356163
16. Borghi A, Corazza M, Minghetti S, Toni G, Virgili A. Clinical and dermoscopic changes of vulvar lichen sclerosus after topical corticosteroid treatment. *J Dermatol*. 2016;43(9):1078-1082. doi:10.1111/1346-8138.13374
17. Lee A, Fischer G. Diagnosis and Treatment of Vulvar Lichen Sclerosus: An Update for Dermatologists. *Am J Clin Dermatol*. 2018;19(5):695-706. doi:10.1007/s40257-018-0364-7
18. Fistarol SK, Itin PH. Diagnosis and treatment of lichen sclerosus: an update. *Am J Clin Dermatol*. 2013;14(1):27-47. doi:10.1007/s40257-012-0006-4
19. Fu Y, Bao Y, Li Z, Gao X, Chang J. Study of melanocyte density and epidermal thickness in vulvar lichen sclerosus lesions. *Int J Dermatol*. 2021;60(8):991-995. doi:10.1111/ijd.15555
20. Park YJ, Lee H, Park HS, Kim YC. Histopathological differences between vitiligo and lichen sclerosus et atrophicus using quantitative immunohistochemical analysis. *Front Med*. 2023;10:1205909. doi:10.3389/fmed.2023.1205909
21. Esse I, Rodriguez KH, Kassels A, Shiu J, Kraus CN. Vulvar lichen sclerosus and vitiligo: Overlap and clinical features. *J Am Acad Dermatol*. 2023;89(4):839-841. doi:10.1016/j.jaad.2023.06.016
22. Borghi A, Corazza M, Minghetti S, Bianchini E, Virgili A. Dermoscopic Features of Vulvar Lichen Sclerosus in the Setting of a Prospective Cohort of Patients: New Observations. *Dermatol Basel Switz*. 2016;232(1):71-77. doi:10.1159/000439198
23. Regauer S, Liegl B, Reich O. Early vulvar lichen sclerosus: a histopathological challenge. *Histopathology*. 2005;47(4):340-347. doi:10.1111/j.1365-2559.2005.02209.x
24. Bologna J, Schaffer J, Cerroni L, eds. *Dermatology*. 4th ed. Elsevier; 2018.
25. Sheinis M, Selk A. Development of the Adult Vulvar Lichen Sclerosus Severity Scale-A Delphi Consensus Exercise for Item Generation. *J Low Genit Tract Dis*. 2018;22(1):66-73. doi:10.1097/LGT.0000000000000361
26. Sheinis M, Green N, Vieira-Baptista P, et al. Adult Vulvar Lichen Sclerosus: Can Experts Agree on the Assessment of Disease Severity? *J Low Genit Tract Dis*. 2020;24(3):295-298. doi:10.1097/LGT.0000000000000534
27. Kennedy CM, Dewdney S, Galask RP. Vulvar granuloma fissuratum: a description of fissuring of the posterior fourchette and the repair. *Obstet Gynecol*. 2005;105(5 Pt 1):1018-1023. doi:10.1097/01.AOG.0000158863.70819.53
28. Romanello JP, Myers MC, Nico E, Rubin RS. Clitoral adhesions: a review of the literature. *Sex Med Rev*. 2023;11(3):196-201. doi:10.1093/sxmrev/qead004
29. Krapf J, Mautz T, Lorenzini S, Holloway J, Goldstein A. Clinical Presentation of Clitorodysplasia Associated with Clitoral Adhesions and Keratin Pearls. *J Sex Med*. 2022;19(Supplement\_3):S14-S14. doi:10.1016/j.jsxm.2022.05.032
30. Ranum A, Pearson DR. The impact of genital lichen sclerosus and lichen planus on quality of life: A review. *Int J Womens Dermatol*. 2022;8(3):e042. doi:10.1097/JW9.0000000000000042
31. Borghi A, Flacco ME, Zedde P, Toni G, Schettini N, Corazza M. Does Clearance of Vulvar Lichen Sclerosus after a Corticosteroid Treatment Correspond to a Decrease in Disease-Related Burden? Results from a Cohort Study Using Pictorial Representation of Illness and Self-Measure and the Dermatology Life Quality Index. *Dermatol Basel Switz*. 2023;239(1):81-90. doi:10.1159/000526257
32. Arnold S, Fernando S, Rees S. Living with vulval lichen sclerosus: a qualitative interview study. *Br J Dermatol*. 2022;187(6):909-918. doi:10.1111/bjd.21777
33. Rees S, Arnold S, Kherlopian A, Fischer G. Attitudes Toward Proactive Topical Corticosteroid Use Among Women With Vulval Lichen Sclerosus. *J Low Genit Tract Dis*. 2024;28(2):183-188. doi:10.1097/LGT.0000000000000791
34. Akinshemoyin Vaughn, OL. Delayed Diagnosis of Vulvar Dermatoses in Skin of Color: A Case Series. In: Vol 26 (3S). *Journal of Lower Genital Tract Disease*; 2022:S15-42.
35. Gwan A, Tanner-Sanders LN, Nair N, Chapple AG, Jernigan A. Equity in visual representation of vulvar conditions in major gynecology textbooks. *J Natl Med Assoc*. 2022;114(3):314-323. doi:10.1016/j.jnma.2022.02.005
36. Hereford B, Kim Y, Zaenglein AL, Hollins LC. Photographic representation of skin tones in three dermatology journals. *Pediatr Dermatol*. 2021;38(S2):146-148. doi:10.1111/pde.14766
37. Dennin MH, Stein SL, Rosenblatt AE. Vitiligo variant of lichen sclerosus in young girls with darker skin types. *Pediatr Dermatol*. 2018;35(2):198-201. doi:10.1111/pde.13399

38. Madhiani, Nina, Khan, K, Chaturvedi, N, eds. *Atlas of Vulvovaginal Disease in Darker Skin Types*. 1st ed. CRC Press; 2023.
39. McKenzie S, Brown-Korsah JB, Syder NC, Omar D, Taylor SC, Elbuluk N. Variations in genetics, biology, and phenotype of cutaneous disorders in skin of color. Part II: Differences in clinical presentation and disparities in cutaneous disorders in skin of color. *J Am Acad Dermatol*. 2022;87(6):1261-1270. doi:10.1016/j.jaad.2022.03.067
40. Ingrassi G, El-Kashlan N, Alexis A, Yosipovitch G. Chronic itch in African Americans: an unmet need. *Arch Dermatol Res*. 2022;314(5):405-415. doi:10.1007/s00403-021-02255-6
41. Sutaria N, Parthasarathy V, Roh YS, et al. Itch in skin of colour: a multicentre cross-sectional study. *Br J Dermatol*. 2021;185(3):652-654. doi:10.1111/bjd.20403
42. American College of Obstetricians and Gynecologists' Committee on Practice Bulletins—Gynecology. Diagnosis and Management of Vulvar Skin Disorders: ACOG Practice Bulletin, Number 224. *Obstet Gynecol*. 2020;136(1):e1-e14. doi:10.1097/AOG.0000000000003944
43. Micheletti L, Bogliatto F, Lynch PJ. Vulvoscopy: review of a diagnostic approach requiring clarification. *J Reprod Med*. 2008;53(3):179-182.
44. Santoso JT, Likes W. Colposcopic acetowhitening of vulvar lesion: a validity study. *Arch Gynecol Obstet*. 2015;292(2):387-390. doi:10.1007/s00404-015-3666-5
45. Heller DS, Day T, Allbritton JJ, et al. Diagnostic Criteria for Differentiated Vulvar Intraepithelial Neoplasia and Vulvar Aberrant Maturation. *J Low Genit Tract Dis*. 2021;25(1):57-70. doi:10.1097/LGT.0000000000000572
46. Larre Borges A, Todorovic-Zivkovic D, Lallas A, et al. Clinical, dermoscopic and histopathologic features of genital and extragenital lichen sclerosus. *J Eur Acad Dermatol Venereol JEADV*. 2013;27(11):1433-1439. doi:10.1111/j.1468-3083.2012.04595.x
47. Lacarrubba F, Borghi A, Verzi AE, Corazza M, Stinco G, Micali G. Dermoscopy of genital diseases: a review. *J Eur Acad Dermatol Venereol JEADV*. 2020;34(10):2198-2207. doi:10.1111/jdv.16723
48. Borghi A, Virgili A, Corazza M. Dermoscopy of Inflammatory Genital Diseases: Practical Insights. *Dermatol Clin*. 2018;36(4):451-461. doi:10.1016/j.det.2018.05.013
49. Horcajada-Reales C, Campos-Domínguez M, Conde-Montero E, Parra-Blanco V, Suárez-Fernández R. Comedo-like openings in dermoscopy: an essential diagnostic clue for lichen sclerosus, even in children. *J Am Acad Dermatol*. 2015;72(1 Suppl):S4-5. doi:10.1016/j.jaad.2014.03.006
50. Lacarrubba F, Pellacani G, Verzi AE, Pippione M, Micali G. Extragenital lichen sclerosus: clinical, dermoscopic, confocal microscopy and histologic correlations. *J Am Acad Dermatol*. 2015;72(1 Suppl):S50-52. doi:10.1016/j.jaad.2014.07.008
51. Green N, Sheinis M, Selk A. Vulvar Lichen Sclerosus: Outcomes Important to Patients in Assessing Disease Severity. *J Low Genit Tract Dis*. 2020;24(3):299-304. doi:10.1097/LGT.0000000000000547
52. Erni B, Navarini AA, Huang D, Schoetzu A, Kind A, Mueller SM. Proposition of a severity scale for lichen sclerosus: The "Clinical Lichen Sclerosus Score." *Dermatol Ther*. 2021;34(2):e14773. doi:10.1111/dth.14773
53. Almadori A, Zenner N, Boyle D, et al. Development and Validation of a Clinical Grading Scale to Assess the Vulvar Region: The Vulvar Architecture Severity Scale. *Aesthet Surg J*. 2020;40(12):1319-1326. doi:10.1093/asj/sjz342
54. Boero V, Liverani CA, Brambilla M, et al. The "CIV Classification," a New Proposal for the Architectural Grading of Vulvar Lichen Sclerosus. *J Low Genit Tract Dis*. 2021;25(4):291-295. doi:10.1097/LGT.0000000000000627
55. Simpson RC, Kirtschig G, Selk A, et al. Core outcome domains for lichen sclerosus: a CORALS initiative consensus statement. *Br J Dermatol*. 2023;188(5):628-635. doi:10.1093/bjd/ljac145
56. Preti M, Selk A, Stockdale C, et al. Knowledge of Vulvar Anatomy and Self-examination in a Sample of Italian Women. *J Low Genit Tract Dis*. 2021;25(2):166-171. doi:10.1097/LGT.0000000000000585
57. Vulval Self-Examination for Women at Increased Risk of Vulval Cancer. Published online 2021. Accessed January 21, 2024. <https://bssvd.org/wp-content/uploads/2021/05/VSE-Brochure-.pdf>
58. Sivalingam, Vanitha. Early Detection of Vulval Cancer Through Self-Examination (EDuCATE): Intervention Study. Published online July 7, 2021. Accessed June 11, 2024. <https://www.clinicaltrials.gov/study/NCT04952961>

# Histopathology

*Tania Day, James Scurry*

**H**istopathologic diagnosis of lichen sclerosus (LS) serves to support the clinical impression, document the condition in anticipation of skin normalization with treatment, and exclude comorbid conditions, superinfection, or neoplasia. Diagnostic criteria for LS are basal layer damage, a band-like lymphocytic infiltrate, and dermal sclerosis; these features are present in most specimens from LS-affected skin. Biopsies may be supportive but not diagnostic when sclerosis is absent. Normal or nonspecific biopsy does not overturn an experienced clinician's diagnosis of LS, but may represent suboptimal timing, incorrect site, a superimposed condition masking the underlying dermatosis, or be unexplained.

## Clinician's approach to vulvar biopsy

### Indication for biopsy

Consensus indications for biopsy of suspected LS in adults include unsure diagnosis, non-response to appropriately applied treatment, and concern for neoplasia.<sup>1,2</sup> Lack of clarity around diagnosis may emerge from unusual clinical features like erosion or erythema suggesting lichen planus (LP) or superinfection.<sup>3</sup> In patients with vitiligo, it may be difficult to distinguish depigmentation from the white color change of LS, especially when symptoms are minimal and skin texture is normal.<sup>4</sup> Features of lichen simplex chronicus (LSC) - increased skin markings, grey-pink color, and excoriations - may preclude assessment of underlying skin color and texture. Biopsy is part of an evaluative process for non-response to topical corticosteroids in suspected LS and serves to support or refute the original diagnosis, identify comorbid or superimposed conditions, and assess for HPV-associated or HPV-independent (HPV-I) precursor lesions (see Chapter 9).<sup>5</sup> Neoplasia in LS appears as lesions different to surrounding abnormal skin, with alterations in color, induration, surface features, and propensity to bleeding (see Chapter 11).<sup>6</sup> HPV-associated neoplasia may show vascular changes like mosaicism or punctuation and become more evident with exposure to acetic acid.<sup>7</sup> HPV-I vulvar intraepithelial neoplasia (VIN) usually appears as white to pink plaques or red patches and visualization is not aided by acetic acid.<sup>6</sup>

Some experts suggest routine biopsy of LS-affected skin at initial specialist presentation to document the diagnosis prior to instituting a suppressive regimen of lifelong topical steroids.<sup>2</sup> When treatment results in normalization of skin color and texture, future care providers may doubt the initial diagnosis and recommend cessation of treatment. Histopathology

of normal-appearing skin is often unremarkable, perhaps reinforcing an erroneous assumption that LS is not present. Clinical photography is a non-invasive alternative to biopsy for documenting a LS diagnosis but may not be as portable between care settings as a histopathology report.

## Timing of biopsy

Biopsy timing depends on both the indication and clinical environment. Suspicion of neoplasia triggers immediate tissue sampling. If the diagnosis is unclear, treatment of superinfection or dermatitis prior to biopsy may facilitate pathologic interpretation of the specimen. If sampling is planned to document LS after referral from primary care, steroid cessation for at least two weeks may unveil microscopic features of inflammation and basal layer damage. Many clinical settings do not have capacity for pre-appointment counselling around steroid cessation or provision of short-interval return appointments for biopsy. In this situation, careful examination often demonstrates an undertreated area, often at perineum or perianus, that may yield characteristic histopathologic findings.

## Selection of biopsy location and number

When there is concern for neoplasia, undertake biopsy at all morphologically distinct sites and the worst-appearing area within each unique lesion.<sup>6</sup> If there are multiple lesions or abnormalities involving the glans clitoris, sampling may sometimes require sedation or general anesthetic. When undertaking a biopsy to establish a diagnosis, sample an area with the most prominent LS characteristics.<sup>5</sup> When superinfection or additional dermatosis complicates LS, biopsy from both a classic-appearing area and a zone of unusual features improves detection of multiple diagnoses.<sup>8</sup>

When abnormal areas are homogenous and multiple sites are clinically suitable, provider convenience and patient comfort dictate placement. Lateral structures are preferable to medial sites, ideally avoiding periclitoral and perianal areas. Biopsy of labium minus risks a through-and-through buttonhole injury, especially with thinly protuberant labial anatomy and a Keyes punch technique.

## Biopsy technique

### Complications and risk mitigation

Complications of biopsy are uncommon and include bleeding, infection, pain, anatomic distortion, and cosmetic concerns. Therapeutic anticoagulation is not a contraindication to office biopsy, but suturing, cautery, and/or prolonged pressure may be necessary for hemostasis.<sup>9</sup> Rates of wound infection after skin biopsy are unknown but likely low in the outpatient setting. Infectious complications occurred in 27% of excisional and incisional biopsies done in a dermatology inpatient cohort with multiple comorbid health conditions.<sup>10</sup> Prophylactic or post-procedure topical or systemic antibiotics may be prescribed in unusual situations of lymphedema and/or recurrent cellulitis.<sup>11</sup> Patients with underlying pain syndromes may experience prolonged pain exacerbation after any vulvovaginal procedure. Anatomic damage



arises primarily from deep sampling of labia minora. Use of silver nitrate or ferrous subsulfate for hemostasis may produce permanent abnormal coloration at the biopsy site, especially in estrogen-deficient skin. Rarely, vasovagal and allergic events occur.

## Anesthetic

Pre-treatment with topical anesthetics is feasible in some clinical settings and reduces pain scores at biopsy.<sup>12</sup> Topical lidocaine and/or prilocaine 2-5% for at least 10 minutes facilitates subsequent anesthetic injection at hairless skin of periclititoris, labia minora, or anal verge. For superficial sampling of non-keratinized epithelium of vestibule or distal vagina, 10 minutes of topical anesthetic alone may be sufficient. At hair bearing skin, up to one hour of topicals may be required for effective reduction in injectional pain. Some providers arrange for home application with placement of an occlusive dressing for up to 2 hours. Local anesthetic is wiped away when the biopsy procedure begins. Topical anesthetics produce stinging discomfort, erythema, and/or edema in some patients. Lidocaine and prilocaine may be associated with histologic findings of epidermal and dermal pallor, spongiosis, keratinocyte vacuolar change, mild acantholysis, capillary congestion, and extravasated erythrocytes.<sup>13-15</sup> Dermal pallor has a similar appearance to the edematous hyaline change sometimes seen in LS. While these alterations do not usually impede the pathologist's ability to make a diagnosis, they may complicate assessment of acantholytic or subtle lichenoid disorders. A comment on the pathology request form about use of topical anesthetics alerts the pathologist to features that may represent artefact rather than a true skin abnormality.

Vulvar biopsy is a clean, non-sterile procedure. Pre-procedure preparation with chlorhexidine or iodine is optional. Lidocaine 1% is a commonly available rapid-acting local anesthetic and may be buffered with 0.1mL of sodium bicarbonate per 1mL lidocaine. Quantity depends on biopsy location and technical aspects, with more volume required at periclititoral locations, in known rapid metabolizers, and where a wheal enables easier tissue sampling. Supplementation with vasoconstrictors is accompanied by hypothetical concerns about tissue hypoxia at acral sites and cardiovascular risks in predisposed patients, but there is scant documentation of such events. Provider preference and local availability dictates use of vasoconstrictor-anesthetic combinations.<sup>16</sup>

## Procedure considerations

Procedure and device selection depends on the lesion location and appearance, differential diagnosis, instrument availability, and provider preference, detailed in Table 1. Procedure approach does not usually affect diagnostic performance.<sup>17</sup> There are multiple mechanisms for tissue hemostasis, each having proponents and detractors. Chemical cautery agents include 20-70% aluminum chloride, 20% ferric subsulfate (Moncel's solution), and 10-50% silver nitrate.<sup>18</sup> Agent availability differs across countries, regions, and facilities. These topicals coagulate surface proteins, causing local tissue necrosis and eschar formation. Silver nitrate application is more painful than the other two options while aluminum chloride is less likely to cause skin staining.<sup>19</sup> Ferric chloride aggregates blood cells and proteins to close small capillaries.<sup>20</sup> Avoid contact of chemical cautery agents with the specimen as contamination



causes tissue artefact potentially rendering slides uninterpretable. Other hemostasis options include diathermy, topical absorbable porcine skin gelatin (Gelfoam®), or suture reapproximation. Suture closure may be achieved in an interrupted or continuous, subcuticular or full thickness fashion. Choice of suture material is based on availability, cost, logistical considerations, biopsy location, and provider preference. There is no evidence to favor monofilament non-absorbable or delayed absorbable over braided undyed absorbable sutures. Patients with non-absorbable sutures must return to a clinical venue within 2 weeks for removal.

**TABLE 1 Comparative features of vulvar biopsy mechanisms**

	Punch	Biopsy forceps	Snip / shave	Suture-assisted	Elliptical excision
Type of lesion	Dermatosis or suspected neoplasia	Raised lesion or location at leading edge of structure	Non-neoplastic nodule/papule or pedunculated lesion	Papule or blister	Suspected intraepithelial neoplasia amenable to complete removal in office
Lesion site	Most vulvar skin	Vagina Labium minus edge Anus	Most vulvar skin	Most vulvar skin	Any lower genital site
Width	2-6mm 3-4mm preferred	<3mm	Variable	Variable	Variable
Depth	Controlled by clinician; <1cm	<5mm	Thinner than suture-assisted	Variable	Variable
Instruments	Keyes cylindrical blade 3-4mm Forceps Scissors	Tischler biopsy forceps	#15 scalpel or curved iris scissors Forceps	4.0-5.0 suture #15 scalpel or curved iris scissors	#15 scalpel Forceps Needle driver
Hemostasis	Chemical cautery Suture	Chemical cautery	Chemical cautery Suture	Chemical cautery Suture	Suture
Caution	Labial perforation	Inadequate sample	Non-sampling of dermis	Depth is operator dependent	Surgical skill required

Optimal punch biopsy depth is 3mm in hairless skin and 5mm in hair bearing skin.<sup>6</sup> The full depth of a cylindrical punch may be used for suspected cancer. Larger specimens should be oriented with either a suture correlated to anatomic location or pinned to cork and labelled with surrounding structures. Place specimen(s) in 10% buffered formalin. Label specimen jars with patient information and biopsy location. In the office setting, ensure the patient checks the label and request form to verify their identity.

The pathology request form is an essential mechanism of interprofessional communication.

Describe the location of the biopsy using anatomic terms and laterality, rather than an isolated clock-face position.<sup>6</sup> An example is 'left inferior interlabial fold.' Record the differential diagnosis and comorbid vulvar conditions; a lesion description should be brief but specific. An example is "new red patch on background LS, ddx LP vs VIN." Note previous HSIL, HPV-I VIN, or squamous cell cancer (SCC). An accompanying schematic or clinical photograph may enhance diagnostic accuracy in difficult cases through improved clinicopathologic correlation.

## Patient information

Inform patients that biopsy does not always provide a diagnosis - part of its utility is what it excludes.<sup>21</sup> Advise normal bathing, patting the biopsy site dry, and applying pressure if there is bleeding. Biopsy sites do not require additional medication but topical steroid may be applied to surrounding skin the same day. A barrier ointment may improve comfort and healing. Post-procedure discomfort mirrors other minor skin injuries, usually managed with paracetamol/acetaminophen, ibuprofen, and/or cool packs. Complete healing may require weeks. Infection is rare but presents with induration, itch, pain, and spreading redness.

## Interpretation of results

Dermatopathologic terminology is unfamiliar to many vulvar clinicians (see Appendix).<sup>22</sup> Reading the whole pathology report builds familiarity with pathologic vocabulary and diagnostic approach. Experienced pathologists often explain the histologic differential diagnosis in the comments, narrowing clinical possibilities while allowing for uncertainty.

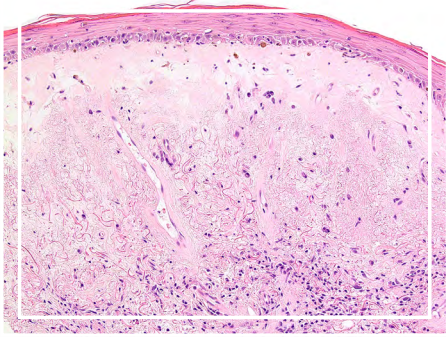
As with all medical fields, anatomic pathologists sometimes provide non-specific, false positive, or false negative results. A non-diagnostic biopsy should not overturn a sound clinical diagnosis of LS.<sup>23</sup> Some pathologists use the descriptor "early" when specimens do not display specific diagnostic features, but this word incorrectly implies a short time interval between disease development and biopsy. The preferred approach is to describe the findings and provide a dermatopathologic category or differential diagnosis.<sup>24,25</sup> The presence of dense inflammation, superinfection, or neoplasia may mask features of an underlying dermatosis.<sup>7</sup> Inflammation may cause pseudoepitheliomatous hyperplasia and/or reactive changes in cell nuclei, provoking concern for neoplasia.<sup>26,27</sup> When the pathologic result is not consistent with clinical findings, a conversation with the pathologist may reveal potential limitations of biopsy interpretation, clarify the differential diagnosis, and guide the clinical impression and treatment plan.

## Histopathology of lichen sclerosis

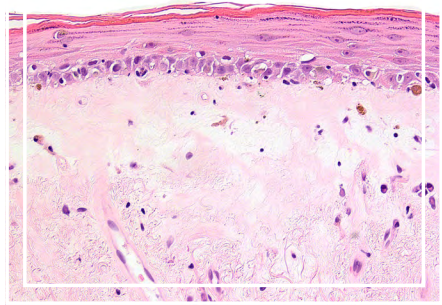
### Classic appearance

Lichen sclerosis involves two parallel processes: a lichenoid tissue reaction and dermal sclerosis seen as edematous, hyalinized, and/or fibrotic collagen change (see Chapter 1).<sup>28</sup> Multiple conditions demonstrate a lichenoid reaction so its presence alone is insufficient to diagnosis LS. Sclerosis is the key diagnostic feature of LS, but may be seen in other conditions like vestibulovaginal sclerosis.<sup>29-31</sup>

Lichen sclerosis involves hairless and hair-bearing skin but is rare on non-keratinized squamous epithelium.<sup>29</sup> The classic histopathologic features of LS are hyperkeratosis, epidermal atrophy, basal vacuolar degeneration, dermal sclerosis, and a band-like lymphocytic infiltrate under the layer of sclerosis (Fig 1a,1b). However, there is substantial variation in appearance and severity of features at each skin layer.<sup>25</sup>



**FIGURE 1a.** Classic histopathologic appearance of LS - thinned epithelium, dermal sclerosis, and a band-like lymphocytic infiltrate; H&E x100.



**FIGURE 1b.** Basal layer degeneration seen as vacuolar change and squamatization and edematous and hyalinized collagen change; H&E x200.

The stratum corneum layer may be normal, often compact rather than basket weave in appearance.<sup>8,32</sup> When parakeratotic or hyperkeratotic, the thickness is variable.<sup>3</sup> On hair bearing skin, LS sometimes shows hyperkeratosis of the uppermost section of the hair follicle, or infundibulum.<sup>25,33</sup> This results from lichenoid tissue reaction at the infundibular epithelium and yields a raised or comedone-like appearance at LS-affected hair follicles, visible on examination or dermoscopy.<sup>34</sup> Sweat glands are less commonly affected by LS, showing lymphocytosis in less than a quarter of cases.<sup>33</sup>

Epidermal thickness may be atrophic, normal, or acanthotic.<sup>25,35,36</sup> Rete ridges are usually absent in the setting of atrophy and reduced with normal epidermal thickness. When the epidermis is thickened, the rete ridges may be absent, reduced, irregularly elongated, or psoriasiform. Spongiosis and exocytosis are common.<sup>3,25,33</sup> Evidence of basal layer damage includes vacuolar change and apoptotic bodies. In the setting of abnormal basal-stromal interface, the basal keratinocyte appearance may be altered such that they resemble suprabasilar squamous cells.<sup>33,37</sup> These squamatized basal cells are horizontally orientated and enlarged with abundant eosinophilic cytoplasm and vesicular nuclei. Squamatization is likely a response to dermal scar.<sup>29</sup> When seen, the pathologist should search for other features of LS.

The basement membrane in LS is likewise variable, sometimes thickened and highlighted by the periodic acid-Schiff (PAS) stain.<sup>25,38</sup> Dermal edema, sclerosis, and fibrosis may be simultaneously present in a single specimen or patient.<sup>36</sup> Sclerosis may be focal in the papillary processes and/or superficial reticular dermis, or primarily perivascular.<sup>25,33</sup> There is no clear minimum quantity of sclerosis to justify a diagnosis of LS; instead the pathologist makes a holistic assessment of the specimen.<sup>24,26</sup> The lymphocytic infiltrate may be scant, moderate, or dense. In addition to the band-like infiltrate, there may be superficial and/or deep perivas-

cular and/or perineural lymphocytic infiltrates.<sup>33</sup> Multiple cell types may be present in varying ratios and locations to include histiocytes, plasma cells, neutrophils, and/or eosinophils.<sup>3,33,38</sup>

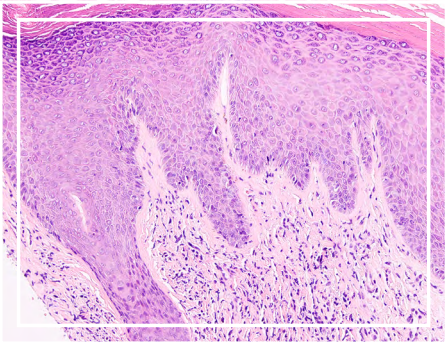
Clinical observations of hemorrhage, abnormal pigmentation, and blistering in LS are mirrored in histopathologic findings. Fresh hemorrhage may arise from fragile telangiectatic vessels and is seen as extravasated red cells. These are taken up by macrophages and converted to hemosiderin, yielding an orange-brown color. In darker-skinned individuals or in areas of melanosis, basal layer damage leads to more pigment incontinence when compared to lighter-toned skin. Blistering represents separation of epidermis from dermis. This may occur more readily in LS due to the abnormal epidermal-dermal interface and likelihood of minor trauma or contact dermatitis.

Immunohistochemistry is not helpful in the diagnosis of LS. Proliferative markers Ki-67 and MCM3 may be overexpressed in vulvar LS compared to normal genital skin or extragenital LS.<sup>39</sup> There is variable expression of p53, from intermittent light to moderate basal nuclear staining to a pattern of near-continuous moderate to dark staining of basal and suprabasilar nuclei.<sup>40</sup> Integration of oncogenic HPV DNA produces block-positive p16, regardless of underlying dermatosis. Non-block-positive p16 patterns seen in LS include patchy nuclear and cytoplasmic staining and a 'mosaic' appearance.<sup>7,41</sup>

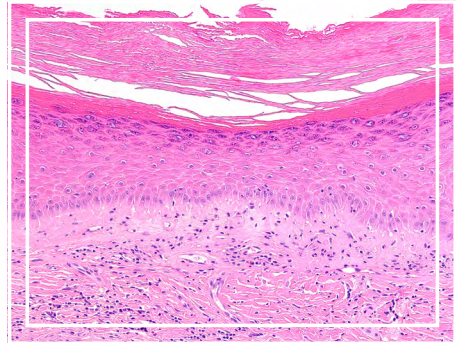
## Variation in histopathologic manifestations of LS

### Lichenified lichen sclerosis (Fig 2,3)

The commonest symptom of LS is itch, so histological effects of rubbing are often seen superimposed on LS.<sup>42</sup> This manifests as hyperkeratosis, focal parakeratosis, and acanthosis that may be flat or with elongated rete ridges. Scratching produces excoriations that appear as narrow diameter V-shaped erosions or superficial ulcers that usually show epithelial neutrophils and a thin layer of fibrin deposition beneath the excoriations.<sup>3</sup> The pathologist describes these findings in the microscopy section of the report and may provide comment as to their significance, but when they accompany basal layer degeneration and sclerosis the final pathological diagnosis remains 'lichen sclerosis' rather than 'lichen sclerosis with lichen simplex chronicus'.



**FIGURE 2.** LS with superimposed LSC: hyperkeratosis, hypergranulosis, acanthosis with irregular rete ridges, sclerosis, vertical papillary fibrosis, and a lymphocytic infiltrate; H&E x100.



**FIGURE 3.** LS with superimposed LSC: marked hyperkeratosis, hypergranulosis, flat acanthosis, sclerosis, and a lymphocytic infiltrate; H&E x200.

## Erosive LS (Fig 4)

Erosive LS is an unusual clinicopathologic subtype combining erosion and diagnostic features of LS, seen clinically as red or pink shiny patches on a background of pallor.<sup>3</sup> This subtype of LS appears to mostly affect hairless skin and has a gentle slope between intact and eroded epithelium. Patients are usually on potent topical corticosteroids; adequate steroid treatment does not reliably resolve the erosion. In contrast, ulcers in LS are more likely to have an abrupt transition between intact and ulcerated epidermis and occur in patients with diabetes, incontinence, excoriation, undertreatment of LS, and elevated risk of HPV-I VIN and SCC.<sup>3</sup>

## Non-sclerotic LS

Non-sclerotic LS (NSLS) is a concept, not a diagnosis, and occurs in around 25% of LS cases. It describes the situation of obvious clinical LS and biopsy from LS-affected skin that does not show sclerosis.<sup>35,43</sup> Support for the LS diagnosis may also arise from previous, concurrent, or subsequent diagnostic biopsies taken from areas with similar appearance.

The four categories of NSLS are lichenoid dermatitis (Fig 5), hypertrophic lichenoid dermatitis (Fig 6), dermal fibrosis with normal epidermis, and dermal fibrosis with hypertrophic epidermis (Table 2).<sup>24</sup> Hypertrophic dermatitis is especially difficult to interpret. Psoriasis may show basilar lymphocytosis and suprabasilar apoptotic keratinocytes, mimicking a lichenoid tissue reaction. As a definite diagnosis is not possible in NSLS, instead the pathologist generates a differential diagnosis depending on the appearance. Use of the phrase 'early LS' is not recommended as absent sclerosis does not reflect duration or clinical severity of disease.<sup>43</sup>

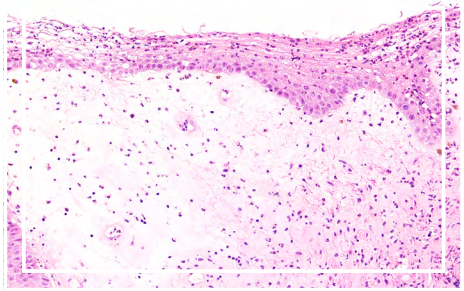


FIGURE 4. Erosive LS: loss of upper epithelium with intraepithelial neutrophils, regenerative basal layer change, edematous sclerosis, and lymphocytic infiltrate; H&E x200.

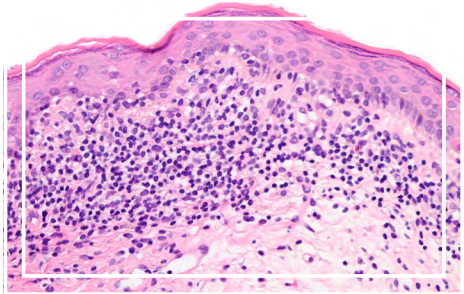


FIGURE 5. Lichenoid dermatitis: thinned epithelium, basal layer degeneration, and a closely-applied band-like lymphocytic infiltrate; H&E x200.

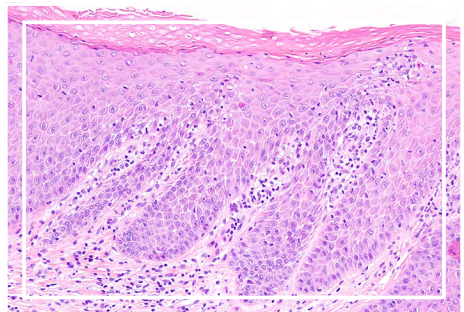


FIGURE 6. Hypertrophic lichenoid dermatitis: hyperkeratosis and parakeratosis, hypogranulosis, regular acanthosis, basal layer degeneration at tops of papillary processes, and a lymphocytic infiltrate; H&E x100.

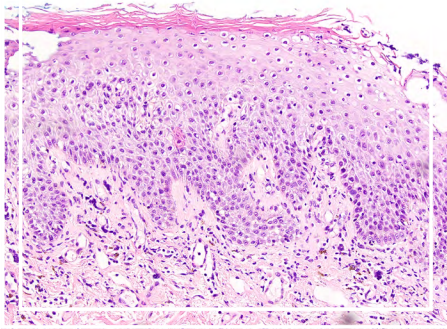


**TABLE 2 Four subtypes of non-sclerotic lichen sclerosis**

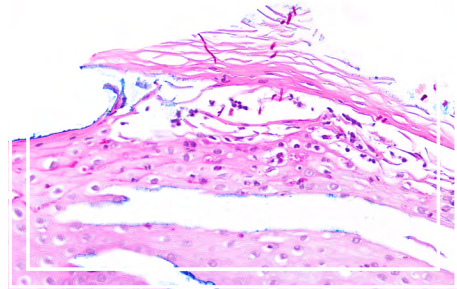
	Lichenoid dermatitis	Hypertrophic lichenoid dermatitis	Normal epidermis, dermal fibrosis	Hypertrophic epidermis, dermal fibrosis
Epidermis	Lichenoid tissue reaction	Acanthosis Lichenoid tissue reaction may be confined to tips or tops of rete ridges	Normal	Acanthosis Lichenoid tissue reaction may be confined to tips or tops of rete ridges
Dermis	Normal collagen	Normal or minimally fibrotic collagen	Dermal fibrosis	Dermal fibrosis
Differential	<ul style="list-style-type: none"> <li>• Lichen sclerosis</li> <li>• Classic lichen planus</li> <li>• Level 1 melanoma</li> <li>• Imiquimod use</li> <li>• Graft versus host</li> </ul>	<ul style="list-style-type: none"> <li>• Lichen sclerosis</li> <li>• Hypertrophic lichen planus</li> <li>• Psoriasis</li> <li>• Candidiasis</li> </ul>	<ul style="list-style-type: none"> <li>• Lichen sclerosis</li> <li>• Scar: obstetrical, surgical, or other trauma</li> </ul>	<ul style="list-style-type: none"> <li>• Lichen sclerosis</li> <li>• Lichen simplex chronicus</li> </ul>
Incidence	Common	Unusual	Unusual	Common in the elderly and/or skin adjacent to neoplasia
Comment	Most cases are lichen sclerosis clinically			Horizontal collagen fibres with lines of lymphocytes trapped between fibres suggests LS

## Loss of diagnostic features with superimposed infection or neoplasia

Superinfection with *Candida albicans* is common in patients with LS: 16% of patients with recurrent candidiasis had LS or LP, 19% of patients with biopsy-proven comorbid LS and LP had candidal superinfection, and 62.5% of patients with visible fungal organisms on biopsy also had LS or LP.<sup>8,44,45</sup> Clinical risk factors include obesity, diabetes mellitus, immunosuppression, skin occlusion, incontinence, recent antibiotics use, systemic and topical estrogen, and topical steroids. The histologic findings of candidiasis are subcorneal or corneal neutrophils, acanthosis, spongiosis, and perivascular infiltrate (Fig 7a).<sup>46</sup> Routine performance of PAS facilitates detection of fungal organisms in the stratum corneum but cannot distinguish between candidiasis and dermatophytosis (Fig 7b).<sup>45</sup> Inflammation and epithelial alterations due to candidiasis may complicate assessment for LS. Moreover, alterations in cytokine-mediated pathways and the dermal-epidermal interface may obscure or eliminate basal layer degeneration and dermal hyalinization.<sup>24</sup> Although documentation in the literature is minimal, a similar situation may occur with HSV and condyloma in which features of LS are lost at the infectious lesion but remain visible in adjacent skin.



**FIGURE 7a.** LS with mycosis: erosion with subcorneal neutrophils, acanthosis with irregular rete ridges, sclerosis, and lymphocytic infiltrate; H&E x100.



**FIGURE 7b.** LS with mycosis: fungal elements and neutrophils in the stratum corneum; PAS x400.

Both condyloma and HSIL are more common in LS compared to unaffected skin.<sup>47</sup> This may relate to erosions providing increased access of HPV to the basal layer and to topical immunosuppression from treatment, but use of steroids is not associated with increased recurrence of HSIL.<sup>48</sup> Neoplasia changes basal cell epitopes and modifies the immunologic interaction between epithelium and stroma. At the site of HSIL overlapping or adjacent to LS or LP, basal layer degeneration was absent in 79% and dermal sclerosis was lost in 57%.<sup>7</sup> Among patients with HPV-16 or vulvar aberrant maturation, all but 3 of whom had clinical or histologic diagnosis of LS, only 56% of specimens had underlying stromal sclerosis.<sup>41</sup> For this reason, analysis of the relationship between neoplasia and vulvar dermatosis should incorporate data from sources other than the excisional specimen (see Chapter 11).

## Differential diagnosis and role of clinicopathologic review

There are several conditions in the differential diagnosis of LS in addition to those in Table 2. Radiotherapy may cause sclerosis, but it also induces or exacerbates vulvar LS, making post-radiation skin assessment difficult and prone to diagnostic misallocation.<sup>49,50</sup> Morphea is localized scleroderma and this may be associated with extragenital LS, but this combination has not been reported on the vulva.<sup>51</sup> Vestibulovaginal sclerosis is uncommon, has a characteristic location between the clitoral frenulum and urethra, and is non-responsive to topical steroids. Histologically there is hyperkeratotic or normal epithelium, a band of stromal sclerosis without an inflammatory reaction, and often basal layer squamatization.<sup>29-31</sup> It is postulated to be a separate condition to LS as it occurs in squamous epithelium of vagina and vestibule rather than epidermis, and the patient does not have LS elsewhere.

When clinical examination is not convincing for LS and sclerosis is absent, there are several diagnostic possibilities. Multidisciplinary discussion with clinical images and photomicrographs helps to narrow the list of potential conditions. Distinguishing LSC and LS is a common problem. While the pathologist can usually resolve this quandary, papillary fibrosis may be difficult to distinguish from focal thin sclerosis. Lichen simplex chronicus is the favored diagnosis when basal layer degeneration is absent.<sup>26</sup>

Classic and hypertrophic LP share clinical features with lichenified or superinfected LS. When there is a lichenoid reaction without sclerosis, it is not possible to definitively distinguish between LS and LP. Clues to classic LP include spiky rete ridges and confluent involvement of hair follicles.<sup>52</sup> Hypertrophic LP is suggested by scale crust, thick parakeratosis, and basal layer degeneration with exocytosis confined to the tips or tops of irregular rete ridges.<sup>53</sup> Erosive LP is more readily differentiated from LS on skin inspection, but comorbid LS and erosive LP is often seen in practice. The shiny red patches of erosive LP in vestibule and inner labia minora about the pallor and texture change of LS on outer labia minora, periclitoral structures, interlabial sulci, and perineum. A biopsy taken at the junction between red and white may be diagnostic for both entities, or may show a non-specific lichenoid dermatitis.<sup>8</sup>

Vitiligo appears as depigmented skin without change to vulvar texture or architecture. It results from immune-mediated destruction of epidermal melanocytes, seen histologically as normal skin that lacks junctional melanocytes, verified with negative SOX-10.<sup>54</sup> Vitiligo may show a mild lymphocytic infiltrate and thickened basement membrane that may mimic sclerosis. While often independent, vitiligo may be comorbid with LS and occur adjacent to or within areas of LS.<sup>4,55</sup>

## Limitations of the literature

As with many routine procedures, there is scant research into technique, timing, location, complications, patient experience, and diagnostic accuracy of vulvar biopsy. Many important questions about the histopathology of LS remain unanswered. It is unknown if LS ever spontaneously remits with histopathology showing no evidence of the prior condition. The effect of topical steroids on histopathology of LS remains unstudied so it is unclear if or how often an adequate dose and duration normalizes biopsy findings. The common clinical question of how long to cease topical steroids prior to biopsy to maximise the chance of a diagnostic result does not have an evidence-based answer. The evolution of histopathologic manifestations over time is not reliably documented, nor is the impact of systemic immunosuppressive medications. Finally, the goal of an immunohistochemical marker panel that reliably differentiates between LS, LP, and HPV-I VIN remains elusive.

## Conclusions and recommendations

Clinical indications for biopsy in LS include concern for neoplasia, unsure diagnosis, non-response to adequate treatment, and desire to document the diagnosis and justify lifelong treatment. Biopsy techniques most suitable for LS include punch, forceps, and suture-assisted snip with selection driven by indication for sampling, location, and provider preference. A complete pathology request form includes site, laterality, suspected diagnosis, key differentials, and pertinent history of neoplasia. Histopathology of LS shows variation across the stratum corneum, epidermis, and dermis, but diagnosis requires basal layer degeneration in combination with dermal sclerosis. Clinicopathologic correlation aids in distinguishing between LS and other conditions in the differential diagnosis, especially when examination is suggestive but sclerosis is absent.



- When there is concern for neoplasia, biopsy all morphologically distinct sites and the worst-appearing area within each unique lesion.
- When undertaking biopsy to establish a diagnosis, sample an area with the most prominent LS characteristics.
- Describe the biopsy location using anatomic terms and laterality, rather than an isolated clock-face position.
- Non-diagnostic biopsy should not overturn a sound clinical diagnosis of LS.

## References

1. Kirtschig G, Cooper S, Aberer W, et al. Evidence-based (S3) Guideline on (anogenital) Lichen sclerosis. *J Eur Acad Dermatol Venereol.* 2017;31(2). doi:10.1111/jdv.13740
2. Yeon J, Oakley A, Olsson A, et al. Vulvar lichen sclerosis: An Australasian management consensus. *Australas J Dermatol.* 2021;62(3):292-299. doi:10.1111/ajd.13594
3. Day T, Otton G, Dennerstein G, Tran H, Scurry J. Erosive Lichen Sclerosis—A Clinicopathologic Subtype. *J Low Genit Tract Dis.* 2021;25(3):255. doi:10.1097/LGT.0000000000000607
4. Esse I, Rodriguez KH, Kassels A, Shiu J, Kraus CN. Vulvar lichen sclerosis and vitiligo: Overlap and clinical features. *J Am Acad Dermatol.* 2023;89(4):839-841. doi:10.1016/j.jaad.2023.06.016
5. Lewis FM, Tatnall FM, Velangi SS, et al. British Association of Dermatologists guidelines for the management of lichen sclerosis, 2018. *Br J Dermatol.* 2018;178(4):839-853. doi:10.1111/bjd.16241
6. Heller DS, Day T, Allbritton JJ, et al. Diagnostic Criteria for Differentiated Vulvar Intraepithelial Neoplasia and Vulvar Aberrant Maturation. *J Low Genit Tract Dis.* 2021;25(1):57-70. doi:10.1097/LGT.0000000000000572
7. Lin A, Day T, Ius Y, Scurry J. Anogenital High-Grade Squamous Intraepithelial Lesion Comorbid With Vulvar Lichen Sclerosis and Lichen Planus. *J Low Genit Tract Dis.* 2020;24(3):311-316. doi:10.1097/LGT.0000000000000540
8. Day T, Moore S, Bohl TG, Scurry J. Comorbid Vulvar Lichen Planus and Lichen Sclerosis. *J Low Genit Tract Dis.* 2017;21(3):204-208. doi:10.1097/LGT.0000000000000307
9. Ireland PA, Borruso L, Spencer SKR, Rosen R, Rosen R. Direct oral anticoagulants in skin surgery: a systematic review of their complications and recommendations for perioperative management. *Int J Dermatol.* Published online November 27, 2023;ijid.16916. doi:10.1111/ijid.16916
10. Wahie S, Lawrence CM. Wound Complications Following Diagnostic Skin Biopsies in Dermatology Inpatients. *Arch Dermatol.* 2007;143(10). doi:10.1001/archderm.143.10.1267
11. Akiyama Y, Norimatsu Y, Ohno Y. Prophylactic antimicrobials may not be needed to prevent surgical site infection after skin biopsy: a retrospective study. *Antimicrob Resist Infect Control.* 2022;11(1):35. doi:10.1186/s13756-022-01077-z
12. Williams LK, Weber JM, Pieper C, Lorenzo A, Moss H, Havrilesky LJ. Lidocaine—Prilocaine Cream Compared With Injected Lidocaine for Vulvar Biopsy: A Randomized Controlled Trial. *Obstet Gynecol.* 2020;135(2):311-318. doi:10.1097/AOG.0000000000003660
13. Gonzalez R, Dunn A, Williams L, et al. Histopathology after lidocaine/prilocaine cream administration for vulvar biopsy. *J Cutan Pathol.* 2021;48(10):1239-1245. doi:10.1111/cup.14018
14. Cazes A, Prost-Squarcioni C, Bodemer C, Heller M, Brousse N, Fraitag S. Histologic Cutaneous Modifications After the Use of EMLA Cream, A Diagnostic Pitfall: Review of 13 Cases. *Arch Dermatol.* 2007;143(8). doi:10.1001/archderm.143.8.1074
15. Lewis FM, Agarwal A, Neill SM, Calonje JE, Stefanova CM. The spectrum of histopathologic patterns secondary to the topical application of EMLA<sup>®</sup> on vulvar epithelium: clinicopathological correlation in three cases. *J Cutan Pathol.* 2013;40(8):708-713. doi:10.1111/cup.12155
16. Seiverling EV, Ahrens HT, Bacik LC, Usatine R. Biopsies for skin cancer detection: Dispelling the myths. *J Fam Pract.* 2018;67(5):270-274.
17. Tuil A, Bergeron C, Lucet JV, et al. Vulvar biopsy: Punch biopsy or cervical forceps biopsy? *J Gynecol Obstet Hum Reprod.* 2023;52(10):102667. doi:10.1016/j.jogoh.2023.102667
18. Glick J, Kaur R, Siegel D. Achieving hemostasis in dermatology-Part II: Topical hemostatic agents. *Indian Dermatol Online J.* 2013;4(3):172. doi:10.4103/2229-5178.115509
19. Coakley A, Wu MJ, Kumar J, et al. A Comparison of Ferric Subsulfate Solution, Silver Nitrate, and Aluminum Chloride for Pain Assessment, Time to Hemostasis, and Cosmesis in Acrochordon Snip Excision. *J Clin Aesthetic Dermatol.* 2020;13(12):32-37.

20. Ciciliano JC, Sakurai Y, Myers DR, et al. Resolving the multifaceted mechanisms of the ferric chloride thrombosis model using an interdisciplinary microfluidic approach. *Blood*. 2015;126(6):817-824. doi:10.1182/blood-2015-02-628594
21. Day T, Knight V, Dyall-Smith D, et al. Interpretation of Nondiagnostic Vulvar Biopsies. *J Low Genit Tract Dis*. 2018;22(1):74-81. doi:10.1097/LGT.0000000000000366
22. Reutter JC. High-Yield Vulvar Histopathology for the Clinician. *Obstet Gynecol Clin North Am*. 2017;44(3):329-338. doi:10.1016/j.ogc.2017.05.001
23. McCarthy S, MacEoin N, O'Driscoll M, O'Connor R, Heffron CCB, Murphy M. Should We Always Biopsy in Clinically Evident Lichen Sclerosus? *J Low Genit Tract Dis*. 2019;23(2):182-183. doi:10.1097/LGT.0000000000000457
24. Day T, Selim MA, Allbritton JI, Scurry J, Committee (DPDC) for the IDPD. Nonsclerotic Lichen Sclerosus: Definition of a Concept and Pathologic Description. *J Low Genit Tract Dis*. 2023;27(4):358. doi:10.1097/LGT.0000000000000760
25. Regauer S, Liegl B, Reich O. Early vulvar lichen sclerosus: a histopathological challenge. *Histopathology*. 2005;47(4):340-347. doi:10.1111/j.1365-2559.2005.02209.x
26. Day T, Bohl TG, Scurry J. Perianal lichen dermatoses: A review of 60 cases. *Australas J Dermatol*. 2016;57(3):210-215. doi:10.1111/ajd.12308
27. Lee ES, Allen D, Scurry J. Pseudoepitheliomatous Hyperplasia in Lichen Sclerosus of the Vulva: *Int J Gynecol Pathol*. 2003;22(1):57-62. doi:10.1097/00004347-200301000-00012
28. Baird P. *Lichen Sclerosus et Atrophicus*. dissertation. University of Sydney; 1981.
29. Day T, Burston K, Dennerstein G, Pagano R, Scurry J. Vestibulovaginal Sclerosis Versus Lichen Sclerosus. *Int J Gynecol Pathol*. 2018;37(4):356. doi:10.1097/PGP.0000000000000041
30. Croker BA, Scurry JP, Petry FM, Fischer G. Vestibular Sclerosis: Is This a New, Distinct Clinicopathological Entity? *J Low Genit Tract Dis*. 2018;22(3):260-263. doi:10.1097/LGT.0000000000000404
31. Fadare O. Vaginal Stromal Sclerosis: A Distinctive Stromal Change Associated With Vaginal Atrophy. *Int J Gynecol Pathol*. 2011;33(3):295-300. doi:10.1097/PGP.0b013e3182005356
32. Day T, Holland SM, Scurry J. Normal Vulvar Histology: Variation by Site. *J Low Genit Tract Dis*. 2016;20(1):64-69. doi:10.1097/LGT.0000000000000162
33. Morrel B, Ewing-Graham PC, Van Der Avoort IAM, Pasmans SGMA, Damman J. Structured analysis of histopathological characteristics of vulvar lichen sclerosus in a juvenile population. *Hum Pathol*. 2020;106:23-31. doi:10.1016/j.humpath.2020.09.003
34. Borghi A, Corazza M, Minghetti S, Toni G, Virgili A. Clinical and dermoscopic changes of vulvar lichen sclerosus after topical corticosteroid treatment. *J Dermatol*. 2016;43(9):1078-1082. doi:10.1111/1346-8138.13374
35. Weyers W. Hypertrophic Lichen Sclerosus With Dyskeratosis and Parakeratosis—A Common Presentation of Vulvar Lichen Sclerosus Not Associated With a Significant Risk of Malignancy. *Am J Dermatopathol*. 2013;35(7):713-721. doi:10.1097/DAD.0b013e31827e7ea9
36. Day T, Otton G, Jaaback K, Weigner J, Scurry J. Is Vulvovaginal Lichen Planus Associated With Squamous Cell Carcinoma? *J Low Genit Tract Dis*. 2018;22(2):159-165. doi:10.1097/LGT.0000000000000384
37. Fung MA, LeBoit PE. Light Microscopic Criteria for the Diagnosis of Early Vulvar Lichen Sclerosus: A Comparison With Lichen Planus. *Am J Surg Pathol*. 1998;22(4):473-478. doi:10.1097/00000478-199804000-00013
38. Lester EB, Swick BL. Eosinophils in biopsy specimens of lichen sclerosus: a not uncommon finding. *J Cutan Pathol*. 2015;42(1):16-21. doi:10.1111/cup.12445
39. Gambichler T, Kammann S, Tigges C, et al. Cell cycle regulation and proliferation in lichen sclerosus. *Regul Pept*. 2011;167(2-3):209-214. doi:10.1016/j.regpep.2011.02.003
40. Liegl B, Regauer S. p53 immunostaining in lichen sclerosus is related to ischaemic stress and is not a marker of differentiated vulvar intraepithelial neoplasia (d-VIN). *Histopathology*. 2006;48(3):268-274. doi:10.1111/j.1365-2559.2005.02321.x
41. Day T, Marzol A, Pagano R, Jaaback K, Scurry J. Clinicopathologic Diagnosis of Differentiated Vulvar Intraepithelial Neoplasia and Vulvar Aberrant Maturation. *J Low Genit Tract Dis*. 2020;24(4):392-398. doi:10.1097/LGT.0000000000000569
42. Lynch PJ. Lichen simplex chronicus (atopic/neurodermatitis) of the anogenital region. *Dermatol Ther*. 2004;17(1):8-19. doi:10.1111/j.1396-0296.2004.04002.x
43. Weyers W. Hypertrophic lichen sclerosus sine sclerosis: clues to histopathologic diagnosis when presenting as psoriasisiform lichenoid dermatitis. *J Cutan Pathol*. 2015;42(2):118-129. doi:10.1111/cup.12457
44. Crouss T, Sobel JD, Smith K, Nyirjesy P. Long-Term Outcomes of Women With Recurrent Vulvovaginal Candidiasis After a Course of Maintenance Antifungal Therapy. *J Low Genit Tract Dis*. 2018;22(4):382-386. doi:10.1097/LGT.0000000000000413
45. Day T, Borbolla Foster A, Phillips S, et al. Can Routine Histopathology Distinguish Between Vulvar Cutaneous Candidiasis and Dermatophytosis? *J Low Genit Tract Dis*. 2016;20(3):267-271. doi:10.1097/LGT.0000000000000208

46. Day T, Chapman-Burgess E, Scurry J. Clinicopathologic Overlap of Vulvar Psoriasis and Candidiasis. *J Low Genit Tract Dis.* 2024;28(2):175-182. doi:10.1097/LGT.0000000000000801
47. Söderlund JM, Hieta NK, Kurki SH, et al. Comorbidity of Urogynecological and Gastrointestinal Disorders in Female Patients With Lichen Sclerosus. *J Low Genit Tract Dis.* 2023;27(2):156-160. doi:10.1097/LGT.0000000000000727
48. Janke MJ, DeBlanc J, Kobernik EK, et al. Comorbid Vulvar Lichen Sclerosus and High-Grade Squamous Intraepithelial Lesions: A Management Conundrum. *J Low Genit Tract Dis.* 2022;26(4):319-322. doi:10.1097/LGT.0000000000000690
49. Brandon A, Joshi T, Ahmed Z, et al. A Rare Presentation of Lichen Sclerosus Involving the Vaginal Canal After Radiation Therapy: A Case Report and Review of the Literature. *Cureus.* Published online October 15, 2023. doi:10.7759/cureus.47077
50. Petersen E, Yazdani L, Hymes SR. A case of radiation-induced bullous morphea/lichen sclerosus overlap in a breast cancer patient. *Rep Pract Oncol Radiother.* 2018;23(1):47-49. doi:10.1016/j.rpor.2017.11.004
51. Yadav D, Agarwal S, Thakur S, Ramam M. Lymphocyte-Peppered Sclerotic Collagen: An Additional Histological Clue in Lichen Sclerosus, Morphea, and Systemic Sclerosis. *Am J Dermatopathol.* 2021;43(12):935-938. doi:10.1097/DAD.0000000000002071
52. Day T, Wilkinson E, Rowan D, Scurry J. Clinicopathologic Diagnostic Criteria for Vulvar Lichen Planus. *J Low Genit Tract Dis.* 2020;24(3):317-329. doi:10.1097/LGT.0000000000000532
53. Day T, Weigner J, Scurry J. Classic and Hypertrophic Vulvar Lichen Planus. *J Low Genit Tract Dis.* 2018;22(4):387. doi:10.1097/LGT.0000000000000419
54. Park YJ, Lee H, Park HS, Kim YC. Histopathological differences between vitiligo and lichen sclerosus et atrophicus using quantitative immunohistochemical analysis. *Front Med.* 2023;10:1205909. doi:10.3389/fmed.2023.1205909
55. Veronesi G, Virdi A, Leuzzi M, et al. Vulvar vitiligo and lichen sclerosus in children: A clinical challenge. *Pediatr Dermatol.* 2021;38(5):1012-1019. doi:10.1111/pde.14771

# Differential diagnosis and comorbid vulvovaginal conditions

*Alicia Little, Švitrigailė Grincevičienė, Deana Funaro*

**W**hen patients present with vulvar white color change, epidermal atrophy, purpura and architecture change, clinicians are confident in the diagnosis of vulvar lichen sclerosus (LS). However, LS shares characteristics with other vulvar dermatoses, infectious conditions, and neoplasia. Lichen sclerosus may also coexist with other vulvar pathology, resulting in diagnostic and treatment challenges.

## Physiologic changes

The vulva undergoes changes throughout the lifespan due to hormonal variations, such as estrogen-deficient states in prepubertal girls and postmenopausal women. Vulvar manifestations of low estrogen states include smaller labia minora, flattened topography, smoothness, diminished Fordyce glands, pallor, and dryness.<sup>1,2</sup>

No two vulvas are alike. Patients with smaller labia minora combined with prominent labia majora due to adiposity may be misdiagnosed with LS. Labiaplasty, treatment for vulvar malignancy or human papillomavirus (HPV)-associated disease, and the unfortunate consequences of female genital mutilation also result in changes to vulvar appearance that may be mistaken for LS.

## Dermatologic conditions with architecture change

Several conditions other than LS affect vulvar architecture. Erosive lichen planus (LP), graft versus host disease (GVHD), autoimmune bullous diseases such as pemphigus and mucous membrane pemphigoid, drug reactions including Steven-Johnson syndrome and toxic epidermal necrolysis, Crohn's disease, and neoplasia may modify vulvar architecture.

Although the presentation of LS is variable, several clinical clues help with diagnosis when histopathology is pending, inconclusive, or unable to be obtained. Women often report skin and symptom improvement with topical steroids that reverses when medication is ceased. They may describe gradual change to the size or appearance of labia minora. Beyond history, extragenital examination including ocular and oral areas may identify LS or other conditions on the differential diagnosis (Chapter 3).<sup>3</sup>

Erosions and blisters are less common in LS and more associated with erosive LP, autoimmune bullous diseases, and drug reactions. Erosive LP and mucous membrane pemphigoid may affect multiple sites including the oropharynx, vagina, cervix, anus, conjunctiva, lacrimal ducts, and external auditory canal.<sup>4,5</sup> Diagnosing these conditions requires biopsy of lesional skin at the border of an erosion. An additional biopsy of adjacent skin sent for direct immunofluorescence permits histologic diagnosis of vesiculobullous disorders. Some laboratories request transport in a specific fixative called Zeus or Michel medium, or specimens may be directly delivered to pathologists in normal saline.<sup>6</sup>

Erosive LP is the most common type of LP found on the vulva. It appears as shiny red patches often bordered by white plaques or lacy white 'Wickham striae.'<sup>7</sup> Erosive LP may affect any non-keratinized epithelium like vagina and mouth, whereas LS typically does not. Oral LP is characterized by the same shiny red and/or white lacy patches along the gingiva, buccal mucosa, the palate, or the tongue. Extragenital hair bearing skin may show classic LP, with pink to purple polygonal pruritic papules and plaques with overlying white net-like scale.<sup>8</sup> The scalp may show perifollicular scale and erythema suggestive of lichen planopilaris, a scarring alopecia characterized by inflammation affecting the hair follicles.<sup>9</sup> Both LS and LP may co-exist in the same patient so clinicians may need to biopsy areas with different lesion morphologies to permit accurate diagnoses.<sup>10</sup> Vulvar clinicians play an important role in detecting LP at extragenital sites by asking about symptoms like difficulty chewing or swallowing, ocular pain, diminished tear formation, or hearing changes, and referring to respective specialists.

Vulvovaginal GVHD may affect 27-66% of women after allogeneic stem cell transplant (SCT), usually developing within in first year post-transplant.<sup>11</sup> The vulva is impacted as a solitary site in ~70% and there is involvement of vagina and vulva in ~25% of patients.<sup>11,12</sup> As with erosive LP, GVHD may cause vaginal adhesions and obliteration. Clinical findings suggestive of LS or LP in patients who have undergone allogeneic SCT may be considered diagnostic of chronic GVHD.<sup>12,13</sup> While patients with vulvovaginal GVHD may report pain, dyspareunia, or dryness, some patients refrain from sexual activity due to illness and may not report symptoms, emphasizing the importance of routine vulvovaginal examination of female patients after allogeneic SCT.<sup>11,12</sup>

Finally, drug reactions such as fixed drug eruption may occur at the vulva, causing chronic erosive or nonspecific recurrent red patches or plaques. The differential diagnosis for this includes erosive LP, plasma cell vulvitis, contact dermatitis, and candidiasis. When perfectly circular erosions are present, over-the-counter and prescription drug intake causing fixed drug eruptions is often the culprit.<sup>14,15</sup>

## **Dermatologic conditions that do not cause architectural change**

There are several conditions that resemble LS but do not cause architecture change. The most common are lichen simplex chronicus (LSC), irritant and allergic contact dermatitis, vitiligo, and psoriasis. Localized scleroderma, or morphea, resembles LS, but is rarely reported on the vulva.<sup>16,17</sup> Clinicians may find differentiating their clinical features from LS challenging and multiple conditions may be concurrent, complicating the diagnostic process.

## Lichen simplex chronicus

Chronic dermatitis may occur anywhere on the body and is identified by lichenified, often poorly marginated plaques characterized by thickened skin and deepened skin markings.<sup>18</sup> The scale characteristic of extragenital LSC may not be present at moist vulvar skin. Lichen simplex chronicus is the result of an itch-scratch cycle, but the underlying causes of itch are variable and often not immediately apparent. Scratching leads to overlying angulated crusted erosions, often linear and favoring the side of the dominant hand. While usually pink-gray in patients with lighter skin types, LSC may appear hyperpigmented in patients with darker skin.<sup>19</sup> Affected skin may also appear white or pale due to traumatic post-inflammatory hypopigmentation or due to the hydration of hyperkeratosis from genital moisture.<sup>20</sup>

The pruritus of LS may result in rubbing and scratching that causes superimposed LSC. This sometimes presents a diagnostic dilemma, since lichenification obscures the classic thinned, crinkly texture change characteristic of LS. Architectural change such as clitoral phimosis or resorption of labia minora helps to identify the LS hiding beneath clinically and histopathologically-identified LSC.

## Irritant and allergic contact dermatitis

Exposure to allergens or irritants occurs via direct application, through transfer from other sites, or via urine and feces. Irritant contact dermatitis is more common than allergic contact dermatitis. Patients with genital symptoms often over-wash, and when used too frequently even water serves as an irritant (Chapter 7). A non-scented, hypoallergenic laundry detergent should also be used for clothing. Patients who develop contact dermatitis to menstrual pads may consider alternatives of leak-proof underwear, tampons, or menstrual cups.<sup>21</sup> Clinicians need to ask about urinary and fecal incontinence as patients often do not disclose these conditions (Chapter 15). Fragrances are a common source of allergy and are often found in cleansers, moisturizers, and over-the-counter medications. Medication allergen sources include topical steroids, antifungals, antibiotics, and anesthetics, commonly benzocaine. Other allergens include preservatives like methylisothiazolinone, botanical extracts, and vehicles like propylene glycol or lanolin.<sup>22–25</sup>

Elimination tests are an affordable and accessible way to remove irritants or allergens that may be causing vulvar irritation. Repeat open application test is another method patients can perform at home to see if they are sensitive to a product. Usually, a suspected product is applied to the upper inner arm or thigh for several consecutive applications to see if an eruption develops. This is most helpful for products meant to be left in place on the skin. When patients continue to suffer itch and rash after all known potential triggers have been removed, patch testing by a dermatologist may identify the cause.<sup>25–27</sup>

## Vestibulovaginal sclerosis

Vestibulovaginal sclerosis is an uncommon condition characterized by white patches or plaques in the vulvar vestibule, and appears to be a distinct entity from LS.<sup>28–30</sup> Vestibulovaginal sclerosis cases are generally asymptomatic or associated with dyspareunia. The condi-

tion is not responsive to topical estrogen or steroids. The histopathology of vestibulovaginal sclerosis demonstrates stromal sclerosis without the features of a lichenoid tissue reaction to include lymphocytic infiltrate or basal layer degeneration.<sup>28</sup>

## Vitiligo

Vitiligo is characterized by depigmentation - the absence of melanin and melanocytes - and appears as white patches with normal surface texture. The Wood's lamp is a UVA light source with peak wavelength of 320-400nm that, when applied to vitiligo, demonstrates a bright bluish-white color indicating absence of melanin.<sup>31</sup> In contrast, most LS lesions demonstrate reduced rather than absent pigmentation often accompanied by texture abnormalities.<sup>32,33</sup> However, overlap may occur, and some LS lesions demonstrate depigmentation with absent or reduced melanocytes on histopathology.<sup>34</sup> In cases of clinical ambiguity in adults, a biopsy may be performed to identify histopathologic features of LS and undertake a special stain for melanocytes (see Chapter 4).

## Psoriasis

Psoriasis is more common in patients with LS and women with both conditions may require additional topicals or consideration of systemic treatment specific to psoriasis.<sup>35,36</sup> In the vulvar area, psoriasis is pink to red and often retains well-demarcated borders as seen in extragenital lesions. Genital and inverse psoriasis typically lacks the thick silver scale pathognomonic of this condition on extensor surfaces. Asking patients if they have dry, flaky, or red areas at the scalp, ears, around the eyes, and on elbows or knees may be helpful to establish the diagnosis of psoriasis comorbid with LS. Nail manifestations are another clue for psoriasis, often seen as pitting, transverse and vertical ridges, and white-yellow areas.

## Vulvar pigmented lesions

Vulvar pigmented lesions are found in an estimated 10% of women and include melanocytic nevi, blue nevi, lentigos, melanosis, seborrheic keratosis, pigmented condylomas, squamous neoplasia, pigmented basal cell carcinomas, Merkel cell carcinoma, and melanomas.<sup>37,38</sup> Angiokeratomas are common benign vascular lesions that may appear pigmented but instead are red to purple. Clinical, histopathologic, and dermoscopic characteristics help establish these diagnoses.

## Vulvar melanosis

Melanosis represents 68% of pigmented vulvar lesions in reproductive-aged women and may be associated with LS.<sup>38,39</sup> Vulvar melanosis is benign. Clinically, hyperpigmented macules and patches are light brown to black. Lesions may be single or multiple, often irregular and asymmetrical, and are most commonly found on hairless skin and non-keratinized squamous epithelium of vestibule and labia minora.<sup>40</sup> Though the pathogenesis is unknown, it is hypothesized that inflammation enhances melanin production and sometimes increases the number of melanocytes at the dermoepidermal junction.<sup>41</sup> The dermoscopic features of

melanosis include a homogeneous or nonhomogeneous diffuse light brown, dark brown and/or black pigmentation, parallel pattern, ringlike pattern, and an absence of pigmented network.<sup>38,40</sup> Melanoma may occur in vulvar skin whether melanosis is present or not. Clinicians may need to biopsy new, changing, or raised areas or for histopathological confirmation of melanosis if the diagnosis is in doubt.<sup>37</sup>

## Melanocytic nevi

Vulvar melanocytic nevi are found in 2% of women, comprise 23% of pigmented vulvar lesions, and may be congenital or acquired.<sup>38,41</sup> Atypical genital nevi account for 5% of vulvar nevi.<sup>38,42</sup> Clinically, melanocytic nevi associated with LS may present with bleeding or pruritus and show irregular borders and brown-black pigmentation. These features require biopsy. While most vulvar melanocytic nevi are benign, the histopathologic interpretation of melanocytic nevi within LS is difficult and presents a risk of overdiagnosis of atypical nevi or melanoma.<sup>38,39,42</sup>

## Vulvar melanoma

Melanoma is a rare vulvar cancer that represents 2% of all melanomas and 6% of vulvar cancers, second only to squamous cell carcinoma. It has an estimated incidence of 0.10/100,000 women/year and primarily affects white women in the 5<sup>th</sup> to 6<sup>th</sup> decades of life.<sup>38,43,44</sup> The 5 year overall survival rate for vulvar melanoma is 47%, significantly less than the 92% survival rate in extragenital melanoma.<sup>38,43</sup> Though pathogenesis remains unclear, a combination of host predisposition, environmental factors, and local immune dysfunction may contribute to its development.<sup>44</sup> Extragenital melanomas are often related to ultraviolet light exposure and BRAF mutations are seen in 70%, while vulvar melanomas arise from a different teratogenic pathway and more often have KIT gene mutations. Vulvar benign and atypical nevi often have BRAF mutations, suggesting that vulvar melanoma arise independently of pre-existing nevi.<sup>43</sup>

Clinically, vulvar melanomas may be subtle and have a different appearance to lesions found elsewhere on the skin. On non-keratinized epithelium, melanomas are often asymmetrical raised or flat lesions with irregular borders with colors ranging across black, brown, gray, blue, and red-pink. While melanoma will often be a single lesion on keratinized skin, it may be multifocal on mucosal surfaces.<sup>37,45</sup> A systematic review of 20 cases of vulvar melanoma arising in LS postulates an association, but this is undermined by inclusion of 5 female children (see Chapter 13).<sup>46</sup> The complexity of correct histologic diagnosis of pigmented lesions in the context of LS reiterates the need for robust clinicopathological correlation often best suited to specialized centers.<sup>46–48</sup>

## Infectious conditions and LS

Treatment of LS with topical steroids may augment susceptibility to or exacerbate bacterial, fungal, and viral infections. Patients often attribute escalating itch or pain to a LS flare, but on evaluation there may be an infectious explanation for worsening symptoms (see Chapter 9).



## Yeast

Vulvovaginal yeast infections are common, with 70-75% of women experiencing at least one episode in their lifetime and 5-10% suffering from recurrent episodes.<sup>49,50</sup> *Candida albicans* is responsible for 85-95% of cases, with most of the remainder attributed to *C. glabrata*, *C. parapsilosis*, *C. tropicalis*, *C. lusitaniae*, *C. krusei*, and *Saccharomyces cerevisiae*.<sup>49,51</sup> There are four categories of vulvovaginal candidiasis (VVC): acute, recurrent, chronic, and cutaneous.<sup>50,52-55</sup> The first three arise mostly in estrogenized women, many of whom are otherwise healthy. In contrast, cutaneous candidiasis usually occurs in postmenopausal women with risk factors that include obesity, diabetes, immunosuppression, incontinence, skin occlusion, topical corticosteroids, IL-17 inhibitors, exogenous estrogen, topical or systemic antibiotics, and SGLT-2 inhibitors.<sup>51,54,56-59</sup>

Symptoms vary according to sites involved and include itch, burning, sexual pain, rash, fissures, edema, and abnormal discharge. Cutaneous candidiasis appears as pink-red patches and plaques, often accompanied by edema, maceration, satellite lesions, thin peripheral scale, and superficial pustules.<sup>54,56</sup> Diagnostic strategies vary by jurisdiction and specialty and may involve wet mount microscopy, molecular testing, vulvovaginal culture, and/or culture of skin scrapings. Genital colonization with *Candida* species is common so testing is not useful in asymptomatic patients. Treatment decisions likewise are dictated by the site, severity, comorbid conditions, and local protocols. Adjunctive prophylactic oral antifungal treatment complements topical steroid maintenance therapy in patients susceptible to yeast infections.<sup>54-56,60</sup> The sparse available clinical guidance on treatment of cutaneous candidiasis does not recommend products that are a combination of topical steroid and antifungal, noting the steroid component may improve clinical but not mycological cure rates and quality of evidence in this area is suboptimal.<sup>55,61</sup>

## Dermatophytes

Vulvar dermatophyte infection, also called tinea genitalis or cruris, is less common than candidiasis. Responsible pathogens include *Trichophyton rubrum*, *Trichophyton mentagrophytes*, and *Epidermophyton floccosum*.<sup>62</sup> Tinea cruris presents as a dry, thin, pink to red plaque with scale. Evaluation of intertriginous areas, feet, and toenails helps establish diagnosis. When superficial tinea infections are treated with topical steroids, dermatophytes may extend into the hair follicle and establish an atypical papulonodular appearance, called Majocchi's granuloma.<sup>63-65</sup> Tinea incognito is another possibility when topical steroids are applied to dermatophyte infection, resulting in persistent symptoms and an atypical pink-red papular rash with variably-demarcated borders.<sup>66,67</sup>

Diagnosis is primarily clinical with attempted confirmation via skin scraping sent for culture. The sensitivity of culture in clinically suspected cases is poor, with positive test rates of 14-83%.<sup>56,68-70</sup> Fungal elements are sometimes seen on histopathology and may establish the primary diagnosis or identify a secondary process. Biopsy cannot distinguish between yeast and dermatophytes.<sup>56</sup> Dermatophyte treatment involves topical or oral terbinafine or -azoles, with route and duration dependent on location, extent, and patient comorbidities.<sup>62,65</sup> Nystatin is ineffective in treating dermatophyte infection.

## Genital herpes

Genital herpes arising in LS usually presents as painful grouped vesicles and erosions on an erythematous base, but also may manifest as papules, ulcers, fissures, and crusts.<sup>56</sup> Most clinically-recognized cases of genital herpes are caused by herpes simplex virus (HSV)-2, which has a seroprevalence around 15%.<sup>71,72</sup> HSV-1, often acquired in childhood from orolabial contact and with a global seroprevalence over 60%, is responsible for a rising percentage of genital lesions.<sup>72</sup> The relative distribution of HSV-1 and HSV-2 at genital lesions varies by age, gender, ethnicity, sexual partner type and practices, and geographic region.<sup>71,73,74</sup> The rate of symptomatic recurrence after HSV-2 acquisition is 70-90%, compared to 20-50% after HSV-1 genital infection.<sup>71</sup>

Between 65-90% of patients with genital HSV are unaware of their diagnosis as their symptoms or lesions have not been attributed to HSV.<sup>71,74</sup> Immunosenescence and topical steroids for LS may unveil HSV in older women who report no previous lesions and no sexual contact for decades. Clinicians explain this usually represents reactivation from a distant viral exposure, rather than new infection. Molecular testing has replaced viral culture as the mechanism to diagnose visible lesions, but timing influences the result reliability. While HSV-2 IgG usually confirms genital herpes, positive HSV-1 IgG occurs in both orolabial and genital cases. Serologic testing is not part of the routine evaluation of suspected HSV, but may be useful in specific scenarios: 1) recurrent localized symptoms but no current lesion amenable to testing, or 2) using results from each partner to inform discordant couples about transmission risk reduction.<sup>71</sup> Suppressive antiviral medication is useful for patients with recurrences that impact on quality of life or LS management and those who wish to reduce viral shedding.<sup>71</sup> Persistent, chronic, or hypertrophic lesions may require a short hiatus from topical steroids and sometimes multimodal systemic therapies.<sup>75</sup>

## Human papillomavirus

Anogenital condylomas may be flat, frond-like, hyperkeratotic, papular, or lobular.<sup>76</sup> Women with LS may identify them as a new lump. As with HSV, anogenital condyloma may be a new diagnosis for older women with LS even though their exposure to HPV occurred many decades ago. Unless women have typical lesions and a previous history of warts, biopsy is useful to exclude high grade squamous intraepithelial neoplasia (HSIL) or HPV-independent vulvar intraepithelial neoplasia (HPV-I VIN) (see Chapter 11). Treatment options include patient- or provider- applied topicals, cryotherapy, curettage, laser, or excision and depends on size, location, patient-preference, cost, and provider experience.<sup>77</sup>

## Bacterial infections

Bacterial infections superimposed on LS include impetigo, folliculitis, furuncle, abscess, erysipelas, cellulitis, and ecthyma gangrenosum, a necrotic infection caused by gram-negative bacteremia in immunosuppressed patients.<sup>78</sup> Conditions affecting patient susceptibility to infections include vulvovaginal colonization with *Staphylococcus* or *Streptococcus*, obesity, immunosuppression, topical and systemic corticosteroids, uncontrolled diabetes, and hy-

giene and hair removal practices.<sup>78,79</sup> Symptoms of itch and pain may be interpreted as a flare of LS rather than a new event. Clinical signs like oozing, crusting, blistering, swelling, edema, and surface warmth may signal bacterial infection. Clinicians obtain a targeted culture before instituting empiric antibiotics based on clinical appearance, severity, known colonization status, local antibiotic susceptibilities, and medical comorbidities.

## Vaginitides

The *ISSVD Disease Recommendations for the Diagnosis and Treatment of Vaginitis* provides detail on conditions causing abnormal discharge. Any of these conditions may be comorbid with or exacerbate LS. Increased discharge and associated hygiene practices may provoke vulvar symptoms, and the cytokine cascade associated with inflammatory processes may produce a field effect. Bacterial vaginosis (BV) is a variably symptomatic microbiome alteration that may produce malodorous discharge, sexual discomfort, and increased risk of pelvic infection. Diagnosis involves wet mount demonstrating clue cells, vaginal pH >4.5, and amine odor when vaginal fluid is exposed to 10% potassium hydroxide.<sup>80,81</sup> In settings without access to wet mount, several molecular tests for *Gardnerella vaginalis* are commercially available but have limitations. Colonization with *G. vaginalis* occurs in women without BV, and some women have BV but *G. vaginalis* is absent. Bacterial vaginosis may recur or persist and require suppressive therapy with oral or topical metronidazole, topical clindamycin, and/or boric acid pessaries.<sup>82</sup>

Desquamative inflammatory vaginitis (DIV), also considered a severe form of aerobic vaginitis, is a condition of unclear etiology characterized by copious discharge and vulvovaginal discomfort.<sup>81</sup> Examination may show confluent or patchy erythema or petechiae over non-keratinized squamous epithelium with features sometimes extending onto the vulva.<sup>83</sup> This appearance may be confused with erosive LP, but DIV does not cause vaginal adhesions. Wet mount microscopy shows increased white blood cells and parabasal cells.<sup>84</sup> In settings without wet mount, historical non-response to other treatments in combination with non-erosive vaginal inflammation and exclusion of candidiasis suggests the diagnosis.<sup>85</sup> Histopathology demonstrates a combination of thinned spongiotic epithelium, intraepithelial or stromal hemorrhage, vascular congestion, and lymphoplasmacytic infiltrate.<sup>83</sup> A similar clinical, microscopic, and histologic presentation occurs with trichomoniasis, so this infection should be excluded.<sup>86</sup> Among women with histologic evidence of DIV or plasma cell vulvitis, 8% also had LS.<sup>83</sup> Initial treatment often involves intravaginal clindamycin or steroids, sometimes in combination. As with other vaginitides, DIV may be recurrent or chronic and require ongoing suppressive therapy.<sup>81,83,84,86</sup>

## Psychosexual conditions

An array of psychosexual conditions affect women with LS. Patients may have underlying concerns about sexual function, attractiveness to a partner, decreased quality of life, and anxiety or depression (see Chapter 8). Structural vulvar changes are associated with increased risk of anxiety or poor genital self-image.<sup>87,88</sup> Feelings of inadequacy, to include a belief LS makes someone 'less attractive,' 'less feminine,' or 'not right,' affects emotional well-

being and sexual functioning, and may impact on intimate relationships and reduce sexual desire.<sup>89–92</sup> Supportive education about LS, discussing pelvic floor relaxation techniques, and referring to sexology, psychology, or pelvic floor physiotherapy help to ameliorate the sexual health impacts of LS.<sup>93</sup> Almost half of women across the lifespan with LS have depression.<sup>90,91,94</sup> Treatment of LS is associated with a decrease in depressive episodes and anxiety disorders.<sup>95</sup> Vulvar clinicians play a role in identifying and addressing depression and anxiety, in concert with other involved clinicians.<sup>96</sup>

## Neoplasia

Vulvar squamous precursor lesions are categorized as HPV-associated or HPV-I and both may occur within LS (see Chapter 11). The appearance of precursor lesions is variable and neoplastic etiology cannot be reliably distinguished on examination. Biopsy is required for white or pink-red patches and plaques that look different to the surrounding skin or do not respond to daily potent topical steroid ointment (see Chapter 9). Imiquimod, laser, and excision are treatment options for HSIL, but the management of HPV-I VIN is excision.<sup>97</sup> Regardless of etiology, clinicians maintain optimal control of LS and provide ongoing surveillance for early detection of recurrent neoplasia.

Primary EMPD is an intraepidermal cutaneous adenocarcinoma that has the potential for invasive disease. Secondary EMPD is the result of epidermotropic metastasis of an underlying malignancy, most commonly gastrointestinal and genitourinary carcinoma.<sup>98</sup> Vulvar EMPD may be asymptomatic or characterized by pruritus, or less commonly burning, pain, discharge or bleeding.<sup>99</sup> It may present with eczematous-appearing pink or red patches or plaques, often with scattered areas of white scale. However, lesions may be hypopigmented, dark red, nodular, or pigmented, and may be eroded or ulcerated. Biopsies of suspected neoplasia in patients with LS must be accompanied with pertinent clinical information and accurate labeling to inform the pathologist's approach (see Chapter 4). There is scant reporting of LS comorbidity with EMPD.<sup>100</sup> Treatment options include imiquimod, laser, or excision, and is often multimodal.<sup>98,99</sup>

## Conclusion and recommendations

While LS has a characteristic clinical appearance, there are multiple conditions to consider in the differential diagnosis, with LSC and vitiligo as the most common sources of confusion. Clinicians often encounter comorbid dermatologic conditions adjacent to or superimposed on LS, especially LP, dermatitis, and psoriasis. Candidiasis frequently complicates LS as most affected women have one or more risk factors for genital mycosis. Genital herpes, vaginitides, and psychosocial conditions are prevalent across the lifespan and thus occur in women with LS, sometimes contributing to reduced symptom control. Clinicians undertaking LS surveillance aim for early detection of HPV-associated lesions, HPV-I VIN, and EMPD to enable effective and less invasive treatment options.

- Biopsy may be helpful to distinguish between LS and competing diagnoses, but a non-specific biopsy does not exclude LS.

- Clinicopathologic assessment of melanocytic lesions in LS is difficult, fraught with the potential for overdiagnosis of melanoma, and best suited to specialized centers.
- Vulvar clinicians play a role in identification and care of other conditions that occur commonly in women to include genitourinary syndrome of menopause, infections, vaginitis, and psychosexual disorders.

## References

1. Cohen Sacher B. The Normal Vulva, Vulvar Examination, and Evaluation Tools. *Clin Obstet Gynecol.* 2015;58(3):442-452. doi:10.1097/GRF.0000000000000123
2. Farage M, Maibach H. Lifetime changes in the vulva and vagina. *Arch Gynecol Obstet.* 2006;273(4):195-202. doi:10.1007/s00404-005-0079-x
3. Eisen D. The evaluation of cutaneous, genital, scalp, nail, esophageal, and ocular involvement in patients with oral lichen planus. *Oral Surg Oral Med Oral Pathol Oral Radiol Endodontology.* 1999;88(4):431-436. doi:10.1016/S1079-2104(99)70057-0
4. Ebrahimi M, Lundqvist L, Wahlin YB, Nylander E. Mucosal Lichen Planus, a Systemic Disease Requiring Multidisciplinary Care: A Cross-Sectional Clinical Review From a Multidisciplinary Perspective. *J Low Genit Tract Dis.* 2012;16(4):377-380. doi:10.1097/LGT.0b013e318247a907
5. Murrell DF, Marinovic B, Caux F, et al. Definitions and outcome measures for mucous membrane pemphigoid: Recommendations of an international panel of experts. *J Am Acad Dermatol.* 2015;72(1):168-174. doi:10.1016/j.jaad.2014.08.024
6. Elston DM, Stratman EJ, Miller SJ. Skin biopsy. *J Am Acad Dermatol.* 2016;74(1):1-16. doi:10.1016/j.jaad.2015.06.033
7. Day T, Wilkinson E, Rowan D, Scurry J. Clinicopathologic Diagnostic Criteria for Vulvar Lichen Planus. *J Low Genit Tract Dis.* 2020;24(3):317-329. doi:10.1097/LGT.0000000000000532
8. Mauskar M. Erosive Lichen Planus. *Obstet Gynecol Clin North Am.* 2017;44(3):407-420. doi:10.1016/j.ogc.2017.04.004
9. Chew A, Stefanato CM, Savarese I, Neill SM, Fenton DA, Lewis FM. Clinical patterns of lichen planopilaris in patients with vulval lichen planus. *Br J Dermatol.* 2014;170(1):218-220. doi:10.1111/bjd.12609
10. Day T, Moore S, Bohl TG, Scurry J. Comorbid Vulvar Lichen Planus and Lichen Sclerosus. *J Low Genit Tract Dis.* 2017;21(3):204-208. doi:10.1097/LGT.0000000000000307
11. Preston M, Richards A. Vulvar and Vaginal Graft Versus Host Disease After Allogeneic Stem Cell Transplant—A Systematic Review. *J Low Genit Tract Dis.* 2023;27(3):266-274. doi:10.1097/LGT.0000000000000738
12. Smith Knutsson E, Björk Y, Broman AK, et al. A prospective study of female genital chronic graft-versus-host disease symptoms, signs, diagnosis and treatment. *Acta Obstet Gynecol Scand.* 2018;97(9):1122-1129. doi:10.1111/aogs.13366
13. Kornik RI, Rustagi AS. Vulvovaginal Graft-Versus-Host Disease. *Obstet Gynecol Clin North Am.* 2017;44(3):475-492. doi:10.1016/j.ogc.2017.05.007
14. Binns HM, Tasker F, Lewis FM. Drug eruptions and the vulva. *Clin Exp Dermatol.* Published online October 31, 2023;1lad369. doi:10.1093/ced/1lad369
15. Fischer G. Vulvar fixed drug eruption. A report of 13 cases. *J Reprod Med.* 2007;52(2):81-86.
16. Kreuter A, Wischnewski J, Terras S, Altmeyer P, Stücker M, Gambichler T. Coexistence of lichen sclerosus and morphea: A retrospective analysis of 472 patients with localized scleroderma from a German tertiary referral center. *J Am Acad Dermatol.* 2012;67(6):1157-1162. doi:10.1016/j.jaad.2012.04.003
17. Prasad S, Black SM, Zhu JL, Sharma S, Jacobe H. Morphea patients with mucocutaneous involvement: A cross-sectional study from the Morphea in Adults and Children (MAC) cohort. *J Am Acad Dermatol.* 2021;85(1):114-120. doi:10.1016/j.jaad.2020.10.093
18. Lynch PJ. Lichen simplex chronicus (atopic/neurodermatitis) of the anogenital region. *Dermatol Ther.* 2004;17(1):8-19. doi:10.1111/j.1396-0296.2004.04002.x
19. Zhao CY, Wijayanti A, Doria MC, et al. The reliability and validity of outcome measures for atopic dermatitis in patients with pigmented skin: A grey area. *Int J Womens Dermatol.* 2015;1(3):150-154. doi:10.1016/j.ijwd.2015.05.002
20. White disorders. In: *Genital Dermatology Atlas.* Lippincott Williams & Wilkins; 2010:165-191.
21. Peterson MY, Warshaw E. Going Green and Adhesive-Free: Snap-in Reusable Menstrual Pads for Tampon and Pad Intolerance. *Dermatitis®.* 2023;34(1):60-61. doi:10.1089/DERM.0000000000000898
22. Aschenbeck KA, Warshaw EM. Allergenic Ingredients in Personal Hygiene Wet Wipes. *Dermatitis.* 2017;28(5):317-322. doi:10.1097/DER.0000000000000275

23. Luu Y, Admani S. Vulvar allergens in topical preparations recommended on social media: a cross-sectional analysis of Facebook groups for lichen sclerosus. *Int J Women's Dermatol.* 2023;9(3):e097. doi:10.1097/JW9.0000000000000097
24. Newton J, Richardson S, Van Oosbre AM, Yu J, Silence C. A cross-sectional study of contact allergens in feminine hygiene wipes: a possible cause of vulvar contact dermatitis. *Int J Women's Dermatol.* 2022;8(4):e060. doi:10.1097/JW9.0000000000000060
25. Vandeweege S, Debaene B, Lapeere H, Verstraelen H. A systematic review of allergic and irritant contact dermatitis of the vulva: The most important allergens/irritants and the role of patch testing. *Contact Dermatitis.* 2023;88(4):249-262. doi:10.1111/cod.14258
26. Bauer A, Rödiger C, Greif C, Kaatz M, Elsner P. Vulvar Dermatoses – Irritant and Allergic Contact Dermatitis of the Vulva. *Dermatology.* 2005;210(2):143-149. doi:10.1159/000082570
27. Woodruff CM, Trivedi MK, Botto N, Kornik R. Allergic Contact Dermatitis of the Vulva. *Dermat Contact Atopic Occup Drug.* 2018;29(5):233-243. doi:10.1097/DER.0000000000000339
28. Day T, Burston K, Dennerstein G, Pagano R, Scurry J. Vestibulovaginal Sclerosis Versus Lichen Sclerosus. *Int J Gynecol Pathol.* 2018;37(4):356. doi:10.1097/PGP.0000000000000041
29. Croker BA, Scurry JP, Petry FM, Fischer G. Vestibular Sclerosis: Is This a New, Distinct Clinicopathological Entity? *J Low Genit Tract Dis.* 2018;22(3):260-263. doi:10.1097/LGT.0000000000000404
30. Fadare O. Vaginal Stromal Sclerosis: A Distinctive Stromal Change Associated With Vaginal Atrophy. *Int J Gynecol Pathol.* 2011;33(3):295-300. doi:10.1097/PGP.0b013e3182005356
31. Klatte JL, Van Der Beek N, Kemperman PMJH. 100 years of Wood's lamp revised. *J Eur Acad Dermatol Venereol.* 2015;29(5):842-847. doi:10.1111/jdv.12860
32. Veronesi G, Virdi A, Leuzzi M, et al. Vulvar vitiligo and lichen sclerosus in children: A clinical challenge. *Pediatr Dermatol.* 2021;38(5):1012-1019. doi:10.1111/pde.14771
33. Esse I, Rodriguez KH, Kassels A, Shiu J, Kraus CN. Vulvar lichen sclerosus and vitiligo: Overlap and clinical features. *J Am Acad Dermatol.* 2023;89(4):839-841. doi:10.1016/j.jaad.2023.06.016
34. Park YJ, Lee H, Park HS, Kim YC. Histopathological differences between vitiligo and lichen sclerosus et atrophicus using quantitative immunohistochemical analysis. *Front Med.* 2023;10:1205909. doi:10.3389/fmed.2023.1205909
35. Fan R, Leasure AC, Little AJ, Cohen JM. Lichen sclerosus among women with psoriasis: A cross-sectional study in the All of Us research program. *J Am Acad Dermatol.* 2023;88(5):1175-1177. doi:10.1016/j.jaad.2022.12.012
36. Wu M, Fischer G. Adult genital psoriasis: An updated review for clinicians. *Australas J Dermatol.* 2024;65(3):e1-e12. doi:10.1111/ajd.14227
37. Edwards L. Pigmented vulvar lesions. *Dermatol Ther.* 2010;23(5):449-457. doi:10.1111/j.1529-8019.2010.01349.x
38. Murzaku EC, Penn LA, Hale CS, Pomeranz MK, Polsky D. Vulvar nevi, melanosis, and melanoma: an epidemiologic, clinical, and histopathologic review. *J Am Acad Dermatol.* 2014;71(6):1241-1249. doi:10.1016/j.jaad.2014.08.019
39. El Shabrawi-Caelen L, Soyer HP, Schaeppi H, et al. Genital lentiginos and melanocytic nevi with superimposed lichen sclerosus: a diagnostic challenge. *J Am Acad Dermatol.* 2004;50(5):690-694. doi:10.1016/j.jaad.2003.09.034
40. De Giorgi V, Gori A, Salvati L, et al. Clinical and Dermoscopic Features of Vulvar Melanosis Over the Last 20 Years. *JAMA Dermatol.* 2020;156(11):1185. doi:10.1001/jamadermatol.2020.2528
41. Moran JM, Hartsough EM, Hoang MP. Vulvovaginal melanocytic lesions: a review. *Diagn Histopathol.* 2024;30(1):15-24. doi:10.1016/j.mpdhp.2023.10.003
42. Gleason BC, Hirsch MS, Nucci MR, et al. Atypical Genital Nevi: A Clinicopathologic Analysis of 56 Cases. *Am J Surg Pathol.* 2008;32(1):51-57. doi:10.1097/PAS.0b013e318068420c
43. Wohlmut C, Wohlmut-Wieser I. Vulvar Melanoma: Molecular Characteristics, Diagnosis, Surgical Management, and Medical Treatment. *Am J Clin Dermatol.* 2021;22(5):639-651. doi:10.1007/s40257-021-00614-7
44. Wechter ME, Gruber SB, Haefner HK, et al. Vulvar melanoma: a report of 20 cases and review of the literature. *J Am Acad Dermatol.* 2004;50(4):554-562. doi:10.1016/j.jaad.2003.07.026
45. Ragnarsson-Ölding BK, Kanter-Lewensohn LR, Lagerlöf B, Nilsson BR, Ringborg UK. Malignant melanoma of the vulva in a nationwide, 25-year study of 219 Swedish females: Clinical observations and histopathologic features. *Cancer.* 1999;86(7):1273-1284. doi:10.1002/(SICI)1097-0142(19991001)86:7<1273::AID-CNCR24>3.0.CO;2-Z
46. Sim SJY, Dear K, Mastoraki E, et al. Genital lichen sclerosus and melanoma; a systematic review. *Skin Health Dis.* 2023;3(2):e198. doi:10.1002/ski2.198
47. Morrel B, van der Avoort IAM, Damman J, Mooyaart AL, Pasmans SGMA. A Scoping Review and Population Study Regarding Prevalence and Histopathology of Juvenile Vulvar Melanocytic Lesions. A Recommendation. *JID Innov Skin Sci Mol Popul Health.* 2022;2(5):100140. doi:10.1016/j.xjidi.2022.100140
48. Morrel B, Pasmans SGMA, Mooyaart AL, van der Avoort IAM. Tread carefully when considering vulvar melanoma in a child or adolescent. *Skin Health Dis.* 2023;3(4):e233. doi:10.1002/ski2.233

49. Sobel JD. Recurrent vulvovaginal candidiasis. *Am J Obstet Gynecol.* 2016;214(1):15-21. doi:10.1016/j.jajog.2015.06.067
50. Denning DW, Kneale M, Sobel JD, Rautemaa-Richardson R. Global burden of recurrent vulvovaginal candidiasis: a systematic review. *Lancet Infect Dis.* 2018;18(11):e339-e347. doi:10.1016/S1473-3099(18)30103-8
51. Farr A, Effendy I, Frey Tirri B, et al. Guideline: Vulvovaginal candidosis (AWMF 015/072, level S2k). *Mycoses.* 2021;64(6):583-602. doi:10.1111/myc.13248
52. Mendling W. Guideline: Vulvovaginal Candidosis (AWMF 015/072), S2k (excluding chronic mucocutaneous candidosis). *Mycoses.* 2015;58(S1):1-15. doi:10.1111/myc.12292
53. Fischer G. Chronic vulvovaginal candidiasis: What we know and what we have yet to learn. *Australas J Dermatol.* 2012;53(4):247-254. doi:10.1111/j.1440-0960.2011.00860.x
54. Day T, Chapman-Burgess E, Scurry J. Clinicopathologic Overlap of Vulvar Psoriasis and Candidiasis. *J Low Genit Tract Dis.* 2024;28(2):175-182. doi:10.1097/LGT.0000000000000801
55. Taudorf EH, Jemec GBE, Hay RJ, Saunte DML. Cutaneous candidiasis – an evidence-based review of topical and systemic treatments to inform clinical practice. *J Eur Acad Dermatol Venereol.* 2019;33(10):1863-1873. doi:10.1111/jdv.15782
56. Day T, Borbolla Foster A, Phillips S, et al. Can Routine Histopathology Distinguish Between Vulvar Cutaneous Candidosis and Dermatophytosis? *J Low Genit Tract Dis.* 2016;20(3):267-271. doi:10.1097/LGT.0000000000000208
57. Saunte DM, Mrowietz U, Puig L, Zachariae C. Candida infections in patients with psoriasis and psoriatic arthritis treated with interleukin-17 inhibitors and their practical management. *Br J Dermatol.* 2017;177(1):47-62. doi:10.1111/bjd.15015
58. Forman JL, Mercurio MG. Vulvar Pruritus in Postmenopausal Diabetic Women With Candidiasis Secondary to Sodium-Glucose Cotransporter Receptor-2 Inhibitors. *J Low Genit Tract Dis.* 2023;27(1):68-70. doi:10.1097/LGT.0000000000000704
59. Mounsey SJ, Teo YX, Calonje JE, Lewis FM. Gliflozin (SGLT2 inhibitor) induced vulvitis. *Int J Dermatol.* 2023;62(1):62-65. doi:10.1111/ijd.16449
60. Crouss T, Sobel JD, Smith K, Nyirjesy P. Long-Term Outcomes of Women With Recurrent Vulvovaginal Candidiasis After a Course of Maintenance Antifungal Therapy. *J Low Genit Tract Dis.* 2018;22(4):382-386. doi:10.1097/LGT.0000000000000413
61. Schaller M, Friedrich M, Papini M, Pujol RM, Veraldi S. Topical antifungal-corticosteroid combination therapy for the treatment of superficial mycoses: conclusions of an expert panel meeting. *Mycoses.* 2016;59(6):365-373. doi:10.1111/myc.12481
62. El-Gohary M, Van Zuuren EJ, Fedorowicz Z, et al. Topical antifungal treatments for tinea cruris and tinea corporis. *Cochrane Skin Group, ed. Cochrane Database Syst Rev.* 2014;2014(8). doi:10.1002/14651858.CD009992.pub2
63. Labadie JG, Guggina LM. Vulvar Majocchi granuloma and kerion formation in an immunocompetent female. *Dermatol Online J.* 2019;25(9):13030/qt4qv91478.
64. Pastore LM, Introcaso CE. Zoonotic Majocchi's Granuloma of the Vulva. *Skinmed.* 2024;22(1):67-68.
65. Luchsinger I, Bossardt PP, Kasper RS, Reinhardt D, Lautenschlager S. Tinea genitalis: a new entity of sexually transmitted infection? Case series and review of the literature. *Sex Transm Infect.* 2015;91(7):493-496. doi:10.1136/sextrans-2015-052036
66. Zacharopoulou A, Tsiogka A, Tsimpidakis A, Lamia A, Koumaki D, Gregoriou S. Tinea Incognita: Challenges in Diagnosis and Management. *J Clin Med.* 2024;13(11):3267. doi:10.3390/jcm13113267
67. Trager JDK. What's Your Diagnosis? Nine-year-old Girl with a Pubic Rash Gone Incognito. *J Pediatr Adolesc Gynecol.* 2006;19(4):307-312. doi:10.1016/j.jpjag.2006.05.015
68. Al-Amiri A, Chatrath V, Bhawan J, Stefanato CM. The periodic acid-Schiff stain in diagnosing tinea: should it be used routinely in inflammatory skin diseases? *J Cutan Pathol.* 2003;30(10):611-615. doi:10.1034/j.1600-0560.2003.00111.x
69. Guarner J, Brandt ME. Histopathologic diagnosis of fungal infections in the 21st century. *Clin Microbiol Rev.* 2011;24(2):247-280. doi:10.1128/CMR.00053-10
70. Mohan H, Bal A, Aulakh R. Evaluation of skin biopsies for fungal infections: role of routine fungal staining. *J Cutan Pathol.* 2008;35(12):1097-1099. doi:10.1111/j.1600-0560.2007.00978.x
71. Gnann JW, Whitley RJ. Genital Herpes. Solomon CG, ed. *N Engl J Med.* 2016;375(7):666-674. doi:10.1056/NEJMcp1603178
72. James C, Harfouche M, Welton NJ, et al. Herpes simplex virus: global infection prevalence and incidence estimates, 2016. *Bull World Health Organ.* 2020;98(5):315-329. doi:10.2471/BLT.19.237149
73. Dabestani N, Katz DA, Dombrowski J, Magaret A, Wald A, Johnston C. Time Trends in First-Episode Genital Herpes Simplex Virus Infections in an Urban Sexually Transmitted Disease Clinic. *Sex Transm Dis.* 2019;46(12):795-800. doi:10.1097/OLQ.0000000000001076



74. Bernstein DI, Bellamy AR, Hook EW, et al. Epidemiology, Clinical Presentation, and Antibody Response to Primary Infection With Herpes Simplex Virus Type 1 and Type 2 in Young Women. *Clin Infect Dis*. 2013;56(3):344-351. doi:10.1093/cid/cis891
75. Hu J, Krauss JC, Moyal-Barracco M, Washer LL, Haefner HK, Parker-Featherstone E. Vulvar pseudotumoral acyclovir-resistant herpes in an HIV-negative, non-immunosuppressed patient: A therapeutic challenge. *Int J Womens Dermatol*. 2021;7(5):731-736. doi:10.1016/j.ijwd.2021.06.002
76. Chan MP. Verruciform and Condyloma-like Squamous Proliferations in the Anogenital Region. *Arch Pathol Lab Med*. 2019;143(7):821-831. doi:10.5858/arpa.2018-0039-RA
77. Unruh KR, Lai DD. Anal Condyloma and Human Papillomavirus: Recognition, Treatment, and Prevention. *Dis Colon Rectum*. 2024;67(4):491-494. doi:10.1097/DCR.0000000000003247
78. Sand FL, Thomsen SF. Skin diseases of the vulva: Infectious diseases. *J Obstet Gynaecol J Inst Obstet Gynaecol*. 2017;37(7):840-848. doi:10.1080/01443615.2017.1306696
79. Cymerman RM, Kaplan Hoffmann R, Rouhani Schaffer P, Pomeranz MK. Vulvar infections: beyond sexually transmitted infections. *Int J Dermatol*. 2017;56(4):361-369. doi:10.1111/ijd.13464
80. Muzny CA, Cerca N, Elnaggar JH, Taylor CM, Sobel JD, Van Der Pol B. State of the Art for Diagnosis of Bacterial Vaginosis. Humphries RM, ed. *J Clin Microbiol*. Published online May 18, 2023:e00837-22. doi:10.1128/jcm.00837-22
81. Paavonen J, Brunham RC. Bacterial Vaginosis and Desquamative Inflammatory Vaginitis. Longo DL, ed. *N Engl J Med*. 2018;379(23):2246-2254. doi:10.1056/NEJMra1808418
82. Muzny CA, Sobel JD. The Role of Antimicrobial Resistance in Refractory and Recurrent Bacterial Vaginosis and Current Recommendations for Treatment. *Antibiotics*. 2022;11(4):500. doi:10.3390/antibiotics11040500
83. Song M, Day T, Kliman L, et al. Desquamative Inflammatory Vaginitis and Plasma Cell Vulvitis Represent a Spectrum of Hemorrhagic Vestibulovaginitis. *J Low Genit Tract Dis*. 2022;26(1):60-67. doi:10.1097/LGT.0000000000000637
84. Van Der Meijden WJ, Ewing PC. Papular Colpitis: A Distinct Clinical Entity?: Symptoms, Signs, Histopathological Diagnosis, and Treatment in a Series of Patients Seen at the Rotterdam Vulvar Clinic. *J Low Genit Tract Dis*. 2011;15(1):60-65. doi:10.1097/LGT.0b013e3181dc2f6a
85. Bradford J, Fischer G. Desquamative Inflammatory Vaginitis: Differential Diagnosis and Alternate Diagnostic Criteria. *J Low Genit Tract Dis*. 2010;14(4):306-310. doi:10.1097/LGT.0b013e3181d737d0
86. Sobel JD, Reichman O, Misra D, Yoo W. Prognosis and Treatment of Desquamative Inflammatory Vaginitis. *Obstet Gynecol*. 2011;117(4):850-855. doi:10.1097/AOG.0b013e3182117c9e
87. Yıldız Ş, Cengiz H, Kaya C, et al. Evaluation of genital self-image and sexual dysfunction in women with vulvar lichen planus or lichen sclerosus. *J Psychosom Obstet Gynecol*. 2022;43(2):99-106. doi:10.1080/0167482X.2020.1857359
88. Hodges KR, Wiener CE, Vyas AS, Turrentine MA. The Female Genital Self-image Scale in Adult Women With Vulvar Lichen Sclerosus. *J Low Genit Tract Dis*. 2019;23(3):210-213. doi:10.1097/LGT.0000000000000481
89. Caspersen IS, Højgaard A, Laursen BS. The influence of lichen sclerosus on women's sexual health from a biopsychosocial perspective: a mixed methods study. *J Sex Med*. 2023;20(4):488-497. doi:10.1093/jsxmed/qdad018
90. Vittrup G, Mørup L, Heilesen T, Jensen D, Westmark S, Melgaard D. Quality of life and sexuality in women with lichen sclerosus: a cross-sectional study. *Clin Exp Dermatol*. 2022;47(2):343-350. doi:10.1111/ced.14893
91. Jabłonowska O, Woźniacka A, Szkarłat S, Żebrowska A. Female genital lichen sclerosus is connected with a higher depression rate, decreased sexual quality of life and diminished work productivity. Favilli A, ed. *PLOS ONE*. 2023;18(4):e0284948. doi:10.1371/journal.pone.0284948
92. Pope R, Lee MH, Myers A, et al. Lichen Sclerosus and Sexual Dysfunction: A Systematic Review and Meta-Analysis. *J Sex Med*. 2022;19(11):1616-1624. doi:10.1016/j.jsxm.2022.07.011
93. Vittrup G, Westmark S, Riis J, et al. The Impact of Psychosexual Counseling in Women With Lichen Sclerosus: A Randomized Controlled Trial. *J Low Genit Tract Dis*. 2022;26(3):258-264. doi:10.1097/LGT.0000000000000669
94. Fan R, Leasure AC, Maisha FI, Little AJ, Cohen JM. Depression and Anxiety in Patients With Lichen Sclerosus. *JAMA Dermatol*. 2022;158(8):953. doi:10.1001/jamadermatol.2022.1964
95. Ranum A, Pearson DR. The impact of genital lichen sclerosus and lichen planus on quality of life: A review. *Int J Women's Dermatol*. 2022;8(3):e042. doi:10.1097/JW9.0000000000000042
96. Chang HR, Ngo M, Jain S, Mauskar MM. Suicidal ideation in patients with vulvar lichen sclerosus. *Int J Women's Dermatol*. 2024;10(3):e164. doi:10.1097/JW9.0000000000000164
97. Preti M, Joura E, Vieira-Baptista P, et al. The European Society of Gynaecological Oncology (ESGO), the International Society for the Study of Vulvovaginal Disease (ISSVD), the European College for the Study of Vulval Disease (ECSVD) and the European Federation for Colposcopy (EFC) consensus statements on pre-invasive vulvar lesions. *Int J Gynecol Cancer*. 2022;32(7):830-845. doi:10.1136/ijgc-2021-003262



98. Delport ES. Extramammary Paget's disease of the vulva: An annotated review of the current literature. *Australas J Dermatol.* 2013;54(1):9-21. doi:10.1111/j.1440-0960.2012.00898.x
99. Caruso G, Barcellini A, Mazzeo R, et al. Vulvar Paget's Disease: A Systematic Review of the MITO Rare Cancer Group. *Cancers.* 2023;15(6):1803. doi:10.3390/cancers15061803
100. Clemente N, Ciavattini A, Valenti G, et al. Extramammary Paget's Disease of the Vulva and Concomitant Premalignant/Malignant Vulvar Lesions: A Potential Challenge in Diagnosis and Treatment. *Curr Oncol.* 2023;30(1):959-966. doi:10.3390/curroncol30010073

# Treatment with topical corticosteroids

*Pedro Vieira-Baptista, Sydney Rivera Dixon, Carly Kirshen, Annarosa Virgili, Michelle Murphy*

Lichen sclerosus (LS) is a chronic and incurable but treatable condition. Topical corticosteroids are safe, effective, and the mainstay of both initial treatment and long-term maintenance therapy. Clear, empathetic, and consistent counseling is required to communicate the natural history of LS and need for a lifelong management plan. Women must be informed the symptoms of vulvar LS range from none to severe and may not correlate with disease activity, progressive architectural change, or the risk of cancer.<sup>1</sup> As a result, symptom control is not a reliable indicator of treatment adequacy; rather, examination by an experienced clinician establishes if disease is optimally controlled. Lifelong maintenance therapy of LS with topical steroids is almost always necessary, even when the condition is asymptomatic.

The goals of LS treatment with topical steroids include:

1. attaining symptom relief in those who are symptomatic and improving quality of life (QoL),
2. objectively controlling disease,
3. preventing progressive anatomical alteration, and
4. reducing the risk of human papillomavirus-independent vulvar intraepithelial neoplasia (HPV-I VIN) and squamous cell cancer (SCC).

## Goals of treatment and assessment of treatment outcome

### Symptom relief and improved QoL

Remission of symptoms occurs in 36-96% of patients, with variation across studies likely explained by different steroid regimens and varied medical complexities of each cohort.<sup>2-5</sup> Key messages for patients are that cessation of symptoms is not synonymous with cure and women with LS require lifelong topical steroid maintenance therapy and regular follow-up for vulvar examinations.<sup>2,5</sup> Symptoms usually improve within 12 weeks of adequate application of topical corticosteroids.<sup>6</sup> Use of topical steroids as prescribed leads to a higher likelihood of symptom improvement compared to infrequent use, with an odds ratio of 4.6 when compared to no use.<sup>7</sup>

Topical steroid treatment of LS improves QoL in 93% of respondents completing the Vulvar Quality of Life Index (VQLI).<sup>8</sup> Residual poor QoL was associated with urinary incontinence,

rather than LS, in this cohort.<sup>8</sup> Quality of life improvement is greatest in women with symptom resolution, compared to those with partial relief.<sup>5</sup> Treatment of LS has also been associated with a reduction in depression and anxiety with relative risks of 0.6 and 0.72 respectively.<sup>4</sup>

## Objective control of disease

Examination findings that reflect disease activity may broadly be categorized into color and texture changes (see Chapter 3). Complete remission of white color change and abnormal texture occurs in more than 20-25% of women on topical corticosteroid treatment.<sup>4,5</sup> Topical steroid use is associated with higher rates of objective improvement compared to non-use, with an odds ratio of 6.9 for ideal and 4.2 for imperfect use.<sup>7</sup> Among 16 women using clobetasol propionate, 81% had histologic improvement at 12 weeks.<sup>9</sup> Expert management of LS using an individualized topical steroid regimen results in a non-response rate of less than 2% in women adhering to treatment recommendations.<sup>2</sup>

## Prevention of progressive anatomical alteration

Vulvar architectural change due to undercontrolled LS may lead to negative health impacts to include sexual difficulties, urinary stream change or obstruction, poor genital self-image, and reduced QoL.<sup>10-12</sup> In untreated disease, progression may occur even in the absence of symptoms.<sup>13</sup> In children, delay in diagnosis and treatment may result in irreversible architectural change prior to puberty, while effective treatment is associated with a lower risk of vulvar structural abnormalities persisting beyond menarche (see Chapter 13).<sup>14,15</sup>

## Risk reduction of HPV-independent neoplasia

The true risk of HPV-I VIN and SCC arising in LS is unknown and may have previously been overestimated due to inadequate delineation of cancer etiology and misdiagnosis of precursor lesions.<sup>16</sup> An emerging body of evidence suggests treatment with topical corticosteroids and ongoing surveillance reduces the risk of cancer to <1%.<sup>16</sup> To date, no other intervention for LS has a demonstrated effect on vulvar SCC rates.

After treatment of HPV-I VIN or SCC, ongoing topical steroid management of LS is recommended (see Chapter 11). A small series showed half the expected recurrence risk in women treated with steroids after vulvar cancer excision.<sup>17</sup> Nevertheless, gynecologic oncologists often do not prescribe topical steroids to asymptomatic women after excision of LS-related cancers.<sup>18,19</sup> This highlights the potential benefit of ongoing input from a vulvar specialist regarding effective control of LS after treatment of HPV-I neoplasia.

## Primer on use of topical corticosteroids

Topical steroid formulations of similar potency likely have comparable therapeutic outcomes.<sup>20,21</sup> Most topical steroids were created by modifying a hydrocortisone base molecule; adding various hydroxyl groups, double bonds, and ketone groups on this base molecule changes the pharmacokinetics, penetration, and lipophilicity of the active ingredient to create new drugs.<sup>22</sup>

**TABLE 1 Topical corticosteroids**

Potency*	Generic	Vehicle^	Allergy Group
Super potent Ultra potent Ultra high	Augmented betamethasone dipropionate 0.05%	G, O	3
	Clobetasol propionate 0.05%	O, C, L, G, F, S	3
	Halobetasol propionate 0.05%	C, O, L, F	3
High potency	Augmented betamethasone dipropionate 0.05%	L, C	3
	Betamethasone dipropionate 0.05%	O	3
	Desoximetasone	C, O (0.25%); G (0.05%)	3
	Fluocinonide 0.05%	C, G, O, S	2
	Mometasone furoate 0.1%	O	2
Medium to high potency	Triamcinolone acetonide	O (0.1%); C (0.5%)	2
	Betamethasone valerate 0.1%	C, L	3
	Fluticasone propionate 0.005%	O	3
Medium potency	Desoximetasone 0.05%	C	3
	Fluocinolone acetonide 0.025%	C, O	2
	Mometasone furoate 0.1%	C, L	2
	Triamcinolone acetonide 0.025%	O	2
Low to lowest potency	Methylprednisolone aceponate 0.1% Desonide 0.05%	O, C C, G, O, L, F	2
	Hydrocortisone 1%, 2.5%	C, L, O	1

\*Steroid class systems vary globally. In U.S. systems, Class I is most potent, while Class VII is least. In the WHO's Anatomical Therapeutic Classification, potency ranges from Class I, least potent, to Class IV, most potent. Classes are thus omitted in the above table in preference of descriptive terms to avoid confusion.<sup>29</sup>

^Abbreviations: ointment (O), cream (C), solution (S), lotion (L), gel (G), and foam (F)

The drug vehicle influences the penetration, stability, and release of a given medication, modulating its potency. Ointments offer better skin penetration, improved barrier function, reduced allergenicity, and better control of LS compared to creams.<sup>20,23,24</sup> Creams have an increased potential for contact dermatitis as they contain more excipients, or 'inert' pharmaceutical ingredients, than ointments. The degree of active ingredient penetration through skin depends on a complex interplay of factors. Propylene glycol and ethanol may be added to a vehicle to increase the percutaneous absorption and thereby increase potency.<sup>25</sup> Patient perception of different vehicles is variable, with a minority describing ointments as greasy, sticky, or prone to staining their underwear.<sup>26</sup> In contrast, creams are more likely to provoke a burning sensation on application. In general, ointments are preferable over creams for vulvar skin conditions.

One fingertip length is approximately 0.5g (see Fig 1). A lentil-sized amount, about a quarter fingertip unit, is required to cover hairless skin and non-keratinized squamous epithelium of the vestibule (see Fig 2). It is acceptable to simultaneously apply vaginal and vestibular estrogen cream. An additional pea-sized amount, approximately  $\frac{1}{3}$  fingertip unit, is needed to cover hair bearing skin of the labia majora and perianus (Fig 3).

Allergies to topical corticosteroids are rare but may be subtle given the background anti-inflammatory medication effect. If skin appearance worsens with exposure to steroid ointments and no other explanation is identified, the differential diagnosis includes steroid allergy. The allergenicity of topical corticosteroids is classified into Groups 1, 2, and 3, based on chemical structure: Group 1 is the most allergenic due to being mostly non-halogenated while Group 3 is rarely implicated in allergy.<sup>27</sup> As multiple agents may cross-react, patch testing should occur with the current and proposed future medication, rather than with a generic panel.<sup>28</sup> Agents used for patch testing topical steroids include tixocortol-21-pivalate and hydrocortisone-17-butyrate for Group 1, budesonide for Group 1 with Group 2 cross-reactivity, with triamcinolone acetonide and clobetasol propionate representing Groups 2 and 3, respectively.<sup>29</sup> Late readings at a 7-day interval may improve sensitiv-

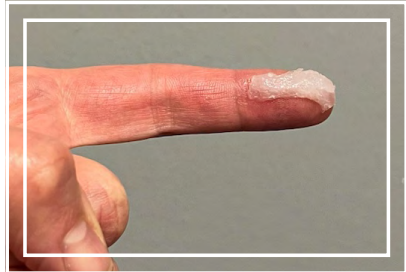

FIGURE 1. One fingertip length, or 0.5g of steroid ointment. This is far more than required to cover vulvar skin.

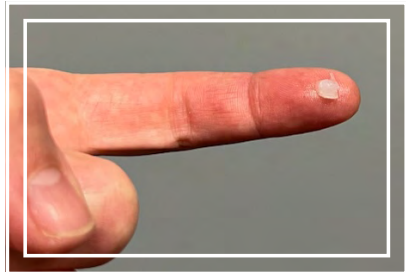

FIGURE 2. A quarter of a fingertip unit, or a lentil-sized amount, covers hairless skin and non-keratinized squamous epithelium of the periclitoral structures, labia minora, and vestibule.

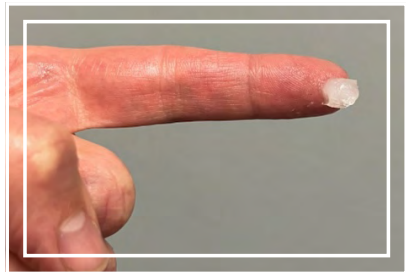

FIGURE 3. A third of a fingertip unit, or a pea-sized amount, covers hair bearing skin of labia majora, perineum, and perianus.

ity. If patch testing is not feasible, the alternative is a repeat open application test during which patients apply the selected agent twice daily to uninvolved skin of the ventral forearm for one week and assess for reaction.

Patients with LS often have steroid-dependent dermatoses at other sites and require simultaneous site-specific use of different vehicles and/or drugs. Cream vehicles are easier to use for vaginal application as they deploy and distribute more readily from applicators. Commercial steroid formulations may be introduced via placement on a dilator or tampon and applicators are now widely available for the public to purchase online. Oils, solutions, or foams may be used for scalp or hair bearing skin. Ointment or gel may be used for oral lesions; halobetasol is particularly effective for oral lichen planus (LP). Due to the varied drug delivery requirements, it is often infeasible to streamline regimens to a single product. In this case, written directions and verbal reinforcement mitigate confusion regarding where to apply which product.

Availability and cost of different steroid formulations varies by country. Table 1 lists commonly used topical steroids and their vehicles: ointments (O), creams (C), solutions (S), lotions (L), gels (G), and foams (F).

## Data supporting topical steroids as the mainstay of lichen sclerosis treatment

Multiple randomized controlled trials (RCT) have compared topical steroids to other medical therapies, with results uniformly favoring steroids. In 1992, clobetasol propionate was shown to be more effective than topical testosterone in symptom control, objective findings, and histology, with fewer adverse effects.<sup>30</sup> A 2011 RCT of clobetasol versus pimecrolimus showed similar symptom relief in both groups but inflammation was only reduced with clobetasol.<sup>31</sup> Clobetasol was likewise found superior to tacrolimus in a 2014 RCT.<sup>32</sup> In 2022, a RCT of 37 women biopsy-proven LS comparing clobetasol with 8% progesterone ointment again found clobetasol more effective.<sup>9</sup> A network meta-analysis of treatments performed by researchers without specific LS expertise highlighted heterogeneity in study populations, regimens, and outcomes, and insufficient direct comparisons between topical steroids and calcineurin inhibitors; however, clobetasol appeared to perform better than any other topical therapy assessed by RCT.<sup>20</sup>

Investigators have explored an array of alternatives to topical corticosteroids for LS, including topical and oral retinoids, systemic immunosuppressants, biologics, photodynamic therapy, high-intensity focused ultrasound, platelet-rich plasma injection, and laser (see Chapter 10). Methodologies range from case series, to cohorts using patients as their own controls, to placebo-controlled RCT. None of these studies provide evidence for replacement of topical corticosteroids as the fundamental treatment approach for LS.

## Initial treatment

A variety of approaches to initial management of LS have been described and assessed, with no strategy identified as superior to another. Investigators have used topical steroids of varying potencies, frequencies, and durations and demonstrated improvement in symptoms and clinical signs. The regimentation of steroid protocols in clinical trials represents

a research-centered rather than a patient-centered approach to care.<sup>26</sup> Didactic adherence to the provision of a single drug type and frequency stands in contradiction to the reality of individual variation in LS extent and severity. Thus, selection of initial treatment may be guided by local availability and cost of various products, clinician experience, disease activity, and patient preferences that may improve tolerability and adherence.

Historically, a common initial treatment regimen for LS was clobetasol propionate 0.05% ointment used in a 12 week tapering regimen of daily for 1 month, alternate days for 1 month, then twice weekly for 1 month.<sup>23</sup> Arising out of this traditional approach, most clinical trials have used clobetasol propionate ointment 0.05% and/or mometasone furoate ointment 0.1% in a reducing regimen as initial treatment.<sup>9,31–36</sup> Prospective and retrospective direct comparison between these two steroids showed no differences in safety, efficacy, or tolerability using 8-12 week tapering regimens.<sup>33,37</sup> The 12-week timeframe is arbitrary, evidenced by a similar outcomes after 12 versus 24 weeks of mometasone ointment 5 days per week; however, with this regimen only 50% of participants had resolution of symptoms and 16% of signs, regardless of duration.<sup>6</sup> This finding may signal insufficient steroid potency and/or frequency to achieve disease control for many women in this cohort. Characteristics associated with persistent symptoms and signs include greater symptom intensity at treatment initiation, more severe features, older age, and longer-standing disease.<sup>5</sup>

The widespread concept of a tapering regimen has not been established as superior to other patterns of steroid use. Its popularity may arise from a perception that tapering mitigates risks of tachyphylaxis and dose-dependent side-effects. A 12-week RCT assessing mometasone application 5 days per week versus a tapering regimen of one month each of 5 days/week, then alternating days, then twice a week, showed no statistical difference between these approaches but a trend towards higher rates of improvement in the continuous group.<sup>38</sup> Multiple studies of clobetasol and/or mometasone tapering regimens cite response rates of 60-80%, with higher rates of improvement in symptoms than signs.<sup>4,33,37,39</sup>

Cohort studies elaborate a treatment approach in which drug potency and/or frequency is determined by clinician assessment of abnormal texture as a manifestation of disease severity. In this care model, the authors used the term 'hyperkeratosis' and categorized it as absent in inactive LS, 1+ hyperkeratosis as mild LS, 2+ as moderate, 3+ as severe, and 4+ as very severe.<sup>21</sup> Treatment of inactive or mild LS was with hydrocortisone acetate 1% or methylprednisolone acetate 0.1% ointment daily. Patients with moderate to severe LS received betamethasone dipropionate 0.05% ointment either daily or twice daily respectively, while very severe LS was managed with clobetasol propionate 0.05% ointment twice daily.<sup>21</sup> Using this individualized scheme, 97% of patient reported symptom resolution within 12 weeks and 86% had normalization of skin texture and color within 6 months.

## Maintenance therapy

Over the past 20 years, the evidence and expert consensus has consolidated around the need for long-term maintenance therapy for LS.<sup>2,40–45</sup> As with initial treatment, multiple approaches to maintenance therapy have been described with studies reporting benefit. It is

recommended that those with LS stay on topical steroids lifelong at the dose and frequency that provides symptom control and improvements in skin color and texture.

A 2013 RCT established that twice weekly mometasone furoate 0.1% ointment was safe as long-term maintenance therapy and more effective than vitamin E cream.<sup>40</sup> In 2016, the same authors demonstrated no significant difference in mometasone versus clobetasol twice weekly for 52 weeks, with 3/48 (5%) experiencing a study-defined relapse while on maintenance.<sup>41</sup> In a prospective cohort using clobetasol propionate 2 or 3 times per week, 54% of participants achieved resolution of signs and symptoms over a mean of 4.7 years. In patients with 'remission', the authors ceased maintenance therapy and found 84% had recurrent active LS within 4 years.<sup>46</sup> There was 1 case each of candidiasis and steroid dermatitis in 83 women. There is no clear clinical foundation for twice weekly dosing; the rationale arises from animal and human studies suggesting persistence of potent topical steroids in skin for 72 hours.<sup>47</sup>

Several cohort studies elaborate a variety of maintenance strategies using methylprednisolone aceponate, triamcinolone, and hydrocortisone acetate ointments.<sup>2,48</sup> One approach involves titration of steroid potency and frequency to each patient's disease severity and evolution over time, with application at least 3 times per week. Patients with severe clinical signs continued super- or high-potency steroids daily, with high rates of ongoing remission and low incidence of adverse effects.<sup>2</sup> Another strategy was long-term triamcinolone ointment once or twice daily titrated to symptoms and signs, with 72% of 41 patients reporting cessation of itch and 92% of pain, but objective results were not reported.<sup>3</sup> In this group, one woman stopped steroids due to exacerbation of a burning sensation, with no other complications noted.

A recent qualitative focus group study found that patients see long-term maintenance therapy as beneficial and a way to minimize the impact of LS on their lives.<sup>26</sup> Women describe a journey of acceptance that involves understanding their diagnosis as chronic, overcoming previous assumptions about genital skin and steroids, and incorporating treatment into their lives as a standard self-care task. Patients identified the importance of autonomy around identifying a routine they can follow while minimizing impacts on work, family commitments, and sex. Ongoing contact with their clinician was an important motivator, allowing women to make the connection between skin appearance and adherence to treatment recommendations. Overall, maintenance therapy was perceived as a necessary inconvenience that produces positive results for their vulvar skin health.

## Adverse effects of topical steroids

Adverse effects from LS treatment are uncommon. Potential complications of steroid overuse include telangiectasia, steroid dermatitis, atrophy, and striae. Steroid dermatitis presents as bright red to purple patches often accompanied by discomfort or burning sensation. In a cohort of 507 women receiving individualized steroid treatment and maintenance, 7 (1.4%) had atrophy and 14 (2.7%) had steroid dermatitis with both conditions responding to a reduction in steroid potency.<sup>2</sup> Among 129 women treated with a similar protocol, 1 (0.7%)



had atrophy and 8 (6%) had steroid dermatitis, and all resolved with reduced potency.<sup>49</sup> Application of a barrier ointment to unaffected adjacent hair bearing skin prior to steroid placement may mitigate lateral spread.

Selection of steroid potency is determined by both dermatologic condition and location. Face, eyelids, and skin folds such as the axilla, inframammary and inguinal folds, and the neck are more susceptible to steroid side effects than vulvar skin. At these locations, clinicians often select less potent steroids such as desonide 0.05% or hydrocortisone 2.5%. Psoriasis inversus may require a medium potency product like triamcinolone 0.01%. Use of a stronger potency or frequency than required to control the disease process has a vasoconstrictive effect, seen as telangiectasia and pustules and often called 'steroid rosacea' (Fig 4). Management may involve short-term steroid cessation, leading to rebound vasodilation that may produce erythema, discomfort, and itch. This temporary reaction is managed with soothing barrier creams, systemic antihistamines, and/or a 4-6 week course of neuromodulators like gabapentin. Reintroduction of topical steroids requires careful counseling around how much to use, where to apply, and what to do in the case of symptom flare.

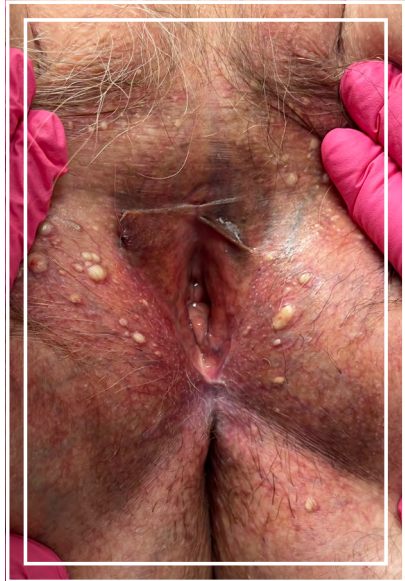

FIGURE 4. Signs of steroid overuse in LS: poorly-demarcated erythema, telangiectasia, and multiple large epidermal cysts.

Several conditions may arise in LS unrelated to over- or under-use of topical steroids. These include epidermal inclusion cysts, cutaneous candidiasis, herpes simplex virus (HSV), and condyloma. The degree to which LS, topical steroids, and/or emollients influence the prevalence of these comorbid entities is unclear. Epidermal cysts and condyloma do not require treatment unless persistently symptomatic, but patients often benefit from reassurance about their benign and often transitory nature. Women with LS have a relative risk of 8.1 for vulvar condyloma or low grade squamous intraepithelial lesion compared to unaffected patients.<sup>50</sup> Suspected condyloma may require histologic confirmation if persistent, bulky, unusual in appearance, or occurring in women with previous HPV-associated neoplasia (see Chapter 11). Candidiasis may occur more commonly than the 0-6% reported in clinical trials and large cohorts.<sup>49</sup> Several clinicopathologic studies report frequent comorbidity of LS, positive genital culture for *Candida albicans*, and mycotic organisms on biopsy.<sup>51-53</sup> Among 201 women with recurrent vulvar candidiasis, 14% had LS or LP.<sup>54</sup> The sparse number of documented cases of HSV activation in LS suggest lesions may be persistent or have an unusual appearance.<sup>55</sup> Episodes of mycotic superinfection and HSV require treatment, and patients with multiple recurrences may benefit from a suppression regimen according to standard practice for women without LS while continuing topical corticosteroid use.

## Limited indication for cessation of topical steroids

Therapy for LS with topical corticosteroids is lifelong, with rare exceptions. For example, a woman with severe dementia or cognitive disability may present with caregivers who explain that application is distressing to the patient and difficult for family or staff (see Chapter 15). Clinicians then explore the surrounding circumstances of LS activity, its symptomatic burden, other comorbid conditions and their prognosis, and if options exist to continue treatment but lessen distress. Sometimes the risk-benefit ratio favors cessation of topical steroids as part of a pivot towards holistic comfort care.

The issue of possible LS quiescence during adolescence and early adulthood is complex. Inappropriate cessation of steroids during this life phase carries risks of permanent anatomic alteration (see Chapter 13). A decision to pause topical steroids in girls and young women with a childhood diagnosis of LS should only be undertaken by vulvar clinicians with the ability to continue routine evaluation of LS activity.

## Maximizing adherence and managing steroid phobia

Adherence to recommended topical corticosteroid regimens among women with LS may be lower than 25%.<sup>56</sup> There are manifold reasons for poor engagement with long-term treatment of LS, some common across chronic diseases, others specific to dermatologic or gynecologic conditions.<sup>57–59</sup> Steroid phobia is common among patients, caregivers, and providers, and impacts on adherence across a range of ocular, oral, and skin disorders.<sup>60</sup> It is characterized by erroneous beliefs and exaggerated concerns about topical corticosteroids and is associated with non-adherence to their use. A study of LS patients found steroid phobia manifested with 40% of patients waiting as long as possible to start topical steroids and then stopping them as soon as they felt symptomatic improvement.<sup>61</sup>

## Patient and cultural factors

Among general dermatology patients who acknowledge non-adherence to topical steroid use, 29% selected 'I forget' as a reason.<sup>62</sup> In LS, symptom status likely influences topical steroid use in a bidirectional manner. Presence of symptoms serves as a reminder to apply treatment, while their absence encourages belief that treatment is not required and/or facilitates forgetfulness.<sup>2</sup> Providers play a key role in disassociating symptoms and the need for treatment through repeated counseling, demonstration with a mirror or image of active LS despite asymptomatic status, and identification of reminder strategies.<sup>1</sup> Recall aids include use of phone reminders or alarms, calendar entries, or coupling steroid use with other routine activities like brushing teeth or taking tablets. Some patients encounter difficulty with high-potency low-frequency regimens and benefit from change to a daily lower-potency treatment plan.<sup>49,58</sup>

Women with LS have worse scores on the genital self-image scale than those with extragenital inflammatory dermatoses. Negative feelings about vulvar appearance may be a barrier to steroid application and interactions with healthcare providers.<sup>11</sup> The impact of sexual trauma, shame, and cultural taboos on vulvar topical steroid use remains unexplored, but

anecdotally these experiences may produce avoidance of genital touch and detachment from vulvovaginal treatment regimens.<sup>59</sup> A trauma-informed approach to examination and explanation may aid in supporting these patients to greater self-efficacy in LS management (see Chapter 3).<sup>63,64</sup>

When asked about reasons for non-adherence to topical corticosteroids, the most common steroid-specific concerns are 1) fear of overuse in 37%, 2) application to broken skin in 17%, 3) words such as ‘sparing’ on the label in 14%, and 4) harmful side effects in 11%.<sup>56,62</sup> Lower health literacy and susceptibility to misinformation are associated with steroid phobia.<sup>2,65</sup> The major sources of misleading information on topical steroids are family, friends, and the internet.<sup>66</sup> Problematic online content themes include: ‘topical steroid addiction,’ ‘steroid withdrawal,’ exaggeration of adverse effects, and suggestion of alternative ‘underlying’ causes with corresponding recommendation of ‘natural’ remedies.<sup>67</sup> These messages, in combination with long-standing community-based steroid phobia, create opportunities for fraudulent marketing to a vulnerable patient population. Some internet-based resources and patient support groups offer accurate information to patients. Clinicians should review online content and direct patients to sites they deem reputable, like the Lichen Sclerosus Support Network, UK Lichen Sclerosus Awareness, and The Lost Labia Chronicles. Mitigating the impacts of health misinformation is difficult. A RCT of targeted education in steroid phobia demonstrated improvements in knowledge after exposure to educational videos and information leaflets, but no change in fears, behaviors, or medication adherence.<sup>68</sup> Persistence of steroid phobia may relate to multidimensional reinforcement by friends, family, package labeling, pharmacists, and health professionals inexperienced in vulvar disease.

## Pharmacist and pharmaceutical company factors

Pharmacists exhibit the highest level of steroid phobia among healthcare workers, with 60% believing topical steroids should not be used long-term for LS.<sup>69,70</sup> A survey of general dermatology patients revealed only 45% recalled a pharmacist encouraging them to use topical steroids as directed by their doctor.<sup>62</sup> Instead, patients reported contrary advice such as ‘apply thinly or sparingly’ in 70% and ‘try non-prescription creams’ or ‘try complementary and alternative treatments before resorting to prescription steroids’ in 35% and 24%, respectively. Negative messages communicated by pharmacists reinforce preexisting worries about medication safety and the patient’s ability to correctly apply it.<sup>62,70</sup> While the solution involves improved education for pharmacists, clinicians meanwhile must preemptively discuss the possibility of misinformed commentary from pharmacy workers when filling their prescriptions.

Product labels for topical corticosteroids state ‘for external use only.’ Super-potent steroid ointments contain the warning to not use longer than 2 consecutive weeks and to not use on the groin. Patients often consider the inner labia minora and vestibule to be ‘internal’ structures when they are not and may interpret the word groin as referring to the whole genital area. Providers must both clarify the anatomic placement of topical steroids and proactively warn patients about misinterpretation of package inserts.

## Clinician and healthcare system factors

High quality patient-clinician communication is the cornerstone of LS management. Among LS patients attending a specialized clinic and counseled by dermatologists regarding long-term topical corticosteroid use, steroid phobia was low compared to community-based cohorts.<sup>71</sup> However, a similar study that compared an internet cohort to a control group from a specialized vulvar clinic found similar rates for steroid phobia in both groups.<sup>61</sup> Counseling must delve into details about quantity, location, time of day, relationship to bathing, and how to manage other concurrent topical products. For example, the widespread recommendation of the ‘fingertip unit’ to guide application quantity is subject to variation in interpretation and may be a barrier to adequate treatment.<sup>72</sup> Consistent, clear information using demonstration, photographs, diagrams, or models may improve understanding of how much to use and where to apply (see Fig 1,2,3). Use of a mirror, clinical photograph, or colposcopic image projection helps patients to see where disease is active and direct their steroid placement. Narrative storytelling with reference to other LS patients’ successful journeys may help allay fears and overcome misinformation.<sup>73</sup>

Discrepancies in advice offered by different healthcare providers exacerbates steroid phobia and reduces treatment adherence.<sup>69,70</sup> While General Practitioners (GP) were more likely than pharmacists to provide positive reinforcement for topical steroid use, patients reported similar rates between provider types of messages like ‘use sparingly,’ ‘may cause skin thinning,’ and ‘not for long-term use.’<sup>62,70</sup> Specialist letters to the GP should detail the selected steroid regimen, its positive impact on skin findings, and the goals of long-term treatment to encourage GP participation in the care plan through provision of scripts and interprofessional communication regarding concerns. Well-written prescriptions, lower drug costs to patients, and short-interval return visits are associated with improved adherence.<sup>58</sup> Additional provider-administered strategies to improve adherence include simplified regimens, provision of written patient information, instruction by specialized nurses, and group learning.<sup>74</sup>

## Surveillance

Once LS control is established, indefinite yearly physical examinations enable clinicians to assess for symptoms, signs of disease activity, architectural changes, comorbid conditions, and neoplasia.<sup>44,75</sup> Women with previous cancer or difficult-to-control disease require more frequent follow-up at intervals of 3-6 months dictated by the clinical scenario.<sup>76</sup> These visits are opportunities to congratulate patients on their progress, reinforce ongoing use, ensure potency and frequency match disease activity, and mitigate ‘treatment burnout.’ Supplemental vulvar self-assessment is feasible for some women and enhances a sense of control over the treatment journey.

Clinical care models, funding structures, access to specialists, and referral networks vary across regions and internationally, limiting the universality of recommendations about follow-up care for LS. When health systems or medical culture dictate that long-term LS management occurs in the primary care setting, the result is often inadequate follow-up and insufficient treatment.<sup>42,75,77-79</sup> However, it is neither feasible nor necessary for all women

with LS to have indefinite surveillance with a vulvar specialist. Instead, vulvar specialists may identify a cohort of clinicians within their network or community with the motivation and knowledge to provide this care. The fundamental requirements are to 1) listen to the woman's concerns, 2) examine her at each visit, 3) provide advice and encouragement regarding steroid therapy, and 4) know when and how to ask for help. Depending on the region and health system, suitable clinicians include women's health nurses, physician's assistants, certified nurse midwives, nurse practitioners, GPs with an interest in women's health, sexual health physicians, and general gynecologists or dermatologists. Asymptomatic women with objectively well-controlled LS on a stable maintenance regimen are suitable candidates for care transition. Maintenance of referral pathways and interprofessional collaboration ensures responsiveness to changes in the clinical scenario via case discussions, ad hoc re-consultation, or longer-interval return visits with the vulvar specialist.<sup>44</sup> There is a continued need for expansion of the provider pool for vulvovaginal conditions through enhancements in trainee and post-graduate education and mentorship.

## Limitations of the literature

While it is widely accepted that topical corticosteroids are the mainstay of initial treatment and ongoing maintenance therapy of vulvar LS, many treatment subtleties remain unexplored and controversial. There are many reasons it is difficult to produce high-quality clinical research on LS, some of these include:

- Inherent ethical concerns of randomization to interventions likely to be inferior to existing topical steroid regimens,
- Lack of consensus around minimum inclusion criteria, assessment of baseline disease activity, and selection of sufficiently homogenous study groups,
- Difficulty in translating patient-centered topical steroid regimens into fixed study protocols,
- Complexity around identification, reporting, and management of comorbid dermatologic and pain conditions during study participation,
- Challenge of establishing outcome sets for a condition with varied manifestations across symptoms and signs, some of which change over time and others, like pre-existing architectural change, remain stable,
- Expense of and logistical barriers to prolonged follow-up in a condition with an extended interval between disease initiation and diagnosis of neoplasia, and
- Insufficient disease visibility and research funding to enable large prospective multi-center studies.

Should current and future research yield solutions to these challenges, myriad topics may be effectively investigated. Does the strategy of high potency/low frequency offer benefits compared to low potency/high frequency regimens? How do varied steroid regimens impact on adherence and patient satisfaction? What role do hormones, like topical or systemic estrogen replacement, play in topical corticosteroid dosing and effectiveness? What is the incidence of candidiasis, HPV-associated disease, HSV, and other comorbid skin conditions in well-managed LS and how do they impact on symptoms, signs, and QoL? Is there a replicable model for transition of effective long-term management from a vulvar specialist to

other women's healthcare providers? While there is no shortage of unanswered questions, progress towards improved study methodology is an essential prerequisite to a more nuanced and patient-oriented understanding of LS management.

## Conclusions and recommendations

Lichen sclerosis is a chronic condition that requires initial control with topical corticosteroids followed by a lifelong regular topical steroid maintenance regimen. Symptoms alone are an insufficient guide to management as they do not reliably correlate with disease activity or risk of cancer. Instead, topical steroid regimens are titrated to achieve objective control of LS and maximize patient satisfaction with their treatment approach. Given the individual variation of LS severity and international differences in drug availability and cost, there is no 'optimal' topical steroid regimen for LS therapy.

- Patients may have symptom control without disease control, therefore examination during surveillance visits is essential to guide treatment.
- Initial steroid regimens often involve daily to twice daily super- or high-potency ointments to achieve normal skin texture and normal or near-normal color.
- Showing people exactly how much steroid to use and where and how to apply it is important to optimize disease control.
- When prescribing topical corticosteroids, ointments are preferred over creams on the vulva.
- Maintenance regimens may be individualized to achieve the goals of ongoing suppression of symptoms and signs, prevention of progressive architectural change, and reduced risk of cancer.
- Patient-centered long-term management plans range from weekly to daily application of a low- to super-potent steroid ointment, depending on underlying disease severity, comorbid conditions, and factors that enhance adherence and QoL.
- Signs of over- or under-use of steroids and disease control at routine surveillance visits allow for alteration to steroid frequency, potency, or both.
- Consistent, specific, and supportive communication with patients, caregivers, and other health professionals helps mitigate the negative impacts of steroid phobia and health misinformation.

## References

1. Vieira-Baptista P, Lima-Silva J, Cavaco-Gomes J, Beires J, Martinez-de-Oliveira J. What Differentiates Symptomatic from Asymptomatic Women with Lichen Sclerosis? *Gynecol Obstet Invest*. 2015;79(4):263-268. doi:10.1159/000367788
2. Lee A, Bradford J, Fischer G. Long-term Management of Adult Vulvar Lichen Sclerosis: A Prospective Cohort Study of 507 Women. *JAMA Dermatol*. 2015;151(10):1061. doi:10.1001/jamadermatol.2015.0643
3. LeFevre C, Hoffstetter S, Meyer S, Gavard J. Management of Lichen Sclerosis With Triamcinolone Ointment: Effectiveness in Reduction of Patient Symptom Scores. *J Low Genit Tract Dis*. 2011;15(3):205-209. doi:10.1097/LGT.0b013e31820a3b6f
4. Cooper SM, Gao XH, Powell JJ, Wojnarowska F. Does Treatment of Vulvar Lichen Sclerosis Influence Its Prognosis? *Arch Dermatol*. 2004;140(6). doi:10.1001/archderm.140.6.702
5. Borghi A, Flacco ME, Zedde P, Toni G, Schettini N, Corazza M. Does Clearance of Vulvar Lichen Sclerosis after a Corticosteroid Treatment Correspond to a Decrease in Disease-Related Burden? Results from a Cohort Study Using Pictorial Representation of Illness and Self-Measure and the Dermatology Life Quality Index. *Dermatol Basel Switz*. 2023;239(1):81-90. doi:10.1159/000526257

6. Corazza M, Toni G, Valpiani G, Morotti C, Borghi A. Does longer duration of corticosteroid treatment improve clearance in vulvar lichen sclerosis? Results from a single centre, comparative, open label study. *Dermatol Ther.* 2021;34(4). doi:10.1111/dth.14955
7. Kohn JR, Connors TM, Chan W, Liang CS, Dao H, Vyas A. Clinical outcomes and adherence to topical corticosteroid therapy in women with vulvar lichen sclerosis: A retrospective cohort study. *J Am Acad Dermatol.* 2020;83(4):1104-1109. doi:10.1016/j.jaad.2020.05.006
8. Wijaya M, Lee G, Fischer G. Why do some patients with vulvar lichen sclerosis on long-term topical corticosteroid treatment experience ongoing poor quality of life? *Australas J Dermatol.* 2022;63(4):463-472. doi:10.1111/ajd.13926
9. Günthert AR, Limacher A, Beltraminelli H, et al. Efficacy of topical progesterone versus topical clobetasol propionate in patients with vulvar Lichen sclerosis – A double-blind randomized phase II pilot study. *Eur J Obstet Gynecol Reprod Biol.* 2022;272:88-95. doi:10.1016/j.ejogrb.2022.03.020
10. Pérez-López FR, Vieira-Baptista P. Lichen sclerosis in women: a review. *Climacteric.* 2017;20(4):339-347. doi:10.1080/13697137.2017.1343295
11. Rivera S, Flood A, Dykstra C, Herbenick D, DeMaria AL. Genital Self-Image, Sexual Function, and Quality of Life Among Individuals with Vulvar and Non-Vulvar Inflammatory Dermatoses. *Arch Sex Behav.* 2022;51(8):3965-3979. doi:10.1007/s10508-022-02353-0
12. Frigerio M, Barba M, Volontè S, et al. Total introital obliteration as a consequence of lichen sclerosis: a rare cause of urinary retention. *Int Urogynecology J.* 2023;34(3):779-781. doi:10.1007/s00192-022-05356-6
13. Fergus KB, Lee AW, Baradaran N, et al. Pathophysiology, Clinical Manifestations, and Treatment of Lichen Sclerosis: A Systematic Review. *Urology.* 2020;135:11-19. doi:10.1016/j.urology.2019.09.034
14. Kherlopian A, Fischer G. Does compliance to topical corticosteroid therapy reduce the risk of development of permanent vulvar structural abnormalities in pediatric vulvar lichen sclerosis? A retrospective cohort study. *Pediatr Dermatol.* 2022;39(1):22-30. doi:10.1111/pde.14840
15. Nerantzoulis I, Grigoriadis T, Michala L. Genital lichen sclerosis in childhood and adolescence—a retrospective case series of 15 patients: early diagnosis is crucial to avoid long-term sequelae. *Eur J Pediatr.* 2017;176(10):1429-1432. doi:10.1007/s00431-017-3004-y
16. Vieira-Baptista P, Pérez-López FR, López-Baena MT, Stockdale CK, Preti M, Bornstein J. Risk of Development of Vulvar Cancer in Women With Lichen Sclerosis or Lichen Planus: A Systematic Review. *J Low Genit Tract Dis.* 2022;26(3):250-257. doi:10.1097/LGT.0000000000000673
17. Chin S, Scurry J, Bradford J, Lee G, Fischer G. Association of Topical Corticosteroids With Reduced Vulvar Squamous Cell Carcinoma Recurrence in Patients With Vulvar Lichen Sclerosis. *JAMA Dermatol.* 2020;156(7):813. doi:10.1001/jamadermatol.2020.1074
18. Pounds R, Tahir S, Dawson C, Woodman C, Luesley D, Yap J. A survey on the use of topical steroids in patients treated for lichen sclerosis-associated vulval squamous cell carcinoma. *J Obstet Gynaecol.* 2018;38(2):265-269. doi:10.1080/01443615.2017.1352572
19. Voss FO, Groenewegen KL, Vermaat H, Bleeker MCG, Van Beurden M. Prevalence of prescribing topical corticosteroids to patients with lichen sclerosis following surgery for vulvar cancer: a survey among gynaecologic oncologists in The Netherlands. *J Obstet Gynaecol.* 2024;44(1):2294330. doi:10.1080/01443615.2023.2294330
20. Pergialiotis V, Bellos I, Biliou EC, Varnava P, Mitsopoulou D, Doumouchtsis SK. An arm-based network meta-analysis on treatments for vulvar lichen sclerosis and a call for development of core outcome sets. *Am J Obstet Gynecol.* 2020;222(6):542-550.e6. doi:10.1016/j.ajog.2019.10.095
21. Lee A, Fischer G. Diagnosis and Treatment of Vulvar Lichen Sclerosis: An Update for Dermatologists. *Am J Clin Dermatol.* 2018;19(5):695-706. doi:10.1007/s40257-018-0364-7
22. Camisa C, Garofola, C C. Topical corticosteroids: Pharmacokinetics. In: Wolverton SE, Wu JJ, eds. *Comprehensive Dermatologic Drug Therapy.* Fourth edition. Elsevier; 2021.
23. Lewis FM, Tatnall FM, Velangi SS, et al. British Association of Dermatologists guidelines for the management of lichen sclerosis, 2018. *Br J Dermatol.* 2018;178(4):839-853. doi:10.1111/bjd.16241
24. Corazza M, Virgili A, Toni G, Borghi A. Mometasone furoate in the treatment of vulvar lichen sclerosis: could its formulation influence efficacy, tolerability and adherence to treatment? *J Dermatol Treat.* 2018;29(3):305-309. doi:10.1080/09546634.2017.1360990
25. Otto A, Du Plessis J, Wiechers JW. Formulation effects of topical emulsions on transdermal and dermal delivery. *Int J Cosmet Sci.* 2009;31(1):1-19. doi:10.1111/j.1468-2494.2008.00467.x
26. Rees S, Arnold S, Kherlopian A, Fischer G. Attitudes Toward Proactive Topical Corticosteroid Use Among Women With Vulvar Lichen Sclerosis. *J Low Genit Tract Dis.* 2024;28(2):183-188. doi:10.1097/LGT.0000000000000791



27. Baeck M, Goossens A. Immediate and delayed allergic hypersensitivity to corticosteroids: practical guidelines. *Contact Dermatitis*. 2012;66(1):38-45. doi:10.1111/j.1600-0536.2011.01967.x
28. Chen JY, Yiannias JA, Hall MR, et al. Reevaluating Corticosteroid Classification Models in Patient Patch Testing. *JAMA Dermatol*. 2022;158(11):1279. doi:10.1001/jamadermatol.2022.3774
29. Bowie AC, Tadrous M, Egeberg A, et al. Agreement and Correlation Between Different Topical Corticosteroid Potency Classification Systems. *JAMA Dermatol*. 2022;158(7):796-800. doi:10.1001/jamadermatol.2022.1706
30. Cattaneo A, De Marco A, Sonni L, Bracco GL, Carli P, Taddei GL. [Clobetasol vs. testosterone in the treatment of lichen sclerosus of the vulvar region]. *Minerva Ginecol*. 1992;44(11):567-571.
31. Goldstein AT, Creasey A, Pfau R, Phillips D, Burrows LJ. A double-blind, randomized controlled trial of clobetasol versus pimecrolimus in patients with vulvar lichen sclerosus. *J Am Acad Dermatol*. 2011;64(6):e99-e104. doi:10.1016/j.jaad.2010.06.011
32. Funaro D, Lovett A, Leroux N, Powell J. A double-blind, randomized prospective study evaluating topical clobetasol propionate 0.05% versus topical tacrolimus 0.1% in patients with vulvar lichen sclerosus. *J Am Acad Dermatol*. 2014;71(1):84-91. doi:10.1016/j.jaad.2014.02.019
33. Virgili A, Borghi A, Toni G, Minghetti S, Corazza M. First randomized trial on clobetasol propionate and mometasone furoate in the treatment of vulvar lichen sclerosus: results of efficacy and tolerability. *Br J Dermatol*. 2014;171(2):388-396. doi:10.1111/bjd.12910
34. Bornstein J, Heifetz S, Kellner Y, Stolar Z, Abramovici H. Clobetasol dipropionate 0.05% versus testosterone propionate 2% topical application for severe vulvar lichen sclerosus. *Am J Obstet Gynecol*. 1998;178(1 Pt 1):80-84. doi:10.1016/s0002-9378(98)70631-3
35. Dalziel KL, Millard PR, Wojnarowska F. The treatment of vulvar lichen sclerosus with a very potent topical steroid (clobetasol propionate 0.05%) cream. *Br J Dermatol*. 1991;124(5):461-464. doi:10.1111/j.1365-2133.1991.tb00626.x
36. Lorenz B, Kaufman RH, Kutzner SK. Lichen sclerosus. Therapy with clobetasol propionate. *J Reprod Med*. 1998;43(9):790-794.
37. Murina F, Rehman S, Di Francesco S, Mantegazza V, Felice R, Bianco V. Vulvar lichen sclerosus: a comparison of the short-term topical application of clobetasol dipropionate 0.05% versus mometasone furoate 0.1%. *J Low Genit Tract Dis*. 2015;19(2):149-151. doi:10.1097/LGT.0000000000000065
38. Borghi A, Corazza M, Minghetti S, Toni G, Virgili A. Continuous vs. tapering application of the potent topical corticosteroid mometasone furoate in the treatment of vulvar lichen sclerosus: results of a randomized trial. *Br J Dermatol*. 2015;173(6):1381-1386. doi:10.1111/bjd.14074
39. Virgili A, Borghi A, Minghetti S, Corazza M. Mometasone furoate 0.1% ointment in the treatment of vulvar lichen sclerosus: a study of efficacy and safety on a large cohort of patients. *J Eur Acad Dermatol Venereol JEADV*. 2014;28(7):943-948. doi:10.1111/jdv.12219
40. Virgili A, Minghetti S, Borghi A, Corazza M. Proactive maintenance therapy with a topical corticosteroid for vulvar lichen sclerosus: preliminary results of a randomized study. *Br J Dermatol*. 2013;168(6):1316-1324. doi:10.1111/bjd.12273
41. Corazza M, Borghi A, Minghetti S, Toni G, Virgili A. Clobetasol propionate vs. mometasone furoate in 1-year proactive maintenance therapy of vulvar lichen sclerosus: results from a comparative trial. *J Eur Acad Dermatol Venereol*. 2016;30(6):956-961. doi:10.1111/jdv.13166
42. Selk A. A Survey of Experts Regarding the Treatment of Adult Vulvar Lichen Sclerosus. *J Low Genit Tract Dis*. 2015;19(3):244-247. doi:10.1097/LGT.0000000000000106
43. Krapf JM, Mitchell L, Holton MA, Goldstein AT. Vulvar Lichen Sclerosus: Current Perspectives. *Int J Womens Health*. 2020;12:11-20. doi:10.2147/IJWH.S191200
44. Yeon J, Oakley A, Olsson A, et al. Vulval lichen sclerosus: An Australasian management consensus. *Australas J Dermatol*. 2021;62(3):292-299. doi:10.1111/ajd.13594
45. De Luca DA, Papara C, Vorobyev A, et al. Lichen sclerosus: The 2023 update. *Front Med*. 2023;10:1106318. doi:10.3389/fmed.2023.1106318
46. Renaud-Vilmer C, Cavalier-Balloy B, Porcher R, Dubertret L. Vulvar lichen sclerosus: effect of long-term topical application of a potent steroid on the course of the disease. *Arch Dermatol*. 2004;140(6):709-712. doi:10.1001/archderm.140.6.709
47. Mautz TT, Krapf JM, Goldstein AT. Topical Corticosteroids in the Treatment of Vulvar Lichen Sclerosus: A Review of Pharmacokinetics and Recommended Dosing Frequencies. *Sex Med Rev*. 2022;10(1):42-52. doi:10.1016/j.sxmr.2021.03.006
48. Simpson, Rosalind C. PEARLS Trial: Proactive against reactive therapy for the prevention of lichen sclerosus exacerbation and progression of disease – a pragmatic, parallel group randomised controlled trial with embedded economic evaluation and process evaluation. Accessed June 11, 2024. <https://www.nottingham.ac.uk/pearls/>



49. Bradford J, Fischer G. Long-term management of vulvar lichen sclerosus in adult women. *Aust N Z J Obstet Gynaecol.* 2010;50(2):148-152. doi:10.1111/j.1479-828X.2010.01142.x
50. Söderlund JM, Hieta NK, Kurki SH, et al. Comorbidity of Urogynecological and Gastrointestinal Disorders in Female Patients With Lichen Sclerosus. *J Low Genit Tract Dis.* 2023;27(2):156-160. doi:10.1097/LGT.0000000000000727
51. Day T, Moore S, Bohl TG, Scurry J. Comorbid Vulvar Lichen Planus and Lichen Sclerosus. *J Low Genit Tract Dis.* 2017;21(3):204-208. doi:10.1097/LGT.0000000000000307
52. Day T, Borbolla Foster A, Phillips S, et al. Can Routine Histopathology Distinguish Between Vulvar Cutaneous Candidosis and Dermatophytosis? *J Low Genit Tract Dis.* 2016;20(3):267-271. doi:10.1097/LGT.0000000000000208
53. Day T, Chapman-Burgess E, Scurry J. Clinicopathologic Overlap of Vulvar Psoriasis and Candidiasis. *J Low Genit Tract Dis.* 2024;28(2):175-182. doi:10.1097/LGT.0000000000000801
54. Crouss T, Sobel JD, Smith K, Nyirjesy P. Long-Term Outcomes of Women With Recurrent Vulvovaginal Candidiasis After a Course of Maintenance Antifungal Therapy. *J Low Genit Tract Dis.* 2018;22(4):382-386. doi:10.1097/LGT.0000000000000413
55. Conforti C, Toffoli L, Giuffrida R, et al. An unusual presentation of genital herpes in a patient affected by lichen sclerosus et atrophicus: A case report and a combined treatment proposal. *Dermatol Ther.* 2020;33(2). doi:10.1111/dth.13239
56. Nic Dhonncha E, O'Connor C, O'Connell G, Quinlan C, Roche L, Murphy M. Adherence to treatment with prescribed topical corticosteroid therapy and potential barriers to adherence among women with vulvar lichen sclerosus: a prospective cross-sectional study. *Clin Exp Dermatol.* 2021;46(4):734-735. doi:10.1111/ced.14527
57. McQuaid EL, Landier W. Cultural Issues in Medication Adherence: Disparities and Directions. *J Gen Intern Med.* 2018;33(2):200-206. doi:10.1007/s11606-017-4199-3
58. Ahn CS, Culp L, Huang WW, Davis SA, Feldman SR. Adherence in dermatology. *J Dermatol Treat.* 2017;28(2):94-103. doi:10.1080/09546634.2016.1181256
59. Araya-Castro P, Roa-Alcaino S, Celedón C, Cuevas-Said M, De Sousa Dantas D, Sacomori C. Barriers to and facilitators of adherence to pelvic floor muscle exercises and vaginal dilator use among gynecologic cancer patients: a qualitative study. *Support Care Cancer.* 2022;30(11):9289-9298. doi:10.1007/s00520-022-07344-4
60. Contento M, Cline A, Russo M. Steroid Phobia: A Review of Prevalence, Risk Factors, and Interventions. *Am J Clin Dermatol.* 2021;22(6):837-851. doi:10.1007/s40257-021-00623-6
61. Delpero E, Sriharan A, Selk A. Steroid Phobia in Patients With Vulvar Lichen Sclerosus. *J Low Genit Tract Dis.* 2023;27(3):286-290. doi:10.1097/LGT.0000000000000753
62. Farrugia LL, Lee A, Fischer G, Blaszczyński A, Carter SR, Smith SD. Evaluation of the influence of pharmacists and GPs on patient perceptions of long-term topical corticosteroid use. *J Dermatol Treat.* 2017;28(2):112-118. doi:10.1080/09546634.2016.1213353
63. Gorfinkel I, Perlow E, Macdonald S. The trauma-informed genital and gynecologic examination. *Can Med Assoc J.* 2021;193(28):E1090-E1090. doi:10.1503/cmaj.210331
64. Owens L, Terrell S, Low LK, et al. Universal precautions: the case for consistently trauma-informed reproductive healthcare. *Am J Obstet Gynecol.* 2022;226(5):671-677. doi:10.1016/j.jag.2021.08.012
65. Hrin ML, Bray JK, Fleischer AB, Feldman SR. Assessing the relationship between topical corticosteroid phobia and susceptibility to misinformation in patients with atopic dermatitis. *J Eur Acad Dermatol Venereol.* 2022;36(2). doi:10.1111/jdv.17663
66. Smith SD, Farrugia LL, Harris V, et al. Evaluation of the influence of family and friends, and the Internet on patient perceptions of long-term topical corticosteroid use. *J Dermatol Treat.* 2017;28(7):642-646. doi:10.1080/09546634.2017.1306017
67. Finnegan P, Murphy M, O'Connor C. #corticophobia: a review on online misinformation related to topical steroids. *Clin Exp Dermatol.* 2023;48(2):112-115. doi:10.1093/ced/llac019
68. Choi E, Tan KW, Tang F, Tan C, Chandran NS. Efficacy of targeted education in reducing topical steroid phobia: A randomized clinical trial. *J Am Acad Dermatol.* 2020;83(6):1681-1687. doi:10.1016/j.jaad.2020.02.079
69. Lambrechts L, Gilissen L, Morren MA. Topical Corticosteroid Phobia Among Healthcare Professionals Using the TOPI-COP Score. *Acta Derm Venereol.* 2019;99(11):1004-1008. doi:10.2340/00015555-3220
70. Nic Dhonncha E, Murphy M. Attitudes and advice-giving behaviours of pharmacists in relation to topical corticosteroid use for patients with lichen sclerosus. *Clin Exp Dermatol.* 2022;47(1):190-192. doi:10.1111/ced.14888
71. Borghi A, Flacco ME, Pacetti L, Toni G, Corazza M. Topical Corticosteroid Phobia Among Women Affected With Vulvar Lichen Sclerosus: Results From a Cross-sectional Survey. *J Low Genit Tract Dis.* 2024;28(2):169-174. doi:10.1097/LGT.0000000000000800

72. Dekio I, Morita E. The weight of a finger-tip unit of ointment in 5-gram tubes. *J Dermatol Treat.* 2011;22(5):302-303. doi:10.3109/09546631003797098
73. D. Jones M, Anderson Crow D. How can we use the 'science of stories' to produce persuasive scientific stories? *Palgrave Commun.* 2017;3(1):53. doi:10.1057/s41599-017-0047-7
74. Mueller SM, Itin P, Vogt DR, et al. Assessment of "corticophobia" as an indicator of non-adherence to topical corticosteroids: A pilot study. *J Dermatol Treat.* 2017;28(2):104-111. doi:10.1080/09546634.2016.1201189
75. Van der Avoort IAM, Tiemes DEM, van Rossum MM, van der Vleuten CJM, Massuger LFAG, de Hullu JA. Lichen sclerosis: treatment and follow-up at the departments of gynaecology and dermatology. *J Low Genit Tract Dis.* 2010;14(2):118-123. doi:10.1097/LGT.0b013e3181c4bfe6
76. Jones RW, Scurry J, Neill S, MacLean AB. Guidelines for the follow-up of women with vulvar lichen sclerosis in specialist clinics. *Am J Obstet Gynecol.* 2008;198(5):496.e1-3. doi:10.1016/j.ajog.2007.05.031
77. Morrel B, van Eersel R, Burger CW, et al. The long-term clinical consequences of juvenile vulvar lichen sclerosis: A systematic review. *J Am Acad Dermatol.* 2020;82(2):469-477. doi:10.1016/j.jaad.2019.08.030
78. Kohn JR, McClatchey TM, Chan W, Liang CS, Dao H, Vyas A. Vulvar Lichen Sclerosis in Gynecology and Dermatology Clinics: The Link between Treatment Compliance and Outcomes [37G]. *Obstet Gynecol.* 2018;131(1):85S-85S. doi:10.1097/01.AOG.0000533386.27483.e8
79. Balasubramaniam P, Lewis FM. Long-term follow-up of patients with lichen sclerosis: does it really happen? *J Obstet Gynaecol J Inst Obstet Gynaecol.* 2007;27(3):282. doi:10.1080/01443610701251539

# General and vulvovaginal health

*Amy Stenson, Emily Murphy, Christina Kraus*

**V**ulvar care advice is an essential component of lichen sclerosus (LS) management. Clinicians offer counseling about bathing, toileting, hair removal, clothing selection, sexual practices, and menstrual care. Discussion centers around avoidance of irritants or allergens and awareness of the misleading marketing claims attached to ‘intimate wellness’ products. Many patients ask about diet and exercise changes that might alleviate or exacerbate their LS and how their other health issues and LS might impact on each other. While minimal evidence exists to inform counseling about general and vulvovaginal health as it relates to LS, clinicians may offer time-tested common sense information that minimizes harms and unnecessary expenditures while empowering women to identify what works for them. Daily vulvar care regimens should facilitate topical steroid use and acknowledge women’s busy lives and competing priorities.

## Diet and exercise

There is no dietary approach shown to impact on the development or treatment response of LS. While vitamin D, omega-3 fatty acids, and antioxidants demonstrate immunomodulatory effects that may mitigate symptoms in some autoimmune diseases, none have been assessed in patients with LS.<sup>1,2</sup> Clinical trials are ongoing to assess outcomes of an ‘anti-inflammatory diet’ compared to a control ‘western’ or standard diet in people with arthritis.<sup>3,4</sup> The anti-inflammatory diet overlaps with the Mediterranean diet (MedDiet) and both mirror standard public health recommendations to eat a diverse array of multicolored fresh vegetables and fruit, nuts and seeds, whole grains, legumes, and fatty fish. This is accompanied by avoidance of refined sugars and carbohydrates, fruit juice and sweetened beverages, meat, saturated and trans-fats, and processed foods. Interventional studies suggest that sustained adherence to the MedDiet improves glycemic control in diabetic patients, reduces blood pressure, improves inflammatory parameters like CRP and IL-6, and decreases the risk of myocardial infarction and cardiovascular death.<sup>5</sup> When discussing diet with LS patients, the emphasis is on maximizing general health and longevity rather than hoping for impacts on the skin condition.

The benefits of exercise for immune function, stress reduction, sleep, and overall well-being are well established, but its specific effect on LS is unknown.<sup>6</sup> Forms of exercise involving genital friction, like bicycling and triathlon training, may exacerbate vulvar inflammatory dermatoses. Swimming is frictionless and chlorine pools have an antimicrobial benefit, but

prolonged submersion affects the skin's barrier function and wearing wet swimsuits outside the pool serves as a contact irritant. Application of an emollient or barrier cream prior to exercise, wearing loose non-allergenic clothing if possible, and promptly changing out of wet or sweaty garments may mitigate problems arising from fitness routines.<sup>7</sup> Anecdotally, powerlifting, pole dancing, horse riding, and intense Pilates may exacerbate pelvic floor dysfunction, but the scant evidence on this topic is mixed.<sup>8,9</sup> Providers may reassure LS patients that yoga and brisk walking offer myriad health benefits while not provoking skin symptoms.

## Cleansing and avoidance of contact irritants and allergens

Vulvar skin is prone to contact irritants and allergens due to increased permeability, occlusion, and friction.<sup>10</sup> Permeability relates to robust blood flow, high follicle count on hair bearing skin, and lack of stratum corneum at the mucocutaneous junction and non-keratinized epithelium.<sup>11</sup> The LS-specific vulvar environment increases the risk of sensitization to allergens.<sup>10,12</sup> These tendencies may be exacerbated by aggressive cleansing practices adopted by many patients when they develop itch or are told they have a rash. Frequent washing, harsh soaps, and anti-septics may alter the vulvovaginal microbiome and activate local inflammatory cascades.<sup>13–15</sup>

Clinicians may advise that once daily washing is generally sufficient to manage routine exposure to sweat, discharge, urine, and feces.<sup>13,16</sup> Water alone or in combination with a non-allergenic non-soap cleanser may be applied to the mons pubis and spread gently around the vulva with one's hands. Washcloths and loofahs are not recommended as scrubbing may produce skin trauma and strip away the skin's barrier function. Patients pat dry with a frequently laundered towel and may apply steroid ointment immediately after their shower or bath. Use of a hairdryer after bathing may be overly drying or risk thermal injury. Soaking for a fixed duration prior to steroid application is unnecessary. If not using a steroid, women instead apply an unscented soothing emollient, oil, or ointment immediately after towel-drying.<sup>16</sup> Patients with erosions, fissures, or recent vulvovaginal surgery may benefit from sitz baths. This involves filling a bathtub or large basin with plain warm water and sitting in it for 10-20 minutes, 2 to 3 times a day. A pinch of Epsom salt, sea salt, or bicarbonate soda may be used but is not required.

## Toileting and bowel health

Bowel dysfunction exacerbates vulvar symptoms and perianal LS control. Strategies to prevent or address constipation include a high-fiber diet, regular use of fiber supplements, drinking water throughout the day, daily exercise, and going to the toilet when there is an urge. Use of a barrier ointment prior to bowel movements protects the skin from subsequent cleaning efforts. While some patients tolerate wiping with fragrance-free toilet paper, others benefit from cleaning with water from a bidet or peri bottle.<sup>16</sup> A peri bottle also helps alleviate discomfort from urine in contact with eroded or fissured skin. Wet wipes are not recommended for post-toilet cleansing. An analysis of 34 wet wipe brands, including those marketed as 'fragrance free,' 'sensitive,' or 'gentle,' demonstrated an average of 2.5 allergens per product, most often fragrances or botanicals.<sup>17</sup> Mineral oil placed on toilet paper is an alternative mechanism for cleaning after a bowel movement.

## Clothing and undergarments

Loose-fitting clothing is usually more comfortable for women with vulvovaginal conditions and allows for aeration and temperature regulation. In contrast, tight jeans, hose, leggings, body shapers, and other close-fitting garments, particularly when made of synthetic fabrics like polyester, nylon, and Lycra, may provoke irritation or discomfort through increased moisture and friction. Breathable natural fiber underwear with a full backside is best.<sup>18</sup> If there is sensitivity to elastic at leg and waist openings, shorts styles may be preferred. Some patients benefit from sleeping without underwear, instead wearing an oversized t-shirt or nightgown. Laundry routines are another potential source of allergens. Patients may benefit from hypoallergenic laundry detergents, using half the recommended amount of detergent, and doing a double rinse cycle. Clinicians should recommend against use of fabric softeners, dryer sheets, and laundry products that claim to be antibacterial, antiviral, and/or anti-yeast.

## Hair management

There is limited evidence on the methods and risks of pubic hair removal. While best practices involve leaving hair alone or trimming, patients often seek advice on this topic arising from societal pressures to remove pubic hair.<sup>19</sup> Conversations should start with reassurance that hair removal does not improve hygiene. Rather, the lack of hair may alter moisture wicking and increase contact between the skin and damp clothing. Shaving, waxing, and any type of mechanical hair removal have the potential to worsen LS given the propensity for koebnerization. Cream depilatories and sugaring may contain allergens or irritants.<sup>20</sup> The preferred option in LS is laser hair removal because it is less traumatic, but it requires multiple sessions, may be cost-prohibitive, and is less effective in people with light-colored hair. If trimming is not an acceptable strategy, direct patients to laser clinics and providers familiar with treating all skin types, as device types and settings vary and inappropriate energy application may result in dyspigmentation or burns.

## Emollients and barrier creams

While often used interchangeably, the terms 'emollient' and 'barrier cream' have slightly different meanings. For most patients with LS, it does not matter the category to which their favored product pertains. More important is that each woman identifies a product that is soothing, cost-effective, and fits into her daily routine. The varied products exist on a spectrum of appearance and function and there is conceptual overlap between emollients and barriers.

Emollients serve as moisturizers and have a thin consistency that spreads easily, absorbs quickly, and leaves little residue. The ideal emollient adds back moisture, enhances the skin's barrier function, and improves skin symptoms.<sup>21,22</sup> On the vulva, oils and ointments are preferred as emollients as they do not contain alcohol or preservatives. Ointments usually contain petrolatum or mineral oil alone or in combination with silicone- or ceramide-based ingredients. Plain white petrolatum is a good option due to its low cost and minimal risk of inducing contact allergy. Refined white petroleum jelly, the main ingredient in several over-the-counter ointments, is not the same as unrefined petrolatum materials. Single-source

plant-based oils like coconut and olive oil are other cost-effective emollients with a low risk of precipitating allergic or irritant contact dermatitis. If patients express concern about dripping or staining of the underwear, advise they use less of the product at each application.

Barrier creams are thicker than emollients and adhere to the skin surface, locking in moisture and providing a water-impenetrable layer between the skin and the outside world.<sup>23</sup> The most familiar barrier creams are marketed for use in babies to prevent or manage diaper rash. Zinc-based products are another common example, with their adherent nature providing prolonged sun protection while swimming. In patients with LS, barrier creams may protect the skin against wetness and friction in the setting of incontinence or menses requiring pad use. They also reduce discomfort associated with exposure of fissures or erosions to urine. Barrier creams often have a longer ingredients list than emollients, sometimes containing potential allergens like lanolin, propylene glycol, and castor oil. The occlusive nature of barrier creams may increase epidermal cysts.

Creams and lotions are of limited utility on vulvar skin. They are water-based products that require alcohols and preservatives to prevent bacterial overgrowth. These ingredients may provoke stinging or burning sensation or contact allergy.<sup>24</sup> Creams and lotions often have a long list of additives with limited clinical usefulness. They have limited durability, disappearing with exposure to moisture. However, some patients are unable to identify an emollient or barrier product they tolerate and may instead select a cream that meets their needs for intermittent moisturizing and symptom improvement.

## Vaginal and menstrual care

Reproductive-age women not using hormonal contraception may describe cyclicality to LS symptoms, as also described in atopic dermatitis and psoriasis.<sup>25</sup> Estrogen receptors are present on keratinocytes and respond to estrogen fluctuations. Skin hydration, collagen content, glycosaminoglycan concentration, pH, and skin barrier function may be impacted by the menstrual cycle and are hypothesized to contribute to itch and irritation.<sup>26</sup> Sanitary pads may provoke allergic or irritant contact dermatitis, aggravating symptoms and altering skin appearance. Increased cleansing and hygiene practices during menstruation may further exacerbate LS.

There are multiple options for mitigating the skin impacts of menstruation. Menstrual suppression with contraceptives is safe for most women and often provides benefits for gynecologic disorders like pelvic pain and abnormal uterine bleeding.<sup>27</sup> Amenorrhea is most reliably achieved with the levonorgestrel-containing intrauterine device, intramuscular medroxyprogesterone, or combined oral contraceptives (COC), with etonogestrel implants and progesterone-only tablets less frequently achieving full menstrual suppression.<sup>28</sup> For women attempting pregnancy or who wish to avoid hormonal medications, menstrual cups provide an environmentally sustainable alternative to tampons and spare the vulvar skin from contact with pads. Reusable leak-proof underwear may be more comfortable and likewise less irritating than pads. Reusable menstrual products have high acceptability and uptake in resource-replete countries, with 37% of Australian and 55% of Spanish women reporting recent use.<sup>29-31</sup>

Women may administer an array of vaginal products for various reasons. Rates of douching differ by generation, cultural background, and socioeconomic status.<sup>32</sup> Commercial douching products make misleading claims that target women's concerns about cleanliness, odor, and lactobacilli health. Evaluation of a lactic acid-containing douche showed no difference in vaginal pH or microbiota, but an increased risk of positive culture for *Candida albicans* and higher odds of diverse anaerobic flora if used during menses.<sup>33</sup> Products containing acetic acid, citric acid, povidone iodine, or sodium bicarbonate increase vaginal epithelial cell death and secretion of pro-inflammatory cytokines.<sup>34</sup> Clinicians should reassure patients that the vagina does not require targeted cleansing and make a strong recommendation against douching.

Lubricants facilitate a variety of activities to include vaginal and anal sex, condom use, placement of dilators or vibrators, and applicator insertion. They are especially useful for women during low-estrogen life phases like menopause, lactation, and/or use of gonadotropin-agonists, aromatase inhibitors, high-dose continuous progestogens, or low-dose COC. The ideal lubricant has a similar pH and osmolality to physiologic vaginal discharge - 4.5 and 1200 milliosmoles per kilogram, respectively.<sup>35</sup> Water-based lubricants are familiar and inexpensive, but most commercial products have a high osmolality and pH in the range of 5 to 8. Hyperosmolar products disrupt the epithelium and may provoke cell necrosis. Water-based lubricants contain bactericidal compounds like chlorhexidine or methylparaben that may kill lactobacilli or otherwise impact genital microflora.<sup>36</sup> Silicone-based lubricants offer a better-matched osmolality and do not affect epithelial cell integrity, but have a neutral rather than acidic pH. The user experience of silicone-based lubricant is a long-lasting slippery sensation that is maintained in or under water. Silicone products are compatible with condom use, must be purchased, are less widely available than other options, and may be expensive. Oil-based lubricants include any single-source unscented oil like coconut, olive, or avocado. This option is readily available and doubles as an emollient but is incompatible with condoms. An observational study of intravaginal practices suggested that candidal colonization was associated with oil use and bacterial vaginosis with petrolatum use, but its interpretation is limited by multiple confounders to include pre-existing vulvovaginal conditions, high rates of douching, over-the-counter antifungal use, and a 27% prevalence of HIV.<sup>37</sup> Lubricant selection is a highly personal choice influenced by multiple factors, but for most women with LS an oil- or silicone-based option is preferable to commercial water-based lubricants.

Vaginal moisturizers may improve symptoms and sexual comfort in women with genitourinary syndrome of menopause (GSM) or other low estrogen states.<sup>38</sup> These water-based products adhere to the vaginal epithelium and mimic physiologic secretions. Moisturizers are intended for ongoing routine use at the vagina and vestibule, with effects lasting 2-3 days.<sup>35</sup> Most products contain an acid to lower the vaginal pH, polymers to promote adherence, preservatives, and a variety of other ingredients to achieve a marketable viscosity and perceived healthfulness. Products may contain hyaluronic, sorbic, citric, or levulinic acid and additives like aloe leaf juice or hop, kiwifruit plant, or camellia japonica leaf/flower extracts. Vaginal moisturizers are an accessible and acceptable intervention to women wary of hormonal therapies, but outcome data suggest the response is a placebo effect.<sup>39</sup> A large randomized

trial showed no difference between placebo hydroxyethylcellulose gel, Replens® moisturizer, or twice weekly 10mcg estradiol tablet on improvements in sexual function and distress questionnaire scores.<sup>40</sup> All groups experienced approximately 50% improvement in symptoms, with the only difference between groups being an improved vaginal maturation index after estrogen exposure. An expert commentary suggested that postmenopausal women experiencing vulvovaginal symptoms should “choose the cheapest moisturizer or lubricant available over-the-counter,” until high-quality evidence demonstrates benefit to another approach.<sup>39</sup>

The use of topical estrogen during menopause has a robust evidence base supporting efficacy and safety, and may be extrapolated to women with other etiologies of hypoestrogenism (see Chapter 15).<sup>41</sup> However, there are limited studies to inform the use of topical estrogen in reproductive-age patients with LS. A cohort of 50 premenopausal women diagnosed with vulvodynia who used oral contraceptives with varied estrogen dosing were advised to cease the COC and apply compounded estradiol 0.03% and testosterone 0.01% to the vestibule daily.<sup>42</sup> After a mean treatment duration of 20 weeks, the group had diminished pain scores on a 10-point VAS scale and an increase in mean free testosterone levels from 0.2 to 0.8 ng/dL. A similarly designed Italian study provided intravaginal 0.5mg estriol 2-3 times per week to premenopausal women with bladder pain syndrome and reported improvement in pain and sexual function questionnaire scores.<sup>43</sup> A case series of women taking spironolactone who presented with dyspareunia treated with a topical estradiol/testosterone gel also reported symptom resolution.<sup>44</sup> The varied interventions, uncontrolled designs, and subjective outcomes of these studies raise the possibility that improvements are due to placebo effect or relate to androgens, other hormonal metabolites, or excipients. Topical estrogen is recommended for transgender men taking gender-affirming testosterone who report sexual pain or other symptoms of vaginal hypoestrogenism, but outcome assessment studies are lacking.<sup>45</sup>

## Resources for patients, social media, and support groups

Management of LS and vulvovaginal health advice should be supplemented with patient-oriented resources. The ISSVD and multiple other vulvovaginal professional organizations offer open access information sheets and online educational content. Many patients turn to social media for information and support on topics ranging from the experience of living with LS to sexual health practices, and from optimal use of topical steroids to the array of proposed alternative management strategies.<sup>46</sup> A cross-sectional analysis of Facebook support groups for LS found over 78% of topical preparations mentioned on these sites contained at least one allergen.<sup>47</sup> Patients often seek alternative non-steroid regimens to control or ‘cure’ LS, with the popularity of various products waxing and waning over time.

One of the most persistent social media alternative remedy trends is the use of Borax for an array of health conditions. Borax, or sodium borate/tetraborate, is an insecticide, preservative, and antifungal agent. A white powder that dissolves in water, it is classified as a poison and is banned as a food additive in multiple jurisdictions. Its use for LS is promulgated across multiple sites with posts advising baths, dabbing with cotton swabs, application of pastes, and/or ingestion. The British Association of Dermatologists released a statement in 2020



advising against Borax use for skin conditions, citing safety concerns and lack of scientific evaluation, and reinforced the recommendation for treatment and monitoring of LS by a medical professional. Several well-recognized support groups also addressed this topic on their webpages, advising there is no cure for LS and Borax may have negative health consequences. Clinicians may wish to ask patients about alternative remedies and provide supportive education to mitigate risks and counter misinformation.

## Conclusions and recommendations

Clinician and patient attention to general vulvovaginal health facilitates LS treatment, improves symptoms, and enhances self-efficacy. Vulvovaginal care regimens are most sustainable when they are low cost, pragmatic, soothing, transportable, and fit easily into daily life. Clinicians provide education and reassurance to fortify patients against the onslaught of anxiety-provoking social media trends and ubiquitous direct-to-consumer marketing.

- There is no diet or exercise program known to impact on LS, but a healthful diet and regular exercise benefit overall well-being and longevity.
- Loose-fitting, natural fiber clothing, exercise gear, and underwear may reduce moisture and friction and improve skin health.
- Patients should review all products that contact their skin or clothing to identify potential allergens and irritants and substitute or eliminate items containing problem ingredients.
- Complex multistep regimens for topical steroid or emollient placement may impede adherence and are unlikely to improve control of LS-related symptoms and signs.
- Vulvovaginal and sexual health may be aided by menstrual management strategies and use of lubricants.
- Clinicians should provide written handouts and guidance on reliable internet resources and support groups to facilitate patients' LS journey and reduce harms associated with non-use of steroids and untested or unsafe home remedies.

## References

1. Nobs SP, Zmora N, Elinav E. Nutrition Regulates Innate Immunity in Health and Disease. *Annu Rev Nutr.* 2020;40:189-219. doi:10.1146/annurev-nutr-120919-094440
2. Swenson CW, Schimpf MQ, Menees SB, Haefner HK, Berger MB. Comparison of Serum Vitamin D Levels in Relation to Bowel and Bladder Symptoms in Women with Vulvar Diseases. *Int J Vitam Nutr Res Int Z Vitam- Ernahrungsforschung J Int Vitaminol Nutr.* 2020;90(3-4):266-272. doi:10.1024/0300-9831/a000527
3. Hulander E, Bärebring L, Turesson Wadell A, et al. Proposed Anti-Inflammatory Diet Reduces Inflammation in Compliant, Weight-Stable Patients with Rheumatoid Arthritis in a Randomized Controlled Crossover Trial. *J Nutr.* 2021;151(12):3856-3864. doi:10.1093/jn/nxab313
4. Law L, Heerey JL, Devlin BL, et al. Effectiveness of an anti-inflammatory diet versus low-fat diet for knee osteoarthritis: the FEAST randomised controlled trial protocol. *BMJ Open.* 2024;14(4):e079374. doi:10.1136/bmjopen-2023-079374
5. Guasch-Ferré M, Willett WC. The Mediterranean diet and health: a comprehensive overview. *J Intern Med.* 2021;290(3):549-566. doi:10.1111/joim.13333
6. Salimans L, Liberman K, Njemini R, Kortekaas Krohn I, Gutermuth J, Bautmans I. The effect of resistance exercise on the immune cell function in humans: A systematic review. *Exp Gerontol.* 2022;164:111822. doi:10.1016/j.exger.2022.111822
7. O'Connor C, McCarthy S, Murphy M. Pooling the evidence: A review of swimming and atopic dermatitis. *Pediatr Dermatol.* 2023;40(3):407-412. doi:10.1111/pde.15325

8. Bø K, Nygaard IE. Is Physical Activity Good or Bad for the Female Pelvic Floor? A Narrative Review. *Sports Med.* 2020;50(3):471-484. doi:10.1007/s40279-019-01243-1
9. Louis-Charles K, Biggie K, Wolfenbarger A, Wilcox B, Kienstra CM. Pelvic Floor Dysfunction in the Female Athlete. *Curr Sports Med Rep.* 2019;18(2):49-52. doi:10.1249/JSR.0000000000000563
10. Woodruff CM, Trivedi MK, Botto N, Kornik R. Allergic Contact Dermatitis of the Vulva. *Dermat Contact Atopic Occup Drug.* 2018;29(5):233-243. doi:10.1097/DER.0000000000000339
11. Farage MA. Vulvar susceptibility to contact irritants and allergens: a review. *Arch Gynecol Obstet.* 2005;272(2):167-172. doi:10.1007/s00404-005-0732-4
12. Marren P, Wojnarowska F, Powell S. Allergic contact dermatitis and vulvar dermatoses. *Br J Dermatol.* 1992;126(1):52-56. doi:10.1111/j.1365-2133.1992.tb08403.x
13. Chen Y, Bruning E, Rubino J, Eder SE. Role of female intimate hygiene in vulvovaginal health: Global hygiene practices and product usage. *Womens Health Lond Engl.* 2017;13(3):58-67. doi:10.1177/1745505717731011
14. Nkamedjie Pete PM, Mabvouna Biguioh R, Bitá Izacar AG, Béchir Adogaye SB, Nguemo C. Genital hygiene behaviors and practices: A cross-sectional descriptive study among antenatal care attendees. *J Public Health Afr.* 2019;10(1). doi:10.4081/jphia.2019.746
15. Pyle HJ, Evans JC, Artami M, et al. Assessment of the Cutaneous Hormone Landscapes and Microbiomes in Vulvar Lichen Sclerosus. *J Invest Dermatol.* Published online February 2024;S0022202X24001118. doi:10.1016/j.jid.2024.01.027
16. Diagnosis and Management of Vulvar Skin Disorders: ACOG Practice Bulletin Summary, Number 224. *Obstet Gynecol.* 2020;136(1):222-225. doi:10.1097/AOG.0000000000003945
17. Newton J, Richardson S, Van Oosbre AM, Yu J, Silence C. A cross-sectional study of contact allergens in feminine hygiene wipes: a possible cause of vulvar contact dermatitis. *Int J Women's Dermatol.* 2022;8(4):e060. doi:10.1097/JW9.0000000000000060
18. D'Antuono A, Bellavista S, Negosanti F, Zauli S, Baldi E, Patrizi A. Dermaisilk briefs in vulvar lichen sclerosus: an adjuvant tool. *J Low Genit Tract Dis.* 2011;15(4):287-291. doi:10.1097/LGT.0b013e31821380a0
19. Mezin-Sarbu E, Wohlrab J. Epilation and depilation in the genital area - motivation, methods, risks and recommendations from a dermatological point of view. *J Dtsch Dermatol Ges J Ger Soc Dermatol JDDG.* 2023;21(5):455-462. doi:10.1111/ddg.14993
20. Lim V, Simmons BJ, Maranda EL, Afifi L, Kallis PJ, Jimenez J. Sugaring—Modern Revival of an Ancient Egyptian Technique for Hair Removal. *JAMA Dermatol.* 2016;152(6):660. doi:10.1001/jamadermatol.2015.4864
21. Singh N, Mishra N, Ghatage P. Treatment Options in Vulvar Lichen Sclerosus: A Scoping Review. *Cureus.* Published online February 24, 2021. doi:10.7759/cureus.13527
22. Virgili A, Minghetti S, Borghi A, Corazza M. Long-term maintenance therapy for vulvar lichen sclerosus: the results of a randomized study comparing topical vitamin E with an emollient. *Eur J Dermatol EJD.* 2013;23(2):189-194. doi:10.1684/ejd.2013.1987
23. Koc F, Eren MG, Sert H. Comparing the Efficacy of Zinc Oxide Versus Barrier Creams for Pressure Injury Prevention: A Retrospective Cross-sectional Study. *Adv Skin Wound Care.* 2023;36(12):1-6. doi:10.1097/ASW.0000000000000064
24. Mauskar MM, Marathe K, Venkatesan A, Schlosser BJ, Edwards L. Vulvar diseases. *J Am Acad Dermatol.* 2020;82(6):1277-1284. doi:10.1016/j.jaad.2019.07.115
25. Zachary C, Fackler N, Juhasz M, Pham C, Mesinkovska NA. Catamenial dermatoses associated with autoimmune, inflammatory, and systemic diseases: A systematic review. *Int J Womens Dermatol.* 2019;5(5):361-367. doi:10.1016/j.iwjd.2019.09.008
26. Rimoin LP, Kwatra SG, Yosipovitch G. Female-specific pruritus from childhood to postmenopause: clinical features, hormonal factors, and treatment considerations. *Dermatol Ther.* 2013;26(2):157-167. doi:10.1111/dth.12034
27. DeMaria AL, Sundstrom B, Meier S, Wiseley A. The myth of menstruation: how menstrual regulation and suppression impact contraceptive choice. *BMC Womens Health.* 2019;19(1):125. doi:10.1186/s12905-019-0827-x
28. American College of Obstetricians and Gynecologists' Committee on Clinical Consensus—Gynecology. General Approaches to Medical Management of Menstrual Suppression: ACOG Clinical Consensus No. 3. *Obstet Gynecol.* 2022;140(3):528-541. doi:10.1097/AOG.0000000000004899
29. Peterson MY, Warshaw E. Going Green and Adhesive-Free: Snap-in Reusable Menstrual Pads for Tampon and Pad Intolerance. *Dermatitis®.* 2023;34(1):60-61. doi:10.1089/DERM.0000000000000898
30. Ramsay C, Hennehan J, Douglass CH, Eddy S, Head A, Lim MSC. Reusable period products: use and perceptions among young people in Victoria, Australia. *BMC Womens Health.* 2023;23(1):102. doi:10.1186/s12905-023-02197-3
31. Medina-Perucha L, López-Jiménez T, Holst AS, et al. Use and perceptions on reusable and non-reusable menstrual products in Spain: A mixed-methods study. *PLoS One.* 2022;17(3):e0265646. doi:10.1371/journal.pone.0265646

32. Arbour M, Corwin EJ, Salsberry P. Douching patterns in women related to socioeconomic and racial/ethnic characteristics. *J Obstet Gynecol Neonatal Nurs JOGNN*. 2009;38(5):577-585. doi:10.1111/j.1552-6909.2009.01053.x
33. Van der Veer C, Bruisten SM, van Houdt R, et al. Effects of an over-the-counter lactic-acid containing intra-vaginal douching product on the vaginal microbiota. *BMC Microbiol*. 2019;19(1):168. doi:10.1186/s12866-019-1545-0
34. Hesham H, Mitchell AJ, Bergerat A, Hung K, Mitchell CM. Impact of vaginal douching products on vaginal Lactobacillus, Escherichia coli and epithelial immune responses. *Sci Rep*. 2021;11(1):23069. doi:10.1038/s41598-021-02426-5
35. Edwards D, Panay N. Treating vulvovaginal atrophy/genitourinary syndrome of menopause: how important is vaginal lubricant and moisturizer composition? *Climacteric J Int Menopause Soc*. 2016;19(2):151-161. doi:10.3109/13697137.2015.1124259
36. Dezzutti CS, Brown ER, Moncla B, et al. Is wetter better? An evaluation of over-the-counter personal lubricants for safety and anti-HIV-1 activity. *PLoS One*. 2012;7(11):e48328. doi:10.1371/journal.pone.0048328
37. Brown JM, Hess KL, Brown S, Murphy C, Waldman AL, Hezareh M. Intravaginal Practices and Risk of Bacterial Vaginosis and Candidiasis Infection Among a Cohort of Women in the United States. *Obstet Gynecol*. 2013;121(4):773-780. doi:10.1097/AOG.0b013e31828786f8
38. Potter N, Panay N. Vaginal lubricants and moisturizers: a review into use, efficacy, and safety. *Climacteric J Int Menopause Soc*. 2021;24(1):19-24. doi:10.1080/13697137.2020.1820478
39. Huang AJ, Grady D. Rethinking the Approach to Managing Postmenopausal Vulvovaginal Symptoms. *JAMA Intern Med*. 2018;178(5):690-691. doi:10.1001/jamainternmed.2018.0094
40. Mitchell CM, Reed SD, Diem S, et al. Efficacy of Vaginal Estradiol or Vaginal Moisturizer vs Placebo for Treating Postmenopausal Vulvovaginal Symptoms: A Randomized Clinical Trial. *JAMA Intern Med*. 2018;178(5):681-690. doi:10.1001/jamainternmed.2018.0116
41. The 2020 genitourinary syndrome of menopause position statement of The North American Menopause Society. *Menopause*. 2020;27(9):976-992. doi:10.1097/GME.0000000000001609
42. Burrows LJ, Goldstein AT. The treatment of vestibulodynia with topical estradiol and testosterone. *Sex Med*. 2013;1(1):30-33. doi:10.1002/sm2.4
43. Gardella B, Iacobone AD, Porru D, et al. Effect of local estrogen therapy (LET) on urinary and sexual symptoms in premenopausal women with interstitial cystitis/bladder pain syndrome (IC/BPS). *Gynecol Endocrinol Off J Int Soc Gynecol Endocrinol*. 2015;31(10):828-832. doi:10.3109/09513590.2015.1063119
44. Mitchell L, Govind V, Barela K, Goldstein AT. Spironolactone May be a Cause of Hormonally Associated Vestibulodynia and Female Sexual Arousal Disorder. *J Sex Med*. 2019;16(9):1481-1483. doi:10.1016/j.jsxm.2019.06.012
45. Tordoff DM, Lunn MR, Chen B, et al. Testosterone use and sexual function among transgender men and gender diverse people assigned female at birth. *Am J Obstet Gynecol*. 2023;229(6):669.e1-669.e17. doi:10.1016/j.ajog.2023.08.035
46. Shiplo S, Sivajohan B, Selk A. A Comparison of Lichen Sclerosus and Vulvodynia Content Across Social Media Platforms: What Is Trending Over Time. *J Low Genit Tract Dis*. 2024;28(1):95-100. doi:10.1097/LGT.0000000000000782
47. Luu Y, Admani S. Vulvar allergens in topical preparations recommended on social media: a cross-sectional analysis of Facebook groups for lichen sclerosus. *Int J Women's Dermatol*. 2023;9(3):e097. doi:10.1097/JW9.000000000000097

# Psychosexual and pelvic floor health

*Julieta Vera, Katrina Bouchard, Jaclyn Lanthier, Carson Judkins, Sonali Patel, Amy Stein, Claudia Marchitelli*

**S**exual and psychological impacts are common in patients with vulvar LS. Vulvar clinicians must develop a range of techniques to open the conversation, identify specific concerns, undertake targeted history and examination, and offer an initial therapeutic plan. Involvement of a multidisciplinary team of physicians, psychologists, sex therapists, and physiotherapists likely improves function and quality of life (QoL) in women with LS and psychosexual issues.

## Sexual impacts

The biopsychosocial approach to sexual health recognizes that sexual function is affected by biologic, psychologic, interpersonal, and sociocultural factors that interact and change over time.<sup>1</sup> The prevalence of sexual dysfunction in women with LS is over 50%, most often manifesting as sexual pain, less frequent sexual activity, and lower sexual satisfaction.<sup>2-4</sup> Biologic contributions to pain include loss of tissue elasticity, tearing at the posterior fourchette, and introital narrowing. Discomfort may not be alleviated by surgeries that address these anatomic changes (see Chapter 12).<sup>5,6</sup> Patients with LS commonly face other personally distressing sexual difficulties to include low sexual desire, diminished arousal, and lack of orgasm.<sup>7-10</sup>

Clinician inquiry into sexual health concerns is welcomed by most patients.<sup>11</sup> This begins with taking a supportive, culturally sensitive, trauma-informed sexual history.<sup>12</sup> The use of gender-neutral language and a sex-positive approach lays the groundwork for discussions perceived as fruitful and non-judgmental. The terms ‘cultural safety’ and ‘cultural humility’ have replaced the concept of cultural competence, reflecting that providers cannot be knowledgeable about all cultures and intersectional identities, but can recognize their own biases and strive to learn from and collaborate with patients.<sup>12</sup> Trauma-informed care recognizes the endemic nature of violence and abuse, assumes all patients may be affected, and promotes explanation of exams, consent, boundary setting, and support mechanisms (see Chapter 3).<sup>13</sup> Two ways of opening the conversation are “Is it okay if I ask you some questions about your sexual health?” and “Do you have any concerns about your sexual health today?” Depending on the response and clinical situation, further discussion may address the 5P

framework of partners, practices, protection from sexually transmitted infections (STI), past history, and pregnancy intention.<sup>14</sup> Phrases like ‘high-risk’ may be replaced with less stigmatizing words like ‘increased chance’ or ‘more vulnerable.’ The 5P framework is less relevant for some women with vulvar dermatoses, whose concerns instead may center on relationship issues, genital self-image, or relieving sexual discomfort.

The PLISSIT model provides a sensitive and effective model for addressing sexual wellbeing during a clinical encounter. The acronym stands for Permission, Limited Information, Specific Suggestions, and Intensive Therapy.<sup>15</sup> The first step involves normalizing the topic of sexual health and providing a safe space for further discussion. The clinician provides information about types of sexual dysfunction and aims to identify issues of desire, arousal, orgasm, and/or pain. Suggestions might include vulvovaginal care advice, discussion of lubricants and sex toys, topical hormonal medications, and pelvic floor physiotherapy (see Chapter 7). Optimizing topical corticosteroid treatment of LS aids in sexual comfort (see Chapter 6). Patients with LS may require reassurance that silicone- and oil-based lubricants are safe for them and clitoral stimulation with a vibrator may mitigate reduced sensitivity resulting from architectural change. A small pilot study showed improvement in skin appearance in patients with LS who used vibrators.<sup>16</sup> If clinically indicated, providers may recommend involvement of a sex therapist, psychologist, or sexual medicine specialist.

Clinicians may wish to adopt a standardized tool for assessment of QoL and sexual wellbeing. There is no consensus among vulvar experts regarding a preferred questionnaire.<sup>17,18</sup> The Dermatology Life Quality Index (DLQI) measures the impact of the skin disease on different life domains, addressing symptoms and treatment response.<sup>19</sup> The Vulvar Quality of Life Index (VQLI) has fifteen questions specifically focusing on vulvar disease and includes symptoms, emotions, impacts on relationships, sexual function, impacts on daily living, and concerns about the future and treatment.<sup>20</sup> The Female Sexual Functioning Index (FSFI) consists of 19 questions across six domains of sexual function: sexual desire, sexual arousal, lubrication, orgasm, satisfaction, and pain.<sup>21</sup> The World Health Organization Five-Item Well-being Index is a short generic global rating scale for subjective well-being.<sup>22</sup> The Core Outcomes Set for Research in Lichen Sclerosus (CORALS) project aims to gain consensus on a measurement tool for QoL and sexual impacts to improve quality in interventional research and indirectly standardize routine care.<sup>23</sup>

## **Sex therapy, cognitive behavioral therapy, and mindfulness-based therapy**

Sex therapy is a form of psychotherapy or counseling aimed at helping individuals and couples resolve or cope with sexual difficulties.<sup>24</sup> Sex therapy often encompasses cognitive behavioral therapy (CBT) or mindfulness-based therapy (MBT) delivered to individuals or groups.<sup>25</sup> The principle of CBT is to challenge unhelpful thoughts, beliefs, and behaviors to increase adaptive coping and reduce emotional distress.<sup>26</sup> The aim of MBT is to help individuals cultivate non-judgmental awareness of the present moment, often through the practice of mindfulness meditation.<sup>27,28</sup> This approach emerged as a third wave of CBT that promoted an acceptance-oriented strategy for managing symptoms.<sup>29</sup>

Few studies examine sex therapy for LS, so its potential impact is extrapolated from studies of sexual dysfunction. Meta-analyses show that psychological interventions reduce symptoms and distress in women with sexual pain, arousal, and/or orgasm disorders.<sup>30-32</sup> In women with vulvodynia, CBT is similarly effective to electromyographic biofeedback and more effective than topical lidocaine or hydrocortisone for a range of sexual and psychological outcomes.<sup>33-35</sup> Compared to CBT in vulvodynia patients, group MBT provides greater reduction of insertional pain and similar improvements in other psychosexual outcomes.<sup>36</sup> Among patients with female sexual interest/arousal disorders, group supportive sex education versus MBT provide similar improvements in sexual desire, arousal, as well as reductions in distress and rumination.<sup>29</sup> To date, there is one published study examining sex therapy for LS. This randomized controlled trial (RCT) assessed psychosexual counseling versus usual care in 158 women with LS. The intervention included up to 8 sessions with a sex therapist that addressed psychosexual education, sensate focus, relaxation skills, and desensitization.<sup>37</sup> Both groups experienced improvement in sexual function, but the counseling intervention yielded higher DLQI and FSFI scores. Women who attended sessions with their partner had even greater improvements, highlighting the importance of couple or interpersonal factors in sexual wellbeing.

## Comorbid depression and anxiety

There are high rates of anxiety and depression in those with LS. Many mental health screening tools exist for clinical care but none are specifically recommended for women with LS. Two simple and widely accepted systems are the Patient Health Questionnaire (PHQ-9) and General Anxiety Disorder Scale (GAD-7). The PHQ-9 and GAD-7 screen for symptoms of depression and anxiety in the prior 2 weeks with response options being not at all, several days, more than half the days, or nearly every day. The PHQ-9 assesses self-harm thoughts, anhedonia, hopelessness, guilt, inability to concentrate, and disturbance in sleep, appetite, and activity. A score less than 5/27 indicates absence of depression and 15 or greater suggests moderately severe depression. The GAD-7 asks about feeling nervous, persistent or multi-subject worry, inability to relax, restlessness, irritability, and sense of impending doom. A score less than 4/21 excludes anxiety while 15 or greater indicates severe anxiety. These PHQ-9 AND GAD-7 have been combined into the PHQ-Anxiety and Depression Scale (PHQ-ADS).<sup>38</sup>

While studies are not specific to LS-associated depression, psychotherapy is efficacious for treating emotional distress secondary to physical health concerns.<sup>39,40</sup> For those diagnosed with major depressive disorder, the mainstays of treatment are psychotherapy and antidepressants.<sup>41</sup> Psychotherapy may be twice as effective as medication for anxiety disorder.<sup>42</sup> If cost poses a barrier to accessing individual psychotherapy, group-based psychotherapy or online modules may be a more affordable treatment option for depression and anxiety.<sup>43</sup> Vulvar clinicians may need to highlight the patient's mental health concerns to an involved primary care provider and become familiar with local referral options.

The most common reason for discontinuation of antidepressants is sexual side effects, including low libido (72%), diminished arousal (83%), and difficulty reaching orgasm (40%) in

women on SSRIs.<sup>44</sup> Sexual side effects often occur in the first 1-3 weeks of use while mood benefits take 4-6 weeks to appear, potentially leading to early discontinuation.<sup>45</sup> Screening for sexual dysfunction prior to medication initiation and managing expectations may mitigate this issue.<sup>44</sup> Clinicians prescribing medication for depression or anxiety can ask “How has your sexual life been since starting the medication?” to increase the chance of disclosure. Sexual desire or arousal problems may be addressed by lowering the dose or changing to a non-serotonergic drug, while orgasm difficulties may be managed with dose-reduction, weekend holidays, or switching to fluvoxamine, mirtazapine, or bupropion.<sup>46</sup>

## Psychological and interpersonal factors

For some women with LS, the condition leads to feelings of shame, embarrassment, grief, and insecurity about sexual relationships.<sup>18</sup> It can be a ‘lonely and isolating condition’ as many women keep their diagnosis a secret due to stigma and lack of community awareness about genital conditions.<sup>47</sup> Two qualitative studies document that women with LS and other inflammatory dermatoses may feel it is socially inappropriate to discuss their diagnosis with family, friends, and partners.<sup>47,48</sup> The changes in vulvar anatomy, appearance, and function may be associated with negative impacts on self-image, body confidence, and sense of femininity.<sup>47,48</sup> A qualitative study of 19 Dutch women with LS investigated motives for LS-related surgery and observed 3 themes: the desire to be a ‘normal’ woman, to sexually satisfy a male partner, and to regain intimacy and sexual enjoyment.<sup>49</sup> A content analysis of 527 online LS forum posts similarly highlighted concerns about diminished femininity and losing a partner due to their condition.<sup>50</sup> These feelings have broad impacts on psychosocial functioning, with some women reporting avoidance of dating due to fear of disclosing LS to a prospective sexual partner.<sup>48</sup> Interventions grounded in CBT and aimed at illness-related distress may help patients to challenge negative thoughts about their identity as a desirable partner and address avoidance behaviors to improve overall psychosexual function.<sup>51</sup>

Genital self-image describes an individual’s attitudes and emotions about their genitals, related to but distinct from general body image.<sup>52,53</sup> It encompasses concerns related to genital appearance, hygiene, and function, often manifesting as concerns about vulvovaginal scent, introital capacity, vaginal lubrication, and labial color, shape, and size. This can be assessed with a brief self-report measure like the Female Genital Self-Image Scale (FGSIS).<sup>52,54</sup> In non-clinical samples, positive genital self-image is associated with better sexual function and satisfaction.<sup>53</sup> Compared to controls or those with extragenital skin conditions, women with LS have poorer genital self-image and this is associated with reduced sexual function.<sup>10,55,56</sup> LS treatment does not reliably alter FGSIS scores, but may be modifiable with psychological therapy.<sup>55</sup>

## Pelvic health physiotherapy

Pelvic health physiotherapy (PT) is an effective, minimally invasive, first-line treatment for many pelvic floor disorders, including pelvic pain and dyspareunia.<sup>57,58</sup> Pelvic PT is a general term for instruction by a physiotherapist in pelvic muscle strengthening, relaxation, and coordination exercises. It may involve manual therapy, biofeedback, electrical stimulation,

behavioral and pain science education, therapeutic exercise, and individualized home activity programs, unique to each patient's condition.<sup>57</sup> Treatment is aimed at improving patients' bodily awareness and understanding the function of their pelvic and perineal structures. A systematic review showed various pelvic PT interventions improve vulvodynia, sexual function, and QoL.<sup>59</sup>

The clinical encounter begins with a holistic history of general medical, musculoskeletal, sexual, bowel, and bladder issues, often incorporating validated questionnaires. This process helps to define the patient's concerns and treatment goals. Examination includes general assessment of abdominopelvic and lumbosacral function, to include stance, gait, posture, sitting position abnormalities, presence of diastasis recti, core muscle asymmetry or deconditioning, and muscular activity imbalances. Vulvar examination identifies discomfort, scar, reduced introital dimensions, and overactivity of the pubococcygeus muscle. Internal examination evaluates for tenderness and tightness of the levator ani and hip rotator muscles, bony structures, and ligamentous connections. The physiotherapist uses this holistic assessment to generate an individualized treatment plan to provide lasting functional improvements.<sup>60</sup>

Education and behavioral modifications are a major component of the therapeutic approach. General lifestyle advice often addresses nutrition, sleep, physical activity, and diaphragmatic breathing practice. The physiotherapist may provide ergonomic and postural advice tailored to the individual's work setting and lifestyle. Detailed guidance about bowel and bladder health includes voiding positions, use of a footstool for defecation, mechanisms for sphincter relaxation and closure, and avoidance of straining.<sup>61,62</sup> Physiotherapists review vulvar care advice and effective hygiene practices.<sup>63</sup> When chronic pain is identified in the initial assessment, physiotherapists provide education about pain science and the cycle of protective muscle guarding that produces further discomfort. This may be addressed through nervous system down-training techniques like diaphragmatic breathing, vagus nerve stimulation, visualization, and mindfulness.

Physiotherapists may prescribe a suite of exercises to improve balance and flexibility and achieve lengthening or strengthening at targeted muscle groups.<sup>64</sup> Core exercises that are often advised and modified by physiotherapists include transverse abdominis isometric contractions, pelvic tilts, oblique crunches, bridging, quadruped with opposite arm and leg raise, hip external and internal rotation exercises, squats, pelvic floor exercises, and planks. Pelvic floor relaxation techniques are essential to management of abdominopelvic and sexual pain. Common positions advised for pelvic floor relaxation are the child pose, single knee to chest, butterfly pose with knee support, and deep squat with under-buttock block support.<sup>65</sup>

Manual therapy is what distinguishes physiotherapy from other treatment approaches. Palpation allows clinicians to localize and treat biomechanical impairments and myofascial restrictions. Pelvic floor physiotherapists undertake additional training to enable both external and internal therapy that aims to rehabilitate the pelvic floor muscles and restore neuromobility. Manual therapy enables skilled stretching and mobilization of associated joints.<sup>66</sup> It involves proprioceptive neuromuscular facilitation through contract/relax and reciprocal



inhibition work. The physiotherapist guides active release and other muscle energy techniques to facilitate muscle relaxation and lengthening. A combination of myofascial release and paradoxical relaxation techniques provided a 72% moderate to marked improvement in patients with chronic pelvic pain.<sup>67</sup> Graded exposure techniques with patient-led activities and manual therapies achieve a decrease in fear, increase in blood flow, and increased tolerance to palpation.

Mobilization and massage techniques can help decrease sensitivity, pain, and restriction in areas of adhesion from LS or previous surgery. Palpation over an area of scar may be sustained or applied in a circular fashion, with gradual increase in pressure over time as the patient's pain perception decreases. Myofascial release is a technique of applying manual shortening or lengthening forces around scar tissue to enhance mobility. Cross friction massage applies perpendicular pressure along the length of a scar to help with remodeling of the tissue. There are no studies specific to LS, but a study of burn patients with hypertrophic scars showed significant improvement in skin distensibility and color after scar mobilization techniques.<sup>68,69</sup> Another study in a burn cohort showed improvements in itch, pain, mood, and anxiety after a single session of scar massage therapy.<sup>70</sup> Patients with scar after breast cancer surgery reported improved pain, mobility, and function after myofascial release therapy.<sup>71</sup>

Dilators, therapeutic wands, and vibrators also may aid in pelvic floor retraining and confidence-building in vulvovaginal function. Gradual increase of dilator diameter over time allows for gentle introital stretch, vaginal lengthening, and reduction in pelvic floor muscle tension. This activity is entirely under the woman's control, aiding in anxiety reduction and the practice of nervous system down-training techniques.<sup>72,73</sup> Dilation is also essential to prevent recurrence after surgery to address LS-related adhesions (see Chapter 12). Dilators and therapeutic wands may be used for self-directed management of painful tense pelvic floor muscles. Placement of a dilator or wand also provides muscular proprioception during PT exercises, potentially augmenting pelvic floor contraction and relaxation. Vibrators can be used across the lower anogenital tract to facilitate tissue relaxation and desensitization, clitoral stimulation, and sexual arousal.<sup>16</sup> Physiotherapists may instruct patients in a suite of approaches to incorporate into daily life at home.

Biofeedback is a technique based on provision of instantaneous performance-dependent visual and/or auditory feedback. Equipment records muscular contraction and relaxation and signals the patient through visual or auditory cues so she can learn to control disordered muscle activity patterns.<sup>74</sup> This helps patients gain awareness of pelvic floor function through identifying muscle location, activity, and guarding reactions to discomfort.

Electrical stimulation applied in various waveforms may be used externally and internally at the pelvis to improve proprioception, enhance contractile function, and/or decrease pain sensitization.<sup>75</sup> Transcutaneous electrical nerve stimulation (TENS) is the application of mild electrical stimulation using skin electrodes near or distant to a painful site to interfere with transmission of painful stimuli. Several RCTs found TENS to be effective in the treatment of localized provoked vulvodynia.<sup>76,77</sup>

## Limitations of the literature

While multiple studies document the profound psychosexual impacts of LS, scant research assesses therapeutic approaches to this problem. Sex therapy grounded in CBT and MBT is effective in managing sexual dysfunction and genital pain syndromes and this benefit likely extrapolates to LS. Research assessing the interpersonal and relationship aspects of LS may provide insights into more effective psychotherapeutic programs. Continued work on the QoL domain of LS-related core outcome sets may yield consensus about preferred validated questionnaires, enhancing consistency across studies and the ability to undertake subsequent meta-analyses. Demonstration of the benefits of pelvic PT for women with LS may highlight the utility of multidisciplinary care and further the argument for enhanced access to and funding of physiotherapy for vulvar conditions.

## Conclusions and recommendations

Sexual and psychological impacts of lichen sclerosus are common. Holistic LS care addresses sexual health concerns, genital self-image, anxiety, depression, and feelings of shame and isolation. Open-ended non-judgmental questions, validated questionnaires, and the PLISSIT model aid clinicians in identifying and validating psychosexual problems and initiating a therapeutic strategy. This often involves referral to other health professionals like psychologists, sex therapists, physiotherapists, sexual medicine specialists, or psychiatrists.

- Patient-centered sexual history-taking incorporates use of gender-neutral language and trauma-informed principles, respects varied cultural approaches to sex, conveys a positive framing of sexuality, and reassures patients that sexual concerns are common in people with LS.
- Provision of specific suggestions around behavioral changes, vulvovaginal care, inter-partner communication, and sexual aids validates patients' concerns and empowers them to work towards their sexual goals.
- Cognitive behavioral and mindfulness-based therapies may help to address sexual concerns and emotional distress arising in the context of LS.
- Pelvic floor physiotherapy is an effective modality to address sexual, genital, and pelvic pain.
- Vulvar clinicians should develop a referral network of health professionals across multiple fields who share an interest in addressing psychosexual concerns of patients with LS.

## References

1. Thomas HN, Thurston RC. A biopsychosocial approach to women's sexual function and dysfunction at midlife: A narrative review. *Maturitas*. 2016;87:49-60. doi:10.1016/j.maturitas.2016.02.009
2. Pope R, Lee MH, Myers A, et al. Lichen Sclerosus and Sexual Dysfunction: A Systematic Review and Meta-Analysis. *The Journal of Sexual Medicine*. 2022;19(11):1616-1624. doi:10.1016/j.jsxm.2022.07.011
3. Caspersen IS, Højgaard A, Laursen BS. The influence of lichen sclerosus on women's sexual health from a biopsychosocial perspective: a mixed methods study. *J Sex Med*. 2023;20(4):488-497. doi:10.1093/jsxmed/qdad018
4. Haefner HK, Aldrich NZ, Dalton VK, et al. The impact of vulvar lichen sclerosus on sexual dysfunction. *J Womens Health (Larchmt)*. 2014;23(9):765-770. doi:10.1089/jwh.2014.4805
5. Krapf JM, Mitchell L, Holton MA, Goldstein AT. Vulvar Lichen Sclerosus: Current Perspectives. *Int J Womens Health*. 2020;12:11-20. doi:10.2147/IJWH.S191200

6. Lauber F, Vaz I, Krebs J, Günthert AR. Outcome of perineoplasty and de-adhesion in patients with vulvar Lichen sclerosus and sexual disorders. *Eur J Obstet Gynecol Reprod Biol.* 2021;258:38-42. doi:10.1016/j.ejogrb.2020.12.030
7. Corazza M, Virgili A, Minghetti S, Borghi A. Dyspareunia in vulvar lichen sclerosus: an overview of a distressing symptom. *G Ital Dermatol Venereol.* 2020;155(3). doi:10.23736/S0392-0488.17.05849-7
8. Krapf J, Mautz T, Lorenzini S, Holloway J, Goldstein A. Clinical Presentation of Clitorodinia Associated with Clitoral Adhesions and Keratin Pearls. *The Journal of Sexual Medicine.* 2022;19(Supplement\_3):S14-S14. doi:10.1016/j.jsxm.2022.05.032
9. Smith AB, Muhammad NI, Cigna ST, Krapf JM. A systematic review of sexual health consequences among women with lichen sclerosus. *Sexual Medicine Reviews.* 2023;11(1):8-14. doi:10.1093/sxmrev/qeac002
10. Yildiz Ş, Cengiz H, Kaya C, et al. Evaluation of genital self-image and sexual dysfunction in women with vulvar lichen planus or lichen sclerosus. *Journal of Psychosomatic Obstetrics & Gynecology.* 2022;43(2):99-106. doi:10.1080/0167482X.2020.1857359
11. Ryan KL, Arbuckle-Bernstein V, Smith G, Phillips J. Let's Talk About Sex: A Survey of Patients' Preferences When Addressing Sexual Health Concerns in a Family Medicine Residency Program Office. *PRIMER.* 2018;2:23. doi:10.22454/PRIMER.2018.728252
12. Hong D, Cherabie J, Reno HE. Taking a Sexual History: Best Practices. *Med Clin North Am.* 2024;108(2):257-266. doi:10.1016/j.mcna.2023.09.004
13. Gorfinkel I, Perlow E, Macdonald S. The trauma-informed genital and gynecologic examination. *CMAJ.* 2021;193(28):E1090-E1090. doi:10.1503/cmaj.210331
14. National Center for HIV/AIDS, Viral Hepatitis, STD, and TB Prevention (U.S.). A Guide to taking a sexual history. Published online August 5, 2021. Accessed July 31, 2024. <https://stacks.cdc.gov/view/cdc/108651>
15. Annon JS. The PLISSIT Model: A Proposed Conceptual Scheme for the Behavioral Treatment of Sexual Problems. *Journal of Sex Education and Therapy.* 1976;2(1):1-15. doi:10.1080/01614576.1976.11074483
16. Dubinskaya A, Kohli P, Shoureshi P, et al. The Role of Vibrators in Women's Pelvic Health: An Alluring Tool to Improve Physical, Sexual, and Mental Health. *Int Urogynecol J.* 2024;35(5):1085-1092. doi:10.1007/s00192-024-05775-7
17. De Luca DA, Papara C, Vorobyev A, et al. Lichen sclerosus: The 2023 update. *Front Med (Lausanne).* 2023;10:1106318. doi:10.3389/fmed.2023.1106318
18. Vittrup G, Mørup L, Heilesen T, Jensen D, Westmark S, Melgaard D. Quality of life and sexuality in women with lichen sclerosus: a cross-sectional study. *Clin Exp Dermatol.* 2022;47(2):343-350. doi:10.1111/ced.14893
19. Finlay AY, Khan GK. Dermatology Life Quality Index (DLQI)—a simple practical measure for routine clinical use. *Clin Exp Dermatol.* 1994;19(3):210-216. doi:10.1111/j.1365-2230.1994.tb01167.x
20. Saunderson RB, Harris V, Yeh R, Mallitt KA, Fischer G. Vulvar quality of life index (VQLI) - A simple tool to measure quality of life in patients with vulvar disease. *Australas J Dermatol.* 2020;61(2):152-157. doi:10.1111/ajd.13235
21. Rosen R, Brown C, Heiman J, et al. The Female Sexual Function Index (FSFI): a multidimensional self-report instrument for the assessment of female sexual function. *J Sex Marital Ther.* 2000;26(2):191-208. doi:10.1080/009262300278597
22. Topp CW, Østergaard SD, Søndergaard S, Bech P. The WHO-5 Well-Being Index: a systematic review of the literature. *Psychother Psychosom.* 2015;84(3):167-176. doi:10.1159/000376585
23. Simpson RC, Kirtschig G, Selk A, et al. Core outcome domains for lichen sclerosus: a CORALS initiative consensus statement. *Br J Dermatol.* 2023;188(5):628-635. doi:10.1093/bjd/ljac145
24. International Society for Sexual Medicine. What happens during sex therapy. Accessed July 31, 2024. <https://www.issm.info/sexual-health-qa/what-happens-during-sex-therapy>
25. Hall KSK, Binik YM, eds. *Principles and Practice of Sex Therapy.* Sixth edition. The Guilford Press; 2020.
26. Rector, N. *Cognitive-Behavioural Therapy: An Information Guide.* Centre for Addiction and Mental Health; 2010.
27. Bishop SR, Lau M, Shapiro S, et al. Mindfulness: A proposed operational definition. *Clinical Psychology: Science and Practice.* 2004;11(3):230-241. doi:10.1093/clipsy.bph077
28. Shamblaw AL, Segal Z. Mindfulness meditation in the long-term management of mood disorders: Contributions by Canadian researchers. *Canadian Journal of Behavioural Science / Revue canadienne des sciences du comportement.* 2022;54(2):142-151. doi:10.1037/cbs0000286
29. Brotto LA, Zdaniuk B, Chivers ML, et al. A randomized trial comparing group mindfulness-based cognitive therapy with group supportive sex education and therapy for the treatment of female sexual interest/arousal disorder. *Journal of Consulting and Clinical Psychology.* 2021;89(7):626-639. doi:10.1037/ccp0000661
30. Banbury S, Lusher J, Snuggs S, Chandler C. Mindfulness-based therapies for men and women with sexual dysfunction: a systematic review and meta-analysis. *Sexual and Relationship Therapy.* 2023;38(4):533-555. doi:10.1080/14681994.2021.1883578

31. Frühauf S, Gerger H, Schmidt HM, Munder T, Barth J. Efficacy of Psychological Interventions for Sexual Dysfunction: A Systematic Review and Meta-Analysis. *Arch Sex Behav*. 2013;42(6):915-933. doi:10.1007/s10508-012-0062-0
32. Günzler C, Berner MM. Efficacy of Psychosocial Interventions in Men and Women with Sexual Dysfunctions—A Systematic Review of Controlled Clinical Trials. *The Journal of Sexual Medicine*. 2012;9(12):3108-3125. doi:10.1111/j.1743-6109.2012.02965.x
33. Bergeron S, Binik YM, Khalifé S, et al. A randomized comparison of group cognitive-behavioral therapy, surface electromyographic biofeedback, and vestibulectomy in the treatment of dyspareunia resulting from vulvar vestibulitis. *Pain*. 2001;91(3):297-306. doi:10.1016/S0304-3959(00)00449-8
34. Bergeron S, Khalifé S, Glazer HI, Binik YM. Surgical and Behavioral Treatments for Vestibulodynia: Two-and-One-Half-Year Follow-up and Predictors of Outcome. *Obstetrics & Gynecology*. 2008;111(1):159-166. doi:10.1097/01.AOG.0000295864.76032.a7
35. Bergeron S, Khalifé S, Dupuis MJ, McDuff P. A randomized clinical trial comparing group cognitive-behavioral therapy and a topical steroid for women with dyspareunia. *Journal of Consulting and Clinical Psychology*. 2016;84(3):259-268. doi:10.1037/ccp0000072
36. Brotto LA, Bergeron S, Zdaniuk B, et al. A Comparison of Mindfulness-Based Cognitive Therapy Vs Cognitive Behavioral Therapy for the Treatment of Provoked Vestibulodynia in a Hospital Clinic Setting. *The Journal of Sexual Medicine*. 2019;16(6):909-923. doi:10.1016/j.jsxm.2019.04.002
37. Vittrup G, Westmark S, Riis J, et al. The Impact of Psychosexual Counseling in Women With Lichen Sclerosus: A Randomized Controlled Trial. *J Low Genit Tract Dis*. 2022;26(3):258-264. doi:10.1097/LGT.0000000000000669
38. Kroenke K, Wu J, Yu Z, et al. Patient Health Questionnaire Anxiety and Depression Scale: Initial Validation in Three Clinical Trials. *Psychosom Med*. 2016;78(6):716-727. doi:10.1097/PSY.0000000000000322
39. Vlachou E, Ntikoudi A, Owens DA, Nikolakopoulou M, Chalimourdas T, Cauli O. Effectiveness of cognitive behavioral therapy-based interventions on psychological symptoms in adults with type 2 diabetes mellitus: An update review of randomized controlled trials. *Journal of Diabetes and its Complications*. 2022;36(5):108185. doi:10.1016/j.jdiacomp.2022.108185
40. Kimber JM, Ertl MM, Egli MR, Brenner RE. Psychotherapies for clients with physical health conditions: A scoping review of demographic reporting. *Psychotherapy*. 2022;59(2):209-222. doi:10.1037/pst0000397
41. Gartlehner G, Wagner G, Matyas N, et al. Pharmacological and non-pharmacological treatments for major depressive disorder: review of systematic reviews. *BMJ Open*. 2017;7(6):e014912. doi:10.1136/bmjopen-2016-014912
42. Carl E, Witcraft SM, Kauffman BY, et al. Psychological and pharmacological treatments for generalized anxiety disorder (GAD): a meta-analysis of randomized controlled trials. *Cognitive Behaviour Therapy*. 2020;49(1):1-21. doi:10.1080/16506073.2018.1560358
43. Bennett CB, Ruggero CJ, Sever AC, Yanouri L. eHealth to redress psychotherapy access barriers both new and old: A review of reviews and meta-analyses. *Journal of Psychotherapy Integration*. 2020;30(2):188-207. doi:10.1037/int0000217
44. Lorenz T, Rullo J, Faubion S. Antidepressant-Induced Female Sexual Dysfunction. *Mayo Clinic Proceedings*. 2016;91(9):1280-1286. doi:10.1016/j.mayocp.2016.04.033
45. Gelenberg AJ, Dunner DL, Rothschild AJ, Pedersen R, Dorries KM, Ninan PT. Sexual Functioning in Patients With Recurrent Major Depressive Disorder Enrolled in the PREVENT Study. *Journal of Nervous & Mental Disease*. 2013;201(4):266-273. doi:10.1097/NMD.0b013e318288d298
46. Montejo A, Prieto N, De Alarcón R, Casado-Espada N, De La Iglesia J, Montejo L. Management Strategies for Antidepressant-Related Sexual Dysfunction: A Clinical Approach. *JCM*. 2019;8(10):1640. doi:10.3390/jcm8101640
47. Arnold S, Fernando S, Rees S. Living with vulval lichen sclerosus: a qualitative interview study. *British Journal of Dermatology*. 2022;187(6):909-918. doi:10.1111/bjd.21777
48. Sadownik LA, Koert E, Maher C, Smith KB. A Qualitative Exploration of Women's Experiences of Living With Chronic Vulvar Dermatoses. *J Sex Med*. 2020;17(9):1740-1750. doi:10.1016/j.jsxm.2020.06.016
49. Brauer M, van Lunsen R, Burger M, Laan E. Motives for Vulvar Surgery of Women with Lichen Sclerosus. *J Sex Med*. 2015;12(12):2462-2473. doi:10.1111/jsm.13052
50. Wehbe-Alamah H, Kornblau BL, Haderer J, Erickson J. Silent no more! The lived experiences of women with lichen sclerosus. *J Am Acad Nurse Pract*. 2012;24(8):499-505. doi:10.1111/j.1745-7599.2012.00715.x
51. Hudson JL, Moss-Morris R. Treating Illness Distress in Chronic Illness: Integrating Mental Health Approaches With Illness Self-Management. *European Psychologist*. 2019;24(1):26-37. doi:10.1027/1016-9040/a000352
52. Herbenick D, Reece M. ORIGINAL RESEARCH—OUTCOMES ASSESSMENT: Development and Validation of the Female Genital Self-Image Scale. *The Journal of Sexual Medicine*. 2010;7(5):1822-1830. doi:10.1111/j.1743-6109.2010.01728.x

53. Komarnicky T, Skakoon-Sparling S, Milhausen RR, Breuer R. Genital Self-Image: Associations with Other Domains of Body Image and Sexual Response. *J Sex Marital Ther.* 2019;45(6):524-537. doi:10.1080/0092623X.2019.1586018
54. Herbenick D, Schick V, Reece M, Sanders S, Dodge B, Fortenberry JD. The Female Genital Self-Image Scale (FGSIS): results from a nationally representative probability sample of women in the United States. *J Sex Med.* 2011;8(1):158-166. doi:10.1111/j.1743-6109.2010.02071.x
55. Hodges KR, Wiener CE, Vyas AS, Turrentine MA. The Female Genital Self-image Scale in Adult Women With Vulvar Lichen Sclerosus. *J Low Genit Tract Dis.* 2019;23(3):210-213. doi:10.1097/LGT.0000000000000481
56. Rivera S, Flood A, Dykstra C, Herbenick D, DeMaria AL. Genital Self-Image, Sexual Function, and Quality of Life Among Individuals with Vulvar and Non-Vulvar Inflammatory Dermatoses. *Arch Sex Behav.* 2022;51(8):3965-3979. doi:10.1007/s10508-022-02353-0
57. Van Reijn-Baggen DA, Han-Geurts IJM, Voorham-van Der Zalm PJ, Pelger RCM, Hagenaars-van Miert CHAC, Laan ETM. Pelvic Floor Physical Therapy for Pelvic Floor Hypertonicity: A Systematic Review of Treatment Efficacy. *Sexual Medicine Reviews.* 2022;10(2):209-230. doi:10.1016/j.sxmr.2021.03.002
58. Stein A, Sauder SK, Reale J. The Role of Physical Therapy in Sexual Health in Men and Women: Evaluation and Treatment. *Sexual Medicine Reviews.* 2019;7(1):46-56. doi:10.1016/j.sxmr.2018.09.003
59. Nascimento RP, Falsetta ML, Maurer T, Sarmiento ACA, Gonçalves AK. Efficacy of Physiotherapy for Treating Vulvodynia: A Systematic Review. *J Low Genit Tract Dis.* 2024;28(1):54-63. doi:10.1097/LGT.0000000000000787
60. Bø K. Overview of physical therapy for pelvic floor dysfunction. In: Evidence-Based Physical Therapy for the Pelvic Floor. *Elsevier*; 2007:1-8. doi:10.1016/B978-0-443-10146-5.50007-1
61. Modi RM, Hinton A, Pinkhas D, et al. Implementation of a Defecation Posture Modification Device: Impact on Bowel Movement Patterns in Healthy Subjects. *Journal of Clinical Gastroenterology.* 2019;53(3):216-219. doi:10.1097/MCG.0000000000001143
62. Faubion SS, Shuster LT, Bharucha AE. Recognition and Management of Nonrelaxing Pelvic Floor Dysfunction. *Mayo Clinic Proceedings.* 2012;87(2):187-193. doi:10.1016/j.mayocp.2011.09.004
63. Chen Y, Bruning E, Rubino J, Eder SE. Role of female intimate hygiene in vulvovaginal health: Global hygiene practices and product usage. *Womens Health (Lond Engl).* 2017;13(3):58-67. doi:10.1177/1745505717731011
64. Caneiro JP, Smith A, Bunzli S, Linton S, Moseley GL, O'Sullivan P. From Fear to Safety: A Roadmap to Recovery From Musculoskeletal Pain. *Phys Ther.* 2022;102(2):pzab271. doi:10.1093/ptj/pzab271
65. Tosun ÖÇ, Dayıcan DK, Keser İ, Kurt S, Yildirim M, Tosun G. Are clinically recommended pelvic floor muscle relaxation positions really efficient for muscle relaxation? *Int Urogynecol J.* 2022;33(9):2391-2400. doi:10.1007/s00192-022-05119-3
66. Haslam J, Laycock J, eds. Therapeutic Management of Incontinence and Pelvic Pain. *Springer London*; 2007. doi:10.1007/978-1-84628-756-5
67. Anderson RU, Wise D, Sawyer T, Chan C. Integration of myofascial trigger point release and paradoxical relaxation training treatment of chronic pelvic pain in men. *J Urol.* 2005;174(1):155-160. doi:10.1097/01.ju.0000161609.31185.d5
68. Cho YS, Jeon JH, Hong A, et al. The effect of burn rehabilitation massage therapy on hypertrophic scar after burn: A randomized controlled trial. *Burns.* 2014;40(8):1513-1520. doi:10.1016/j.burns.2014.02.005
69. Barnes SP, Ma Y, Patel B, Muthayya P. Efficacy of Massage Techniques for Hypertrophic Burn Scars – A Systematic Review of Literature. *Journal of Burn Care & Research.* Published online September 12, 2023;:irad140. doi:10.1093/jbcr/irad140
70. Kellogg JS, Field TS, Peck MS, Hernandez-Reif MS, Krugman SS, Burman IS. Postburn itching, pain, and psychological symptoms are reduced with massage therapy. *Journal of Burn Care & Rehabilitation.* 2000;021(3):189-193. doi:10.1067/mbc.2000.105087
71. Serra-Añó P, Inglés M, Bou-Catalá C, Iraola-Lliso A, Espí-López GV. Effectiveness of myofascial release after breast cancer surgery in women undergoing conservative surgery and radiotherapy: a randomized controlled trial. *Support Care Cancer.* 2019;27(7):2633-2641. doi:10.1007/s00520-018-4544-z
72. Rosenbaum TY. Pelvic floor involvement in male and female sexual dysfunction and the role of pelvic floor rehabilitation in treatment: a literature review. *J Sex Med.* 2007;4(1):4-13. doi:10.1111/j.1743-6109.2006.00393.x
73. Fisher KA. Management of dyspareunia and associated levator ani muscle overactivity. *Phys Ther.* 2007;87(7):935-941. doi:10.2522/ptj.20060168
74. Hite M, Curran T. Biofeedback for Pelvic Floor Disorders. *Clin Colon Rectal Surg.* 2021;34(1):56-61. doi:10.1055/s-0040-1714287

75. Bergeron S, Brown C, Lord MJ, Oala M, Binik YM, Khalifé S. Physical therapy for vulvar vestibulitis syndrome: a retrospective study. *J Sex Marital Ther.* 2002;28(3):183-192. doi:10.1080/009262302760328226
76. Murina F, Recalcati D, Di Francesco S, Cetin I. Effectiveness of Two Transcutaneous Electrical Nerve Stimulation (TENS) Protocols in Women with Provoked Vestibulodynia: A Randomized Controlled Trial. *Med Sci (Basel).* 2023;11(3):48. doi:10.3390/medsci11030048
77. Murina F, Bianco V, Radici G, Felice R, Di Martino M, Nicolini U. Transcutaneous electrical nerve stimulation to treat vestibulodynia: a randomised controlled trial. *BJOG.* 2008;115(9):1165-1170. doi:10.1111/j.1471-0528.2008.01803.x

# Assessment and management of non-response to topical corticosteroids

(alphabetical order)

Tania Day, Melissa Mauskar, James Scurry, Amanda Selk

**V**ulvar lichen sclerosus (LS) usually responds to topical corticosteroid therapy with prompt symptom relief and progressive improvement in skin appearance and function. A minority of patients report non-response or exacerbation with topical steroids. There are myriad and often overlapping reasons for this. Clinicians undertake a systematic and stepwise approach to identifying causes and contributors to steroid non-response to formulate a management plan (Fig 1).

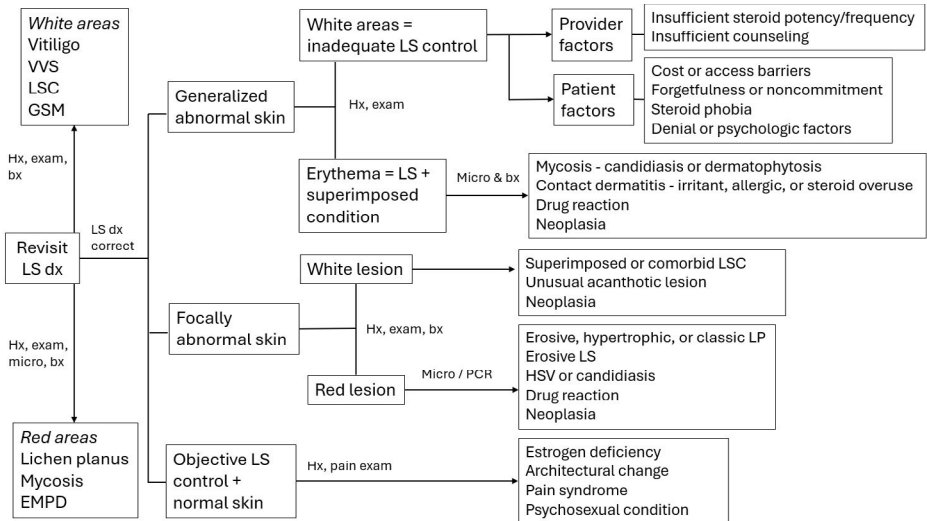


FIGURE 1. An algorithmic approach to non-response to topical steroids

## Revisiting the original diagnosis

An incorrect diagnosis of LS may be the reason for non-response to topical steroids. Review of the history and thorough re-examination are the first steps in diagnostic reappraisal. Lichen sclerosus does not cause abnormal discharge, shooting vaginal pain, dysmenorrhea, or abdominopelvic pain (see Chapter 2). A reliable clinical diagnosis of LS requires presence of white color change at commonly affected structures of the periclititoris, labia minora, interlabial sulci, perineum, and/or perianus (see Chapter 3). Supporting features include fissures, crinkly or thickened texture, and characteristic architectural changes. When features are not typical of LS, further investigation with microscopy, microbiology, and/or histopathology is required.

Dermatologic conditions most often confused with LS include vitiligo, vestibulovaginal sclerosis (VVS), lichen simplex chronicus (LSC), lichen planus (LP), and extramammary Paget's disease (EMPD) (see Chapter 5). The first two conditions present with white color change, LSC has a gray-pink appearance, while the latter two often show a combination of red and white areas. Vitiligo is common and often concurrent with LS. It usually lacks symptoms, shows depigmentation with well demarcated borders, has no texture change, and fluoresces with ultraviolet light examination. It typically occurs over the mons pubis, outer labia majora, genitocrural folds, and buttocks, lateral to the usual location of LS. Vestibulovaginal sclerosis may present with fissures, pain, or dyspareunia, or may be asymptomatic.<sup>1,2</sup> It appears as a white well-demarcated plaque on the vagina or vestibule, often between the clitoral frenulum and urethra. The etiology is unknown and it does not respond to topical steroids or estrogen. Vitiligo and VVS are distinguishable from LS on histopathology. Genitourinary syndrome of menopause (GSM) is sometimes confused with LS due to pallor and diminution of vulvar anatomy, but its characteristic vestibular and vaginal appearance and response to topical estrogen usually eliminate it from the differential diagnosis.

The examination characteristics of LSC are thickened texture with increased skin markings over hair bearing and hairless skin, often accompanied by excoriations or erosions.<sup>3</sup> Erosive LP may result in similar architectural change to LS but appears as shiny red patches over inner labia minora and vestibule often with a white slightly raised or lacy border.<sup>4,5</sup> Pain is more characteristic of erosive LP than itch, but both may occur. Erosive LP affects non-keratinized squamous epithelium and hairless skin, while LS involves hairless and hair bearing skin.<sup>6</sup> When the two are comorbid, there is an obvious delineation located at the labia minora and posterior fourchette. Hypertrophic LP appears as ovoid red to purple plaques over the vulva and/or perianus, often accompanied by edema and maceration, and may transition at the lateral border to gray-pink lichenification.<sup>7</sup> It likewise may be comorbid with erosive LP and/or LS. Classic LP is usually a focal red, brown, or purple plaque, but may mimic LS when it affects hair follicles circumferentially at the interlabial sulci and medial labia majora.<sup>7</sup> Extramammary Paget's disease usually presents with stinging or tingling discomfort. Examination findings vary from vague focal redness to extensive bright erythema with overlying inhomogeneous reticular white macules or plaques.<sup>8</sup> Biopsy may aid in differentiating LP from LS and easily distinguishes EMPD and LS.

There are multiple potential benefits to vulvar biopsy at presentation when the clinician suspects LS. The histopathologic appearance of most LS cases is distinct, permitting definitive



diagnosis and exclusion of other entities. The pathology report documents the presence of a chronic condition and accompanies patients as they move through different medical environments. This record of diagnosis helps justify ongoing treatment once skin is normalized by topical steroid treatment by combating doubt or denial in patients, their families, and future healthcare providers.<sup>9</sup> Biopsy diagnosis improves the quality of clinical research by establishing that included patients have the condition of interest. Histopathologic confirmation of LS is the best mechanism to inform national or healthcare system databases about LS prevalence, care utilization, prognosis, and associated conditions. Perceived barriers to biopsy include time, cost, and concerns about patient discomfort and healing. However, the procedure is usually quick and straightforward using rapid-acting local anesthetic, a 3-4mm punch device, and chemical hemostasis (see Chapter 4). Near-universal biopsy of suspected LS is not feasible in all care settings, but the potential advantages may outweigh concerns around procedural risks, costs, and logistics.

## Categories of non-response to topical steroids

Lichen sclerosus manifests with symptoms, sexual concerns, quality of life (QoL) impacts, clinical signs, and potential for neoplasia. Non-response may occur in each of these domains separately, or all simultaneously. Assessment of symptoms, sexual concerns, and QoL occurs through directed history taking and use of validated questionnaire like the Vulvar Life Quality Index (VLQI) and Female Sexual Dysfunction Scale (FSDS) (see Chapter 8).<sup>10-12</sup> To date, there is no consensus-based validated scoring system for LS signs and no reliable mechanism to stratify neoplasia risk.<sup>13</sup>

Examination involves assessment of skin color, texture, and progressive architectural change to determine if LS is active or controlled. Inadequate control of LS may be generalized or localized. Focally persistent white plaques or red patches raise concern for neoplasia and require biopsy. If LS is well controlled, the clinician undertakes further evaluation to identify additional diagnoses. This may involve inspection of the oral cavity, scalp, extragenital skin, genitocrural and sub-pannus folds, and natal cleft for concurrent conditions like superinfection, LP, psoriasis, or vitiligo. Directed evaluation of pain or dyspareunia may include cotton-swab or digital testing for vestibular allodynia, speculum examination and microscopy to assess vaginal discharge, palpation of pelvic floor muscles for tightness and tenderness, and internal examination for cervical motion tenderness or abnormalities of pelvic organ mobility and size.

The differential diagnosis and management approach are determined by LS activity status and normal versus abnormal skin appearance (Fig 1). Suboptimal LS control usually results from inadequate treatment due to patient and/or provider factors. Undertreated LS may be asymptomatic or have impacts across multiple life domains. Regardless of LS control, abnormal skin appearance may signify a superimposed vulvovaginal condition. When LS is well controlled and genital skin appears otherwise normal, ongoing symptoms, sexual concerns, or diminished QoL are due to another medical or psychosexual condition.<sup>14</sup> If topical steroids are correctly titrated and other conditions excluded, less than 2% of patients have a true non-response to treatment.<sup>15</sup>

## Generalized abnormal skin – Reasons and management

### Inadequate LS control due to insufficient topical corticosteroid treatment

The commonest reason for active LS despite treatment is insufficient topical steroid reaching the skin. Patients often report improved symptoms but examination shows white to pink color, abnormal texture, fissures, purpura, or progressive architectural change. Clinical signs may take 3 to 6 months to improve with reliable use of sufficient steroid potency and frequency, and the effect persists only though continued use of a maintenance regimen.<sup>15</sup> Multiple and sometimes overlapping provider and patient issues serve as barriers to adequate initial and long-term treatment.

Provider contribution to inadequate treatment usually involves prescribing too little topical steroid for the individual's disease severity. Many publications and guidelines suggest all women with LS respond to a 3 month reducing regimen followed by twice weekly application of a potent or super-potent steroid. In practice, this is not true and fails to acknowledge the wide spectrum of LS activity. A universal standardized regimen may overtreat patients with mild LS and undertreat those with severe disease. Patients with hyperkeratosis and lichenification usually require super potent steroid ointment daily to twice daily until skin texture has improved, followed by a daily long-term maintenance regimen to prevent recurrence of these features. Clinicians must also emphasize the chronic and incurable nature of LS - if patients cease steroids, signs and symptoms will return in time.<sup>16</sup>

Clinicians sometimes provide incomplete counseling around how much steroid to apply, where to place it, and how to manipulate vulvar structures to ensure adequate treatment of the clitoris and vestibule. Use of mirrors, photographs, diagrams, and reinforcement at subsequent visits helps to convey technical aspects of steroid use. Patients often realize they have been missing an anatomic zone, typically the periclitoral or perianal areas, after the clinician demonstrates the difference in skin appearance between that region and elsewhere on the vulva. Despite a clinician's best efforts, sometimes patients reduce or cease steroid use due to misplaced advice from a pharmacist, nurse, midwife, general practitioner, or specialist in another field.<sup>17,18</sup> To counteract this phenomenon, vulvar clinicians offer preemptive warnings about comments from providers who have not examined the vulva or are inexperienced at managing LS.

Varied patient factors may contribute to inadequate steroid use. Access to and cost of treatment is a difficult barrier to mitigate, especially in countries where some steroids must be compounded as they are not commercially produced. Patients may identify price differences between steroid products and substitute a less expensive medication for the one prescribed, not realizing the two have different potencies. Forgetfulness is another common problem, particularly with once or twice weekly regimens.<sup>17,19</sup> A lower potency steroid at higher frequency may overcome this problem. Cost concerns and forgetfulness may reflect a deeper reticence regarding the treatment plan. For some, this stems from mild symptoms or minimization of the impact on daily activities. For others, reasons for non-use arise from mistrust of medical approaches or desire for a 'natural' solution. The wellness industry and online misinformation agents promote an array of diets, behavioral practices, topicals, supplements, and ingested products that purport to cure chronic conditions. While cost is the

only apparent harm of some of these panaceas, others are associated with dermatitis, medication interactions, exacerbation of other medical conditions, and progressive irreversible architectural change while pursuing ineffective remedies.

Corticosteroid phobia is widespread in lay and medical communities.<sup>17,20</sup> This often manifests as a belief that steroids ‘thin the skin’ and ‘cannot be used long-term.’<sup>18</sup> Counseling to counteract these beliefs involves a simplified explanation of the mechanisms of LS and steroid treatment. One approach is to describe how LS involves a chronic attack on the skin by white blood cells, causing a cycle of damage and repair.<sup>21</sup> Steroids work by making the white blood cells go away so the skin can heal and restore its normal texture and function.<sup>22</sup> Stopping the steroid allows the white blood cells to return and cause further damage, over time resulting in irreversible scarring and tendency towards cancer. Another way to address steroid phobia is through storytelling about other patients who were scared to use steroids but overcame their fears and regained a sense of normalcy and control. In reproductive-age women, clinicians should also highlight that topical steroids for LS are safe in pregnancy and breastfeeding (see Chapter 14).

Concurrent medical and psychologic conditions impact on adherence to treatment recommendations. Obesity, arthritis, and neurologic conditions may reduce the ability to reach the vulva with one’s fingertips (see Chapter 15). Intellectual impairment and dementia contribute to forgetfulness and incorrect application, and patient-carer interactions about genital medication placement may be complicated. Depression, anxiety, and other mental health disorders may impact on motivation, planning, and execution of regular steroid application.<sup>23</sup> Socioeconomic disadvantage, discrimination, poor health literacy, language barriers, and belief in health-related conspiracy theories contribute to unwillingness or inability to follow treatment recommendations.<sup>23</sup> Hospitalization often results in cessation of treatment due to being outside the home environment, admitting teams failing to prescribe steroid ointment, and/or lack of assistance from nursing staff in genital skin care.

Denial is a powerful contributor to treatment non-adherence. A diagnosis of LS is often the first time patients confront the concept of having a chronic condition. The overlay of LS with sexual, urinary, bowel function, and risk of malignancy combines to make this diagnosis overwhelming and distressing for many women.<sup>24</sup> Patients may believe the diagnosis is incorrect and search for alternative explanations for their symptoms and signs. Feelings of guilt or a desire to assign blame may lead women to link LS to some other exposure or life event. Bargaining behavior may involve intermittent or non-use of steroids. Clinicians can facilitate this emotional journey by identifying the grief reaction and explaining how patients often progress through stages of shock, pain, anger, and sadness before moving to acceptance and a proactive embrace of self-care.<sup>25</sup>

## **Superimposed vulvovaginal conditions**

Patients with superimposed vulvovaginal conditions often report an excellent response to treatment for a while, and then they experience a ‘flare’ that does not improve despite maintaining or increasing their steroid regimen. Examination often shows erythema, making it

difficult to assess underlying LS control. The differential diagnosis includes mycotic superinfection, contact irritant or allergic dermatitis, steroid overuse, and drug reaction. Microscopy, microbiology, and biopsy may aid in delineating the cause.

Mycotic superinfection is usually due to *Candida albicans*, but non-albicans yeast species and dermatophytes are sometimes implicated. There are four categories of vulvovaginal candidiasis (VVC) - acute, recurrent, chronic, and cutaneous.<sup>26-29</sup> Acute, recurrent, and chronic VVC are primarily vaginal conditions with varied and sometimes subtle vulvar findings. They are estrogen-dependent disorders occurring in reproductive-age women or in postmenopausal women on estrogen replacement.<sup>27,30</sup> Cutaneous candidiasis mostly affects postmenopausal women with concurrent medical disorders to include obesity, diabetes mellitus, incontinence, immunosuppression, antibiotic use, and skin occlusion. It does not require exogenous estrogen, although this serves as an exacerbating factor. Cutaneous candidiasis may affect any intertriginous area and occurs in men. Use of SGLT-2 inhibitors for diabetes treatment may result in severe relapsing candidiasis until the medication is ceased.<sup>31,32</sup> Tinea cruris has similar risk factors to cutaneous candidiasis and may produce an extensive rash with central clearing over the mons, vulva, genitocrural folds, legs, and buttocks.<sup>33</sup>

Women with LS and candidiasis usually report redness, pain, burning, and swelling, but may be asymptomatic. Abnormal discharge is a variable symptom. Patients do not find sustained relief if they increase their topical steroid frequency. Typical skin findings of recurrent and chronic VVC are vague erythema at interlabial sulci and perineum with subtle edema of periclitoral structures and labia minora. Cutaneous candidiasis is red to violaceous, often extends over labia majora and perianus, and may be accompanied by satellite lesions, follicular pustules, scale, and adherent discharge. Vulvovaginal swab sent for culture detects yeast organisms, but dermatophytes are only identified through culture of skin scrapings. Recent use of topical or oral antifungals may cause false negatives, thus a positive culture supports the diagnosis but a negative result does not exclude it. The histologic triad of subcorneal or corneal neutrophils, acanthosis, and dermal lymphocytic infiltrate suggests candidiasis, although these features also occur in psoriasis.<sup>28</sup> Fungal elements in the stratum corneum are diagnostic of mycosis, but do not distinguish between candidiasis and dermatophytosis. If clinicians miss the diagnosis and undertake 'shotgun' prescribing of antibiotics, estrogen, potent topical steroids, and/or systemic immunosuppressives, skin findings become increasingly dramatic with diffuse edema, deep red-purple color, desquamation, and ulcers, sometimes culminating in hospitalization. The limited studies of LS with mycotic superinfection describe treatment with prolonged courses of oral antifungals, with duration dependent on severity, extensiveness, and comorbidities. If provoking conditions cannot be modified, women may require ongoing antifungal maintenance therapy to prevent reinfection.<sup>28,29</sup>

Contact dermatitis is a frequent cause of persistent symptoms and abnormal skin findings despite adequate topical steroid treatment of LS. Patients experience stinging and burning, and examination shows redness, edema, or weeping. Chronic exposure to provoking agents and perpetuation of an itch-scratch cycle results in intractable itch with lichenification seen on inspection. The location of skin changes provides a clue to the irritant source. Urinary and fecal incontinence with corresponding use of pads or briefs is often unrevealed until direct

inquiry. The characteristic finding of daily pad use is thickened gray-pink skin with increased skin markings over the convex curve of labia majora. Well-intentioned but misguided hygiene practices, like pubic hair removal, bathing additives, and wet wipes, are likewise a common undisclosed culprit (see Chapter 7).<sup>34</sup> Revisiting vulvar care advice at sequential visits helps patients make gradual changes that culminate in better skin health.

Allergic contact dermatitis may occur in response to preservatives, antibiotics, benzocaine, perfumes, and steroid vehicle components like propylene glycol. Allergy to the corticosteroid itself is rare, but possible (see Chapter 6). Some patients have intolerance to a particular medication or vehicle, without signs of dermatitis. If either allergy or intolerance to vulvar topicals is suspected, management includes review of all potential products touching underclothes, fingers, or skin, simplification of vulvar care regimens, and/or change to a Class 3 topical steroid ointment. Biopsy of acute dermatitis demonstrates spongiosis - edema between epidermal squamous cells. Intraepidermal eosinophils are a supporting feature but dermal eosinophils occur in a range of conditions.<sup>35,36</sup> Chronic dermatitis is seen histologically as hyperkeratosis or parakeratosis, acanthosis, a lymphocytic infiltrate, and papillary dermal fibrosis.<sup>3,37</sup>

Drug eruptions are an unusual cause of recurrent or persistent redness and erosion. Common culprits are statins, non-steroidal anti-inflammatories, paracetamol/acetaminophen, co-trimoxazole and biologic agents like cytokine and immune checkpoint inhibitors.<sup>38-40</sup> The usual clinical appearance is a well-demarcated erythematous plaque of variable size, sometimes with edema and blisters. The histopathology of vulvar drug reactions is not well documented but may show a lichenoid or psoriasiform tissue reaction. Biopsy does not readily distinguish a lichenoid drug reaction from LP or non-sclerotic LS, as they all show basal layer damage accompanied by lymphocytic infiltrate. Psoriasiform drug reaction shows the same histologic features as candidiasis and psoriasis, again complicating the diagnostic process. A detailed medication history, combined with resolution on cessation of the offending agent, is the mechanism for resolving this phenomenon.

## **Focally abnormal skin – Reasons and management**

Steroid-resistant lesions within LS usually appear as white papules and plaques or red patches and plaques.<sup>41</sup> Clinicians undertake biopsy of the worst area within the lesion to confirm or exclude neoplasia. Common descriptions of white lesions on the pathology request form include 'recalcitrant white plaque,' 'steroid-resistant lesion,' or 'persistent hyperkeratosis.' The clinician documents any previous diagnosis of human papillomavirus-independent vulvar intraepithelial neoplasia (HPV-I VIN), vulvovaginal high-grade squamous intraepithelial lesion (HSIL), or squamous cell cancer (SCC). Informing the pathologist of higher pre-test probability alerts them to the need for deeper levels and additional scrutiny of the basal layer. Basal nuclear atypia is required to make a diagnosis of neoplasia, while immunohistochemistry for p16 and p53 establishes HPV-associated versus HPV-I etiology (see Chapter 11).<sup>42</sup>

Biopsies from recalcitrant white plaques usually show lichenified LS without evidence of neoplasia. Less commonly, the diagnosis is an unusual acanthotic lesion that may be la-

beled vulvar aberrant maturation (VAM) or HPV-I p53 wild-type verruciform acanthotic VIN (HPVI(p53wt)vaVIN) (see Chapter 11). Rarely there is HSIL, HPV-I VIN, or SCC. When the biopsy result is benign, histopathology infrequently offers insight into the reason for focal steroid non-response. While no studies detail the relationship between clinical LS control and histologic appearance, there are several common sense hypotheses. A dense lymphocytic infiltrate suggests inadequate exposure to topical steroids. Conversely, the absence of lymphocytes implies maximal steroid effect. Marked hyperkeratosis may be associated with incomplete steroid ointment penetration into the dermis. When the clinicopathologic assessment is benign with incomplete suppression of inflammation, the first step is to address provider- and patient-related reasons for undertreatment and consider an increase in steroid potency or frequency. If hyperkeratosis persists after maximizing topical therapy and biopsy is benign, clinicians may opt for intradermal steroid injection, topical retinoid, laser ablation if amenable, and/or supplemental systemic therapy (see Chapter 10).<sup>43–46</sup> Short interval follow-up is required to assess the post-intervention response. Excision is appropriate if lesions persist or recur despite multimodal treatment as they may represent previously undetected neoplasia.<sup>47</sup>

A new or persistent red plaque, patch, or erosion within LS raises concern for an alternate diagnosis or neoplasia. Clinicians label these request forms with a description of the lesion and clinical impression. The differential diagnosis includes herpes simplex virus, candidiasis, erosive LS, erosive LP, fixed drug eruption, HSIL, HPV-I VIN, or SCC. The diagnostic process may include speculum examination, microscopy, vulvovaginal culture, molecular testing, and/or biopsy. When suspicion for an infectious etiology is high and investigations are negative, it is reasonable to provide directed antiviral or antifungal treatment and reassessment, followed by tissue sampling if still unresolved.

## **Well controlled lichen sclerosus with persistent symptoms – Reasons and management**

Persistent pain or dyspareunia despite objective control of LS and otherwise physiologic-appearing skin may be due to estrogen deficiency, trauma arising from LS-related architectural changes, a superimposed pain syndrome, and/or psychosexual conditions.<sup>14</sup> Itch may represent a form of pain sensation. Estrogen deficiency relating to menopause, lactation, and progestogen-mediated contraceptives may produce sexual pain or sensations of vulvar awareness, dryness, and friction. Adhesions and sclerosis diminish elasticity and resilience of vestibular structures, potentially leading to fissures with attempted penetration (see Chapter 12). Vestibular allodynia and pelvic floor dysfunction are common across the lifespan and arise from a complex interplay of genetic, environmental, medical, and psychosexual events.<sup>48</sup> Anxiety, depression, arousal disorder, and partner issues may also contribute to pain and dyspareunia in the setting of LS.

Clinicians take a thorough history to identify causes and contributors to persistent symptoms. Neuromuscular pain may have a gradual or abrupt onset. It is often described as shooting, stabbing, or cramping pain that worsens through the day and is felt more on one side. Pain is exacerbated by sex or examination and the subsequent ache may last hours or

days. The traditional gynecologic distinguishers of entry versus deep dyspareunia are usually unhelpful as pain is difficult to localize and often multifocal.<sup>49</sup> There may be a foreign body sensation and relief when sitting on a donut cushion or toilet seat. Women with pain syndromes often report painful conditions at other sites, previous vulvovaginal or pelvic surgery, difficult pregnancy or birth experiences, recurrent VVC or urinary tract infections, bladder or bowel dysfunction, trauma to the spine or pelvic girdle, repetitive strain injuries, longstanding anatomic or postural abnormalities, and/or engagement in activities like horse riding, long-distance bicycling, pole dancing, or heavy weightlifting.<sup>50,51</sup> Vulvovaginal examination to identify contributing painful sites validates the woman's experience of pain, builds the therapeutic relationship, and guides management strategies.

The initial treatment approach involves maximizing LS control with topical steroids, identifying and treating estrogen deficiency, modifying behaviors that exacerbate pain, and encouraging pelvic floor physiotherapy (see Chapter 8). Surgical management is appropriate for LS-related architectural change if conservative measures are unsuccessful and the patient is willing to adhere to aggressive and long-term topical steroid treatment to prevent or forestall re-adhesion. Clinicians should provide hope and reassurance that most women with vulvovaginal and sexual pain experience improvement when they engage with a multidisciplinary care program.

## Limitations of the literature

Investigators have not yet meaningfully addressed the topic of steroid non-response and it is a rarity when clearly defined. The terms 'recalcitrant' and 'non-response' are often used in reference to women enrolled in interventional studies of alternative treatment approaches like calcineurin inhibitors, laser, and injectables. However, these studies' methods often offer little insight into pre-study steroid regimens and the nature of non-response. Documentation of the comorbidities and superinfections that complicate LS is sparse, in contrast to their common occurrence in day-to-day clinical practice. There is no clinicopathologic research that details the relationship between clinical assessment of LS activity and the corresponding histologic appearance.

## Conclusions and recommendations

Almost all women with LS respond to topical steroids if the diagnosis is correct and they adhere to a long-term regimen titrated to severity of disease. A systematic approach using history, examination, investigations, and histopathology usually identifies one or more reasons for new or persistent symptoms or signs. Interventional studies that purport to enroll 'steroid non-responders' require critical analysis, as the authors may have misdiagnosed or undertreated the study cohort. In the setting of true focal non-response, biopsy helps to exclude neoplasia and guide progress through the differential diagnosis and management strategy.

- Direct and supportive provider counseling must accompany a prescription for topical steroids and address where, why, and how much to use, the natural history of LS, steroid phobia, and the emotional journey towards acceptance and treatment self-efficacy.

- Key objectives of follow-up visits are to assess LS control, troubleshoot barriers to steroid adherence, offer commendation to those who have attained excellent control, and encourage patients to continue treatment.
- Multiple concurrent vulvovaginal conditions are the rule rather than the exception and may account for apparent non-response of LS to topical steroids.
- Cutaneous candidiasis is common in postmenopausal women with LS who also have obesity, diabetes, immunosuppression, incontinence, skin occlusion, antibiotic use, and/or exogenous estrogen exposure.
- Options for management of benign but persistent focal white plaques in LS include intralesional steroids, topical retinoids, systemic therapies, laser ablation, and excision, but persistently non-responsive lesions raise concern for neoplasia and the need for surgical removal.

## References

1. Croker BA, Scurry JP, Petry FM, Fischer G. Vestibular Sclerosis: Is This a New, Distinct Clinicopathological Entity? *J Low Genit Tract Dis*. 2018;22(3):260-263. doi:10.1097/LGT.0000000000000404
2. Day T, Burston K, Dennerstein G, Pagano R, Scurry J. Vestibulovaginal Sclerosis Versus Lichen Sclerosus. *Int J Gynecol Pathol*. 2018;37(4):356. doi:10.1097/PGP.0000000000000441
3. Lynch PJ. Lichen simplex chronicus (atopic/neurodermatitis) of the anogenital region. *Dermatol Ther*. 2004;17(1):8-19. doi:10.1111/j.1396-0296.2004.04002.x
4. Day T, Wilkinson E, Rowan D, Scurry J. Clinicopathologic Diagnostic Criteria for Vulvar Lichen Planus. *J Low Genit Tract Dis*. 2020;24(3):317-329. doi:10.1097/LGT.0000000000000532
5. Wu M, Lee G, Fischer G. Forming diagnostic criteria for vulvar lichen planus. *Australas J Dermatol*. 2020;61(4):324-329. doi:10.1111/ajd.13350
6. Day T, Moore S, Bohl TG, Scurry J. Comorbid Vulvar Lichen Planus and Lichen Sclerosus. *J Low Genit Tract Dis*. 2017;21(3):204-208. doi:10.1097/LGT.0000000000000307
7. Day T, Weigner J, Scurry J. Classic and Hypertrophic Vulvar Lichen Planus. *J Low Genit Tract Dis*. 2018;22(4):387. doi:10.1097/LGT.0000000000000419
8. Van der Linden M, Meeuwis K a. P, Bulten J, Bosse T, van Poelgeest MIE, de Hullu JA. Paget disease of the vulva. *Crit Rev Oncol Hematol*. 2016;101:60-74. doi:10.1016/j.critrevonc.2016.03.008
9. Yeon J, Oakley A, Olsson A, et al. Vulval lichen sclerosis: An Australasian management consensus. *Australas J Dermatol*. 2021;62(3):292-299. doi:10.1111/ajd.13594
10. Saunderson RB, Harris V, Yeh R, Mallitt K, Fischer G. Vulvar quality of life index (VQLI) – A simple tool to measure quality of life in patients with vulvar disease. *Australas J Dermatol*. 2020;61(2):152-157. doi:10.1111/ajd.13235
11. Wu M, Kherlopian A, Wijaya M, Fischer G. Quality of life impact and treatment response in vulvar disease: Comparison of 3 common conditions using the Vulval Quality of Life Index. *Australas J Dermatol*. 2022;63(4). doi:10.1111/ajd.13898
12. Wijaya M, Lee G, Fischer G, Lee A. Quality of Life in Vulvar Lichen Sclerosus Patients Treated With Long-Term Topical Corticosteroids. *J Low Genit Tract Dis*. 2021;25(2):158-165. doi:10.1097/LGT.0000000000000599
13. Sheinis M, Green N, Vieira-Baptista P, et al. Adult Vulvar Lichen Sclerosus: Can Experts Agree on the Assessment of Disease Severity? *J Low Genit Tract Dis*. 2020;24(3):295-298. doi:10.1097/LGT.0000000000000534
14. Wijaya M, Lee G, Fischer G. Why do some patients with vulvar lichen sclerosis on long-term topical corticosteroid treatment experience ongoing poor quality of life? *Australas J Dermatol*. 2022;63(4):463-472. doi:10.1111/ajd.13926
15. Lee A, Bradford J, Fischer G. Long-term Management of Adult Vulvar Lichen Sclerosus: A Prospective Cohort Study of 507 Women. *JAMA Dermatol*. 2015;151(10):1061-1067. doi:10.1001/jamadermatol.2015.0643
16. Renaud-Vilmer C, Cavalier-Balloy B, Porcher R, Dubertret L. Vulvar lichen sclerosis: effect of long-term topical application of a potent steroid on the course of the disease. *Arch Dermatol*. 2004;140(6):709-712. doi:10.1001/archderm.140.6.709
17. Farrugia LL, Lee A, Fischer G, Blaszczynski A, Carter SR, Smith SD. Evaluation of the influence of pharmacists and GPs on patient perceptions of long-term topical corticosteroid use. *J Dermatol Treat*. 2017;28(2):112-118. doi:10.1080/09546634.2016.1213353



18. Nic Dhonncha E, O'Connor C, O'Connell G, Quinlan C, Roche L, Murphy M. Adherence to treatment with prescribed topical corticosteroid therapy and potential barriers to adherence among women with vulvar lichen sclerosus: a prospective cross-sectional study. *Clin Exp Dermatol*. 2021;46(4):734-735. doi:10.1111/ced.14527
19. Ahn CS, Culp L, Huang WW, Davis SA, Feldman SR. Adherence in dermatology. *J Dermatol Treat*. 2017;28(2):94-103. doi:10.1080/09546634.2016.1181256
20. Delpero E, Sriharan A, Selk A. Steroid Phobia in Patients With Vulvar Lichen Sclerosus. *J Low Genit Tract Dis*. 2023;27(3):286-290. doi:10.1097/LGT.0000000000000753
21. Terlou A, Santegoets LAM, van der Meijden WI, et al. An autoimmune phenotype in vulvar lichen sclerosus and lichen planus: a Th1 response and high levels of microRNA-155. *J Invest Dermatol*. 2012;132(3 Pt 1):658-666. doi:10.1038/jid.2011.369
22. Uva L, Miguel D, Pinheiro C, et al. Mechanisms of Action of Topical Corticosteroids in Psoriasis. *Int J Endocrinol*. 2012;2012:1-16. doi:10.1155/2012/561018
23. McQuaid EL, Landier W. Cultural Issues in Medication Adherence: Disparities and Directions. *J Gen Intern Med*. 2018;33(2):200-206. doi:10.1007/s11606-017-4199-3
24. Arnold S, Fernando S, Rees S. Living with vulval lichen sclerosus: a qualitative interview study. *Br J Dermatol*. 2022;187(6):909-918. doi:10.1111/bjd.21777
25. Rees S, Arnold S, Kherlopian A, Fischer G. Attitudes Toward Proactive Topical Corticosteroid Use Among Women With Vulval Lichen Sclerosus. *J Low Genit Tract Dis*. 2024;28(2):183-188. doi:10.1097/LGT.0000000000000791
26. Farr A, Effendy I, Frey Tirri B, et al. Guideline: Vulvovaginal candidosis (AWMF 015/072, level S2k). *Mycoses*. 2021;64(6):583-602. doi:10.1111/myc.13248
27. Hong E, Dixit S, Fidel PL, Bradford J, Fischer G. Vulvovaginal candidiasis as a chronic disease: diagnostic criteria and definition. *J Low Genit Tract Dis*. 2014;18(1):31-38. doi:10.1097/LGT.0b013e318287aced
28. Day T, Chapman-Burgess E, Scurry J. Clinicopathologic Overlap of Vulvar Psoriasis and Candidiasis. *J Low Genit Tract Dis*. 2024;28(2):175-182. doi:10.1097/LGT.0000000000000801
29. Crouss T, Sobel JD, Smith K, Nyirjesy P. Long-Term Outcomes of Women With Recurrent Vulvovaginal Candidiasis After a Course of Maintenance Antifungal Therapy. *J Low Genit Tract Dis*. 2018;22(4):382-386. doi:10.1097/LGT.0000000000000413
30. Fischer G, Bradford J. Vulvovaginal Candidiasis in Postmenopausal Women: The Role of Hormone Replacement Therapy. *J Low Genit Tract Dis*. 2011;15(4):263-267. doi:10.1097/LGT.0b013e3182241f1a
31. Forman JL, Mercurio MG. Vulvar Pruritus in Postmenopausal Diabetic Women With Candidiasis Secondary to Sodium-Glucose Cotransporter Receptor-2 Inhibitors. *J Low Genit Tract Dis*. 2023;27(1):68-70. doi:10.1097/LGT.0000000000000704
32. Mounsey SJ, Teo YX, Calonje JE, Lewis FM. Gliflozin (SGLT2 inhibitor) induced vulvitis. *Int J Dermatol*. 2023;62(1):62-65. doi:10.1111/ijd.16449
33. Day T, Borbolla Foster A, Phillips S, et al. Can Routine Histopathology Distinguish Between Vulvar Cutaneous Candidiasis and Dermatophytosis? *J Low Genit Tract Dis*. 2016;20(3):267-271. doi:10.1097/LGT.0000000000000208
34. Foote CA, Brady SP, Brady KL, Clark NS, Mercurio MG. Vulvar Dermatitis From Allergy to Moist Flushable Wipes. *J Low Genit Tract Dis*. 2014;18(1):E16-E18. doi:10.1097/LGT.0b013e31828e499f
35. Lester EB, Swick BL. Eosinophils in biopsy specimens of lichen sclerosus: a not uncommon finding. *J Cutan Pathol*. 2015;42(1):16-21. doi:10.1111/cup.12445
36. Carlson JA, Lamb P, Malfetano J, Ambros RA, Mihm MC. Clinicopathologic comparison of vulvar and extragenital lichen sclerosus: histologic variants, evolving lesions, and etiology of 141 cases. *Mod Pathol Off J US Can Acad Pathol Inc*. 1998;11(9):844-854.
37. Day T, Bohl TG, Scurry J. Perianal lichen dermatoses: A review of 60 cases. *Australas J Dermatol*. 2016;57(3):210-215. doi:10.1111/ajd.12308
38. Binns HM, Tasker F, Lewis FM. Drug eruptions and the vulva. *Clin Exp Dermatol*. Published online October 31, 2023;llad369. doi:10.1093/ced/llad369
39. Fischer G. Vulvar fixed drug eruption. A report of 13 cases. *J Reprod Med*. 2007;52(2):81-86.
40. Geisler AN, Phillips GS, Barrios DM, et al. Immune checkpoint inhibitor–related dermatologic adverse events. *J Am Acad Dermatol*. 2020;83(5):1255-1268. doi:10.1016/j.jaad.2020.03.132
41. Heller DS, Day T, Allbritton JJ, et al. Diagnostic Criteria for Differentiated Vulvar Intraepithelial Neoplasia and Vulvar Aberrant Maturation. *J Low Genit Tract Dis*. 2021;25(1):57-70. doi:10.1097/LGT.0000000000000572
42. Thuijs NB, Van Beurden M, Duin S, et al. High-grade vulvar intraepithelial neoplasia: comprehensive characterization and long-term vulvar carcinoma risk. *Histopathology*. 2024;84(2):301-314. doi:10.1111/his.15050

43. Lee A, Lim A, Fischer G. Fractional carbon dioxide laser in recalcitrant vulval lichen sclerosus. *Australas J Dermatol*. 2016;57(1):39-43. doi:10.1111/ajd.12305
44. Hobson JG, Ibrahim SF, Mercurio MG. Recalcitrant Vulvar Lichen Sclerosus Treated With Erbium YAG Laser. *JAMA Dermatol*. 2019;155(2):254-256. doi:10.1001/jamadermatol.2018.4461
45. Lee A, Fischer G. Diagnosis and Treatment of Vulvar Lichen Sclerosus: An Update for Dermatologists. *Am J Clin Dermatol*. 2018;19(5):695-706. doi:10.1007/s40257-018-0364-7
46. Hargis A, Ngo M, Kraus CN, Mauskar M. Systemic Therapy for Lichen Sclerosus: A Systematic Review. *J Low Genit Tract Dis*. 2024;28(1):84-90. doi:10.1097/LGT.0000000000000775
47. Preti M, Joura E, Vieira-Baptista P, et al. The European Society of Gynaecological Oncology (ESGO), the International Society for the Study of Vulvovaginal Disease (ISSVD), the European College for the Study of Vulvar Disease (ECSVD) and the European Federation for Colposcopy (EFC) consensus statements on pre-invasive vulvar lesions. *Int J Gynecol Cancer*. 2022;32(7):830-845. doi:10.1136/ijgc-2021-003262
48. Bornstein J, Goldstein AT, Stockdale CK, et al. 2015 ISSVD, ISSWSH and IPPS Consensus Terminology and Classification of Persistent Vulvar Pain and Vulvodinia. *Obstet Gynecol*. 2016;127(4):745-751. doi:10.1097/AOG.0000000000001359
49. Gyang A, Hartman M, Lamvu G. Musculoskeletal Causes of Chronic Pelvic Pain: What a Gynecologist Should Know. *Obstet Gynecol*. 2013;121(3):645-650. doi:10.1097/AOG.0b013e318283ffea
50. Harm-Ernandes I, Boyle V, Hartmann D, et al. Assessment of the Pelvic Floor and Associated Musculoskeletal System: Guide for Medical Practitioners. *Female Pelvic Med Reconstr Surg*. 2021;27(12):711-718. doi:10.1097/SPV.0000000000001121
51. Harris V, Fischer G, Bradford JA. The aetiology of chronic vulvar pain and entry dyspareunia: a retrospective review of 525 cases. *Aust N Z J Obstet Gynaecol*. 2017;57(4):446-451. doi:10.1111/ajo.12613

# Proposed alternatives to treatment with topical steroids

*Emma Veysey, Melissa Mauskar, Andrew Goldstein*

**T**opical corticosteroids are effective in nearly all patients with vulvar LS (see Chapter 6). When patients have persistent symptoms or signs despite topical steroids, clinicians undertake a systematic approach to determining and addressing the reason(s) for non-response (see Chapter 9). Nonetheless, patients and providers often seek alternative therapies. Multiple medical devices, procedures, topicals, and systemic agents have been proposed as alternatives to topical steroids, each with their own mechanisms of action, side effect profiles, and feasibility implications.

## Topical agents

### Calcineurin inhibitors

Topical calcineurin inhibitors prevent local T-cell production of pro-inflammatory cytokines interleukin (IL)-2, IL-3, IL-4, IL10, interferon- $\gamma$ , and granulocyte macrophage colony-stimulating factor.<sup>1</sup> Their main clinical application is atopic dermatitis, but they have been explored as treatment for psoriasis and LS. The two main calcineurin inhibitors are pimecrolimus cream and tacrolimus ointment. Topical tacrolimus produces a transient burning sensation in 20-50% of women with LS, with this symptom usually resolving after 3 weeks of treatment.<sup>2</sup> Pimecrolimus appears to be better tolerated than tacrolimus, but demonstrates less permeability through the skin and less systemic absorption. As a weaker immunosuppressant than tacrolimus, it requires higher concentrations to achieve therapeutic benefit.<sup>3,4</sup>

A 2011 Cochrane review concluded that topical pimecrolimus and clobetasol propionate provided similar symptom relief of LS, but clobetasol was more effective in improving clinical appearance and reducing inflammation.<sup>5</sup> Subsequently, a randomized controlled trial (RCT) comparing tacrolimus 0.1% ointment with clobetasol once daily in 55 women for 3 months found clobetasol was superior in treating LS signs and symptoms.<sup>6</sup> An arm-based network meta-analysis found clobetasol ranked first compared to other topical therapies for LS remission, while tacrolimus ranked second. However, the small study sizes and suboptimal methodology of studies on calcineurin inhibitors limited the authors' ability to draw further conclusions about the relative performance of topical therapies.<sup>7</sup>

In most care settings, the role of topical calcineurin inhibitors is limited to management of patients who decline steroid maintenance. Another potential application is as a steroid-spar-

ing agent in the uncommon patient who needs daily treatment for symptom amelioration but shows signs of steroid overuse. Clinicians must inform these patients there is no long-term outcome data addressing architectural change or squamous cell carcinoma (SCC) risk for women using calcineurin inhibitors to manage LS.

## Topical retinoids

Topical retinoids induce keratinocyte proliferation and differentiation, while promoting collagen remodeling and increasing hyaluronic acid content in the upper reticular dermis. This mechanism of action often results in irritation, skin sensitivity, and flaking. Topical retinoids are used as first-line therapy for acne vulgaris and as part of anti-aging regimens that address fine lines, wrinkles, and dyspigmentation. A handful of small studies have assessed topical retinoids as a single agent or in combination with topical steroids for treatment of LS. In one uncontrolled study, 22 patients with LS were treated with topical tretinoin 0.025% 5 days per week for 1 year. Compared to baseline, symptoms, clinical signs, and histologic features were significantly improved and side effects did not result in medication cessation.<sup>8</sup> Several years later, a second study looked at alternate day dosing of topical tretinoin 0.025% in 17 patients with LS over a 12 week period, with 70% of patients experiencing a response to treatment, although only 17% of patients experienced an objective improvement over 75%.<sup>9</sup> A combination regimen of tretinoin 0.05% cream and mometasone 0.1% ointment each used 5 days per week did not provide benefits to symptoms or signs when compared to the topical steroid plus emollient on the same schedule.<sup>10</sup> The potential for tretinoin as an adjunct to steroids in maintenance therapy remains unclear with the limited available data.

## Hormonal management

In 1984, Friedrich and Karla examined systemic hormone levels in women with LS aged 19-89 years and found those with untreated disease had higher levels of free testosterone and lower levels of dihydrotestosterone (DHT) and androstenedione.<sup>11</sup> After treatment with topical testosterone in ten patients, two did not have a clinical response, although their androgen levels were among the highest tested. This work led to several studies evaluating the efficacy of topical sex hormones including testosterone, progesterone, and DHT (Table 1).<sup>12-16</sup> No hormonal therapy was superior to potent topical steroids.

**TABLE 1 Comparisons of clinical trials of topical sex steroids**

Clinical Trial	Summary	Outcome
Bracco, et al. <i>J Reprod Med</i> 1993 <sup>12</sup>	RCT comparing 2% progesterone, 2% testosterone, petroleum ointment, clobetasol propionate 0.05% in seventy-nine patients.	Topical clobetasol propionate 0.05% was superior.
Sideri, et al. <i>Int J Gynaecol Obstet</i> 1994 <sup>13</sup>	Double-blind RCT of fifty-eight patients comparing 2% testosterone propionate and petrolatum ointment over 1 year, with biopsy at end of treatment period.	Both groups had improvement in symptoms: twenty (67%) patients in the testosterone group and twenty-one (75%) in the placebo group, however there was no histologic improvement.
Paslin. <i>Int J Dermatol</i> . 1996 <sup>14</sup>	Double-blind cross-over study of five patients comparing 2% DHT and 2% testosterone propionate. Patients were instructed to rub 10cm of material into skin twice daily.	All five patients had clinical improvement. Dermal inflammation persisted despite application of DHT or testosterone.
Cattaneo, et al. <i>J Reprod Med</i> . 1996 <sup>15</sup>	Thirty-two patients were treated with 0.05% clobetasol propionate for 24 weeks, after which they were randomized to testosterone 2% ointment or cream-based placebo.	After initial clobetasol therapy, all patients had significant improvement. After testosterone maintenance, all patients had worsening symptoms while the placebo group had symptomatic control.
Bornstein, et al. <i>Am J Obstet Gynecol</i> . 1998 <sup>16</sup>	Forty patients with severe LS were evaluated before or after 1990. Before 1990, twenty were treated with topical testosterone propionate 2% twice daily and after 1990, twenty patients treated with clobetasol propionate 0.05% twice daily.	At 3 months, there was no difference in symptoms but a significant improvement in clinical signs in the clobetasol group compared to testosterone. After 1 year of treatment, symptoms and signs of disease were significantly better in the clobetasol group.

## Systemic medications

A systematic review of systemic treatments for LS found 71 studies of 392 patients. Reported treatments included: oral retinoids (n = 227), methotrexate (n = 59), hydroxychloroquine (n = 36), and systemic steroids (n = 60). Studies used different treatment endpoints and outcome measures, making comparisons difficult. Over 75% of patients were reported to have clinical or symptomatic improvement.<sup>17</sup>

### Oral retinoids

Oral retinoids are derived from vitamin A and have anti-inflammatory and anti-proliferative effects and promote keratinocyte differentiation.<sup>18</sup> They are not immunosuppressive but are teratogenic. They are effective in a range of dermatologic disorders including psoriasis, acne, lichen planus, and skin cancer prevention. Oral retinoids include etretinate, acitretin, and isotretinoin. Several case reports and series and small open label trials report benefit in symptoms and clinical severity with etretinate for vulvar LS.<sup>19-23</sup> However, etretinate has been withdrawn from most jurisdictions due to its long half-life yielding prolonged side effects and increased risk of teratogenicity.

A RCT of 78 women with biopsy-confirmed LS were randomized to acitretin 30mg or placebo daily for 16 weeks, with an option to decrease to 20mg daily after 4 weeks if needed due to side effects. After treatment there was a statistically significant decrease in the acitretin arm of symptoms and signs including pruritus, atrophy, and hyperkeratosis.<sup>24</sup> Most patients decreased to 20mg daily at 4 weeks. A case report described a patient with LS complicated by recurrent SCC with persistent hyperkeratotic disease responding to acitretin 25mg daily, reducing to 10mg daily after development of arthralgias and hair loss.<sup>25</sup>

Common side effects with all oral retinoids (> 10%) include cheilitis, alopecia, skin peeling, dry skin, nail disease, pruritus, and paronychia. Systemic adverse effects include hypertriglyceridemia, glucose dysregulation, dyslipidemia, hepatitis, myalgia, arthralgia, and spinal hyperostosis.<sup>26</sup> Retinoids should be avoided in reproductive-age patients at risk of pregnancy. There is insufficient evidence to recommend the use of acitretin as LS treatment, but it may have a role in managing hyperkeratotic plaques non-responsive to topical steroids.

## Methotrexate

Methotrexate (MTX) is widely used to treat a variety of inflammatory conditions but the mechanism of action is not fully understood. It may involve inhibition of Th-1-related cytokines and suppression of the JAK/STAT signaling pathway, both implicated in the pathogenesis of LS.<sup>27</sup> Case series and reports describe some benefit in treatment of extragenital LS, with effects on genital LS either not stated or already controlled with topical corticosteroids.<sup>28-30</sup>

Routes of administration of MTX are oral and subcutaneous or intramuscular injections. Many patients on MTX report mild, transient gastrointestinal side effects including nausea, vomiting, diarrhea, abdominal pain, and dyspepsia. More severe but rare adverse effects include hepatotoxicity, cirrhosis, myelotoxicity, pulmonary toxicity, nephrotoxicity, and lymphoproliferative disorders.<sup>26</sup> Severe impacts are more likely in patients prescribed daily rather than weekly use.<sup>31</sup> Methotrexate is an abortifacient and teratogen. All genders should cease treatment at least three months prior to conception and reproductive-age women using MTX require reliable contraception.<sup>26</sup> In the largest case series of patients with genital and extragenital LS treated with MTX, 5 (21%) ceased treatment due to side effects including gastrointestinal upset and hair loss, comparable to the 1-year cessation rates established in the general rheumatology literature.<sup>30-33</sup> Supplementation with folic acid may limit some adverse effects, with a common dosing regimen being 5mg of folic acid taken on a different day of the week to the MTX.<sup>34</sup> In the rare circumstance of a patient with uncontrolled LS despite daily super potent corticosteroids who has no contraindication to MTX, it may be considered as an adjunctive therapy.

## Hydroxychloroquine

Hydroxychloroquine is an antimalarial medication with anti-inflammatory and photoprotective benefits, often used in patients with systemic lupus erythematosus. Other applications include management of sarcoidosis, polymorphous light eruption, porphyria cutanea tarda, and lichenoid disorders due to the mild side effect profile and broad effects. Its mechanism

of action involves several processes that interfere with T-cell receptor signaling, antigen processing, and inhibition of autophagy.<sup>35</sup> A recent retrospective study evaluated hydroxychloroquine in patients with anogenital and extragenital LS, of whom 36% had a connective tissue disorder and 24% had morphea. The reported response was 70% among those treated solely for LS, with response more likely in anogenital versus extragenital disease.<sup>36</sup> This cohort continued topical steroids but the drug and frequency were not discussed, making it difficult to assess the potential benefit of hydroxychloroquine over an enhanced topical steroid regimen. Hydroxychloroquine is often prescribed at 200mg twice daily but should be dosed at 5mg/kg based on actual body weight. Long-term higher-dose hydroxychloroquine use is associated with retinopathy, which develops in 7.5% of patients after 5 years and approaches 20% at 20 years.<sup>37</sup> However, when dosed at the recommended 5 mg/kg, patients have <1% risk of toxicity at 5 years and <2% at 10 years.<sup>38</sup> Prior to initiating hydroxychloroquine, patients should have screening for underlying retinopathy and then continue ophthalmologic examinations every 5 years during treatment.<sup>38</sup> The role of hydroxychloroquine as an adjunctive therapy for LS requires further study.

## Janus kinase inhibitors

Janus kinase (JAK) inhibitors may work via inhibition of pro-fibrotic and T-lymphocyte activation.<sup>39,40</sup> To date, the role of JAK inhibitors for LS has been assessed in case reports and small uncontrolled studies. A recent publication evaluated 10 adult patients treated with abrocitinib 100mg once daily as monotherapy over a 4 month period.<sup>41</sup> All experienced objective disease control by week 12, as measured by Investigator's Global Assessment improvement of >2 and decreased inflammatory density on reflectance confocal microscopy.<sup>41</sup> Symptom improvement occurred in as little as 2 weeks. Several smaller reports confirmed this finding.<sup>42-46</sup> Common untoward effects of JAK inhibitors include hyperlipidemia and upper respiratory infection. Uncommon side effects include hypertension, acne, rash, urinary tract infection, anemia, and headache. Significant rare adverse effects include myocardial infarction, thromboembolic events, malignancy and hepatotoxicity.<sup>47</sup> While systemic JAK inhibitors are promising agents for inflammatory dermatoses, the 'off-label' status for LS, side effect profile, and high cost limit their clinical utility. A topical route of administration may circumvent some of these issues. A Phase 2 RCT evaluating topical JAK inhibitors for LS was recently completed and results are forthcoming.

## Cyclosporine

Cyclosporine is a calcineurin inhibitor and thereby limits the synthesis of pro-inflammatory cytokines like IL-2 and tumor necrosis factor (TNF)- $\alpha$ , resulting in reduced T-lymphocyte proliferation. A case series of 5 women with severe LS unresponsive to potent topical steroids treated with cyclosporine 3-4mg/kg daily for 3 months reported improvement in mean symptom score and reduced clinical severity.<sup>48</sup> Cyclosporine has a rapid onset of action and is often substituted for systemic steroids in erythrodermic psoriasis, atopic dermatitis, and Stevens-Johnson syndrome. While usually well tolerated, acute dose-dependent nephrotoxicity and hypertension are common. Less commonly over the longer term, chronic ir-

reversible renal damage may occur. Other side effects include tremor, headaches, gingival hyperplasia, and hirsutism.<sup>49</sup> Cyclosporine use should be limited to 12 months given the risk of nephrotoxicity and hypertension.<sup>50</sup> There is insufficient evidence to recommend cyclosporine for LS treatment but it may be considered as an adjunct in women with recalcitrant disease and no contraindications to its use.

## Tumor necrosis factor- $\alpha$ inhibitors

The evidence to support the use of anti-TNF- $\alpha$  therapy for LS is limited to case reports.<sup>51-54</sup> There is one report of 2 women with severe vulvar LS treated with subcutaneous adalimumab 40mg weekly. Both failed combinations of clobetasol propionate 0.05% ointment, systemic oral corticosteroids, acitretin, MTX, and mycophenolate mofetil. One experienced significant improvement in clinical severity and quality of life (QoL) scores and the other reported modest improvement but described it as the most effective treatment to date.<sup>53</sup> Another case report described a woman with generalized morphea/LS overlap responding to intravenous infliximab.<sup>54</sup>

Patients may develop injection site reactions, upper respiratory tract infections, headaches, rashes, and nausea. Less common side effects include new infection or reactivation of latent tuberculosis, viral, fungal, or opportunistic organisms.<sup>55</sup> A baseline immunosuppression and tuberculosis screening must be performed before commencing treatment. Anti-TNF- $\alpha$  therapy is associated with increased rates of lymphoma and other malignancies. Other potential adverse effects include demyelinating disease, heart failure, and induction of autoimmunity.<sup>55</sup> Given the high-risk side effect profile and inadequate evidence of efficacy and safety, TNF-inhibitors are a suboptimal choice for adjunctive therapy of LS with inadequate response to topical steroids.

## Medical devices and procedures

### High intensity focused ultrasound

High intensity focused ultrasound (HIFU) is a non-invasive procedure in which directed ultrasound causes localized coagulative necrosis due to transduction of thermal energy.<sup>56</sup> This technology is not widely available, but there are several studies evaluating it for non-neoplastic epithelial disorders of the vulva. One small study evaluating 84 patients with LS reports benefits; however, the study was retrospective, biopsies were not obtained, and several clinical photos appear more consistent with lichen simplex chronicus.<sup>57</sup> Given side effects such as skin burns, scarring, and blisters, evidence does not support its use outside of clinical studies at this time.

### Photodynamic therapy

Photodynamic therapy (PDT) is often used as a non-invasive field treatment of acne, psoriasis, superficial basal cell carcinoma, and actinic keratoses. Briefly, PDT involves skin application of photosensitive chemicals, most often 5-aminolevulinic acid (ALA) or methyl aminolevulinic acid (methyl-ALA) and directing a photo-activating light source on the target area.



Upon exposure to light, the topical agents undergo an oxidation reaction that creates protoporphyrin IX and single oxygen species. These are preferentially taken up by inflammatory and precancerous cells, causing targeted damage. The treatment depth and intensity may be modified by varying the wavelength of light applied, ranging from blue light at 410nm to red light at 630nm.<sup>58</sup>

Photodynamic therapy has been proposed as a treatment for 'refractory' LS. Two systematic reviews identified 20 studies and 488 patients, the majority pretreated with ALA.<sup>58,59</sup> Most patients reported mild burning or pain during treatment resolving with completion of therapy and mild local erythema and swelling for one week afterwards. One patient developed a severe erosion from PDT that resolved with mupirocin ointment. Sixteen of twenty studies reported improvement in pruritus, but many studies did not identify improvement in clinical signs or post-treatment histology.<sup>59</sup> Photodynamic therapy may have an adjunctive role for symptomatic improvement in LS, but the machine design may limit feasibility for genital area treatment.

### **Platelet rich plasma and autologous adipose-derived stem cells**

Autologous platelet-rich plasma (PRP) is a platelet concentrate widely used in a variety of applications to include diabetic foot ulcers, acute muscle injury, tendinopathy, and cosmetic procedures.<sup>60-62</sup> Platelet-rich plasma contains platelet-derived growth factor (PDGF), transforming growth factor- $\beta$  (TGF- $\beta$ ), and epidermal growth factor (EGF) that may accelerate wound healing. Autologous adipose-derived stem cells (ADSC) are mesenchymal stem cells obtained from liposuction specimens and numerically increased *in vitro*. These stem cells have the capacity to differentiate into multiple cell lineages including adipocytes, chondrocytes, and osteocytes and interact with lymphocytes, dendritic cells, and macrophages.<sup>63</sup> It is hypothesized ADSC have the potential to regenerate tissues and organs damaged by injury or disease.

Both PRP and ADSC have been studied as LS treatments, mostly in case series and small uncontrolled studies. A qualitative analysis of 9 studies that used PRP, 5 that used ADSC, and 6 that used both agents for vulvar LS identified major methodological flaws in all but one study with heterogeneity in study design, reliance on subjective outcomes, non-validated objective measures, and limited short-term follow-up.<sup>63</sup> The majority of studies assessing PRP alone showed a reduction in itching, burning, and pain, with one study reporting reduced distribution of LS.<sup>63-65</sup> However, one double-blind RCT showed PRP did not improve inflammation on post-treatment biopsies.<sup>66</sup> The studies of ADSC alone reported improvement in vulvar skin appearance, a reduction in white lesions, and improved sexual function.<sup>67,68</sup> A study of 72 women injected with PRP and ADSC reported improvement in the Dermatology Life Quality Index, Skindex-29, Female Sexual Function Index, and a patient-administered clinical scoring system.<sup>69</sup> Patient and clinician financial considerations related to these products may increase the risks of confirmation and recall bias and enhance the placebo effect. The evidence to date does not support use of PRP and ADSC for vulvar LS unless as part of a clinical trial.

## Fractional laser

Lasers are commonly used for skin resurfacing in dermatology. In recent years, there has been an explosion of marketing that promotes laser as a treatment for vulvar LS, despite a lack of high-quality studies demonstrating efficacy. Most publications involve microablative fractional CO<sub>2</sub> laser therapy (FxCO<sub>2</sub>), though other modalities have been used including fractional erbium-doped yttrium aluminum garnet (Er:YAG) lasers, non-fractionated ablative CO<sub>2</sub> lasers, and diode lasers.<sup>70</sup> Fractional CO<sub>2</sub> lasers have a wavelength of 10,600nm allowing a superficial microablative effect in skin with a pulsed beam to reduce thermal damage outside the target zone. The fractionated laser beam creates a grid configuration of pinpoint burns, each dot measuring 150-200µm (Fig 1). The effect of microablation is to stimulate remodeling of connective tissue via the production of heat shock protein 47 and production of collagen, fibroblasts, and ground matrix.<sup>71</sup>

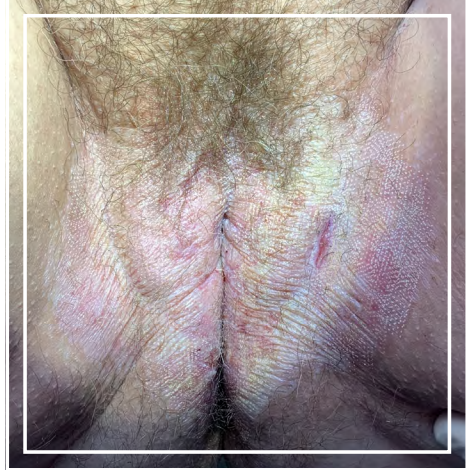

FIGURE 1. Severe vulvar LS exposed to fractional CO<sub>2</sub> laser with the grid-dot pattern still visible

Multiple small uncontrolled studies with short follow-up intervals suggest FxCO<sub>2</sub> for vulvar LS improves symptoms like itching and burning. A recent meta-analysis of laser for LS identified 27 studies, of which 6 met the inclusion criteria of having a control group.<sup>70</sup> Only 1 of these 6 publications used a sham placebo control and was assessed as having a low risk of bias according to the updated Cochrane Collaboration tool.<sup>72</sup> The other 5 studies compared laser to topical steroid and demonstrated methodologic flaws relating to the randomization process, treatment protocols, deviation from intended interventions, inadequate measurement of outcomes, missing outcome data, and selective presentation of results. This sole sham-controlled RCT recruited 37 patients with biopsy-confirmed LS who were agreeable to 4 weeks off treatment and a post-intervention vulvar biopsy.<sup>72</sup> They were randomized to 5 sessions over 24 weeks of FxCO<sub>2</sub> laser with either 'treatment' or sham energy settings. The primary outcome was change in the histopathology score and the secondary outcome was change in the clinical scoring system (CSS). There was no change in the pathology score in either group. Both groups experienced a similar improvement in the subjective CSS, but neither showed a change in the objective CSS. The authors concluded that FxCO<sub>2</sub> laser is not effective as monotherapy for LS and the placebo response rate of a non-steroid intervention for LS is at least 25%. A Swiss group subsequently undertook a sham-controlled trial of FxCO<sub>2</sub> laser for LS in 63 women and likewise found no difference between groups in LS-related symptoms or signs.<sup>73</sup>

The role of laser as an adjunct to topical steroids has been explored in several case series. One study documents 5 women with persistent white plaques despite ongoing treatment with clobetasol propionate 0.05% ointment.<sup>74</sup> Four women had FxCO<sub>2</sub> laser and 1 had glob-

al ablative laser applied to hyperkeratotic areas. All patients showed objective improvement with normalized texture and near-normal skin color, maintained with ongoing clobetasol propionate ointment. Two required a repeat laser session after 6-8 months. A case report describes 2 patients with hyperkeratotic LS despite clobetasol propionate 0.05% ointment once to twice daily, intralesional triamcinolone acetate, and topical retinoids. They underwent ablative Er:YAG laser and resumed topical steroids post-procedure.<sup>75</sup> Both women showed marked improvement with resolution of hyperkeratotic plaques; 1 required 3 procedures to achieve this result. These studies suggest a role for laser to reduce the thickness of white plaques that fail to respond to maximal medical therapy and are benign on biopsy (see Chapter 9). This likely permits improved absorption of topical steroids to maintain control of inflammation and prevent or delay recurrence of hyperkeratosis.

## Limitations of the literature

A variety of studies have evaluated alternatives to topical steroids for LS treatment. Most of these publications have major design flaws, relying on subjective rather than objective outcome measures and short-term follow-up. There is no reliable information about the impact of alternatives to topical steroids on prevention of architecture change and SCC risk reduction. Until consensus-based core outcome sets for clinical signs, symptoms, and QoL have been established, clinical studies evaluating alternatives to topical steroids will likely fail to answer key questions on efficacy, harms, and durability.

## Conclusions and recommendations

Many patients and clinicians would like to use alternatives to steroids for initial treatment and long-term maintenance of LS. However, these desires must be viewed in the context of detrimental consequences from undertreating LS. For some products, financial incentives create the potential for exploitation of LS patients' hopes for a cure. An array of medical and procedural approaches may be useful to improve LS symptom control when there are signs of steroid overuse or to address hyperkeratosis to improve effectiveness of maintenance therapy.

- Topical calcineurin inhibitors and retinoids are inferior to topical steroids in primary management of LS, but in specific situations and populations may have utility as adjunctive therapy.
- Several systemic therapies such as acitretin, hydroxychloroquine, and topical JAK-inhibitors show promise, but more evidence is required to support their use.
- Autologous platelet-rich plasma and autologous adipose-derived stem cells do not appear to have therapeutic benefit for LS beyond placebo.

## References

1. Hampton PJ, Reynolds NJ. Calcineurin inhibitors for the treatment of skin disease: how do they work?. *Clin Exp Allergy*. 2005;35(5):549-550. doi:10.1111/j.1365-2222.2005.02255.x
2. Goldstein AT, Creasey A, Pfau R, Phillips D, Burrows LJ. A double-blind, randomized controlled trial of clobetasol versus pimecrolimus in patients with vulvar lichen sclerosus. *J Am Acad Dermatol*. 2011;64(6):e99-e104. doi:10.1016/j.jaad.2010.06.011

3. Patel TS, Greer SC, Skinner RB Jr. Cancer concerns with topical immunomodulators in atopic dermatitis: overview of data and recommendations to clinicians. *Am J Clin Dermatol.* 2007;8(4):189-194. doi:10.2165/00128071-200708040-00001
4. Meingassner JG, Aschauer H, Stuetz A, Billich A. Pimecrolimus permeates less than tacrolimus through normal, inflamed, or corticosteroid-pretreated skin. *Exp Dermatol.* 2005;14(10):752-757. doi:10.1111/j.1600-0625.2005.00354.x
5. Chi CC, Kirtschig G, Baldo M, Brackenbury F, Lewis F, Wojnarowska F. Topical interventions for genital lichen sclerosis. *Cochrane Database Syst Rev.* 2011;2011(12):CD008240. Published 2011 Dec 7. doi:10.1002/14651858.CD008240.pub2
6. Funaro D, Lovett A, Leroux N, Powell J. A double-blind, randomized prospective study evaluating topical clobetasol propionate 0.05% versus topical tacrolimus 0.1% in patients with vulvar lichen sclerosis. *J Am Acad Dermatol.* 2014;71(1):84-91. doi:10.1016/j.jaad.2014.02.019
7. Pergialiotis V, Bellos I, Billiou EC, et al. An arm-based network meta-analysis on treatments for vulvar lichen sclerosis and a call for development of core outcome sets. *Am J Obstet Gynecol.* 2020;222(6):542-550.e6. doi:10.1016/j.ajog.2019.10.095
8. Virgili A, Corazza M, Bianchi A, Mollica G, Califano A. Open study of topical 0.025% tretinoin in the treatment of vulvar lichen sclerosis. One year of therapy. *J Reprod Med.* 1995;40(9):614-618.
9. Borghi A, Corazza M, Minghetti S, Virgili A. Topical tretinoin in the treatment of vulvar lichen sclerosis: an advisable option?. *Eur J Dermatol.* 2015;25(5):404-409. doi:10.1684/ejd.2015.2595
10. Borghi A, Minghetti S, Toni G, Virgili A, Corazza M. Combined therapy in vulvar lichen sclerosis: does topical tretinoin improve the efficacy of mometasone furoate?. *J Dermatolog Treat.* 2017;28(6):559-563. doi:10.1080/09546634.2016.1277178
11. Friedrich EG Jr, Kalra PS. Serum levels of sex hormones in vulvar lichen sclerosis, and the effect of topical testosterone. *N Engl J Med.* 1984;310(8):488-491. doi:10.1056/NEJM198402233100803
12. Bracco GL, Carli P, Sonni L, et al. Clinical and histologic effects of topical treatments of vulval lichen sclerosis. A critical evaluation. *J Reprod Med.* 1993;38(1):37-40.
13. Sideri M, Origoni M, Spinaci L, Ferrari A. Topical testosterone in the treatment of vulvar lichen sclerosis. *Int J Gynaecol Obstet.* 1994;46(1):53-56. doi:10.1016/0020-7292(94)90309-3
14. Paslin D. Androgens in the topical treatment of lichen sclerosis. *Int J Dermatol.* 1996;35(4):298-301. doi:10.1111/j.1365-4362.1996.tb03009.x
15. Cattaneo A, Carli P, De Marco A, et al. Testosterone maintenance therapy. Effects on vulvar lichen sclerosis treated with clobetasol propionate. *J Reprod Med.* 1996;41(2):99-102.
16. Bornstein J, Heifetz S, Kellner Y, Stolar Z, Abramovici H. Clobetasol dipropionate 0.05% versus testosterone propionate 2% topical application for severe vulvar lichen sclerosis. *Am J Obstet Gynecol.* 1998;178(1 Pt 1):80-84. doi:10.1016/s0002-9378(98)70631-3
17. Hargis A, Ngo M, Kraus CN, Mauskar M. Systemic Therapy for Lichen Sclerosis: A Systematic Review. *J Low Genit Tract Dis.* 2024;28(1):84-90. doi:10.1097/LGT.0000000000000775
18. DiSepio D, Malhotra M, Chandraratna RA, Nagpal S. Retinoic acid receptor-nuclear factor-interleukin 6 antagonism. A novel mechanism of retinoid-dependent inhibition of a keratinocyte hyperproliferative differentiation marker. *J Biol Chem.* 1997;272(41):25555-25559. doi:10.1074/jbc.272.41.25555
19. Romppanen U, Tuimala R, Ellmén J, Lauslahti K. Orale Behandlung der Dystrophie der Vulva mit einem aromatischen Retinoid, Etretinat [Oral treatment of vulvar dystrophy with an aromatic retinoid, etretinate]. *Geburtshilfe Frauenheilkd.* 1986;46(4):242-247. doi:10.1055/s-2008-1035907
20. Mørk NJ, Jensen P, Hoel PS. Vulval lichen sclerosis et atrophicus treated with etretinate (Tigason). *Acta Derm Venereol.* 1986;66(4):363-365.
21. Romppanen U, Rantala I, Lauslahti K, Reunala T. Light- and electron-microscopic findings in lichen sclerosis of the vulva during etretinate treatment. *Dermatologica.* 1987;175(1):33-40. doi:10.1159/000248779
22. Niinimäki A, Kallioinen M, Oikarinen A. Etretinate reduces connective tissue degeneration in lichen sclerosis et atrophicus. *Acta Derm Venereol.* 1989;69(5):439-442.
23. Neuhofer J, Fritsch P. Treatment of localized scleroderma and lichen sclerosis with etretinate. *Acta Derm Venereol.* 1984;64(2):171-174.
24. Bousema MT, Romppanen U, Geiger JM, et al. Acitretin in the treatment of severe lichen sclerosis et atrophicus of the vulva: a double-blind, placebo-controlled study. *J Am Acad Dermatol.* 1994;30(2 Pt 1):225-231. doi:10.1016/s0190-9622(94)70021-4
25. Ranun A, Pearson DR. Acitretin therapy for vulvar lichen sclerosis complicated by recurrent squamous cell carcinoma. *JAAD Case Rep.* 2020;8:53-55. Published 2020 Dec 17. doi:10.1016/j.jidcr.2020.12.009

26. Jeffrey P. Callen and Carol L. Kulp-Shorten, Methotrexate. Wolverton S and Wu J. *Comprehensive Dermatologic Drug Therapy*. 4th ed. Elsevier;2021
27. Thomas S, Fisher KH, Snowden JA, Danson SJ, Brown S, Zeidler MP. Methotrexate Is a JAK/STAT Pathway Inhibitor. *PLoS One*. 2015;10(7):e0130078. Published 2015 Jul 1. doi:10.1371/journal.pone.0130078
28. Kreuter A, Tigges C, Gaifullina R, Kirschke J, Altmeyer P, Gambichler T. Pulsed high-dose corticosteroids combined with low-dose methotrexate treatment in patients with refractory generalized extragenital lichen sclerosis. *Arch Dermatol*. 2009;145(11):1303-1308. doi:10.1001/archdermatol.2009.235
29. Nayeemuddin F, Yates VM. Lichen sclerosis et atrophicus responding to methotrexate. *Clin Exp Dermatol*. 2008;33(5):651-652. doi:10.1111/j.1365-2230.2008.02721.x
30. Cuellar-Barboza A, Basyam AM, Ghamrawi RI, Aickara D, Feldman SR, Pichardo RO. Methotrexate for the treatment of recalcitrant genital and extragenital lichen sclerosis: A retrospective series. *Dermatol Ther*. 2020;33(4):e13473. doi:10.1111/dth.13473
31. Jain S, Pyle HJ, Evans JC, Gao W, Mauskar MM. Cutaneous manifestations of systemic methotrexate toxicity. *JAAD Int*. 2024;15:179-181. Published 2024 Feb 28. doi:10.1016/j.jidint.2024.02.013
32. Kremer JM. The changing face of therapy for rheumatoid arthritis. *Rheum Dis Clin North Am*. 1995;21(3):845-852.
33. Schnabel A, Gross WL. Low-dose methotrexate in rheumatic diseases--efficacy, side effects, and risk factors for side effects. *Semin Arthritis Rheum*. 1994;23(5):310-327. doi:10.1016/0049-0172(94)90027-2
34. Rademaker M, Gupta M, Andrews M, et al. The Australasian Psoriasis Collaboration view on methotrexate for psoriasis in the Australasian setting. *Australas J Dermatol*. 2017;58(3):166-170. doi:10.1111/ajd.12521
35. Sardana K, Sinha S, Sachdeva S. Hydroxychloroquine in Dermatology and Beyond: Recent Update. *Indian Dermatol Online J*. 2020;11(3):453-464. Published 2020 May 10. doi:10.4103/idoj.IDOJ\_280\_20
36. Akpala CO, Tekin B, Torgerson RR, Wetter DA, Nguyen GH. Treatment of lichen sclerosis with hydroxychloroquine: a Mayo Clinic experience. *Int J Dermatol*. Published online July 19, 2024. doi:10.1111/ijd.17394
37. Yusuf IH, Sharma S, Luqmani R, Downes SM. Hydroxychloroquine retinopathy. *Eye (Lond)*. 2017;31(6):828-845. doi:10.1038/eye.2016.298
38. Marmor MF, Kellner U, Lai TY, Melles RB, Mieler WF; American Academy of Ophthalmology. Recommendations on Screening for Chloroquine and Hydroxychloroquine Retinopathy (2016 Revision). *Ophthalmology*. 2016;123(6):1386-1394. doi:10.1016/j.ophtha.2016.01.058
39. Mendoza FA, Piera-Velazquez S, Jimenez SA. Tyrosine kinases in the pathogenesis of tissue fibrosis in systemic sclerosis and potential therapeutic role of their inhibition. *Transl Res*. 2021;231:139-158. doi:10.1016/j.trsl.2021.01.001
40. Terlou A, Santegoets LA, van der Meijden WI, et al. An autoimmune phenotype in vulvar lichen sclerosis and lichen planus: a Th1 response and high levels of microRNA-155. *J Invest Dermatol*. 2012;132(3 Pt 1):658-666. doi:10.1038/ijd.2011.369
41. Bao C, Xu Q, Xiao Z, et al. Abrocitinib as a novel treatment for lichen sclerosis. *Br J Dermatol*. 2023;189(1):136-138. doi:10.1093/bjd/ljad129
42. Liu L, Zhan Y, Shi Y, et al. Bullosis lichen sclerosis-generalized morphea overlap syndrome improved by tofacitinib. *Dermatol Ther*. 2022;35(12):e15942. doi:10.1111/dth.15942
43. Zundell MP, Al-Dehneem R, Song T, Yousif J, Gottlieb AB. Novel Clinical Applications of Topical Ruxolitinib: A Case Series. *J Drugs Dermatol*. 2024;23(3):188-190. doi:10.36849/jdd.7696
44. Xiong X, Chen R, Wang L, et al. Treatment of plasma cell balanitis associated with male genital lichen sclerosis using abrocitinib. *JAAD Case Rep*. 2024;46:85-88. Published 2024 Feb 29. doi:10.1016/j.jidcr.2024.02.010
45. Su M, Liu H, Ran Y. Successfully treated extragenital lichen sclerosis in a 2-year-old boy by baricitinib assessed by dermoscopy: A case report. *Dermatol Ther*. 2022;35(9):e15712. doi:10.1111/dth.15712
46. Wang X, Shi Y, Liu Y. Baricitinib treatment of extragenital lichen sclerosis caused by COVID-19 vaccine. *Australas J Dermatol*. 2023;64(4):574-576. doi:10.1111/ajd.14172
47. Chang PH, Huang SF, Chang PS, Yu Y. Safety considerations of systemic Janus kinase inhibitors in atopic dermatitis applications. *J Dermatol*. 2021;48(11):1631-1639. doi:10.1111/1346-8138.16116
48. Bulbul Baskan E, Turan H, Tunali S, Toker SC, Saricaoglu H. Open-label trial of cyclosporine for vulvar lichen sclerosis. *J Am Acad Dermatol*. 2007;57(2):276-278. doi:10.1016/j.jaad.2007.03.006
49. Sahil Sekhon, Tina Bhutani, John Y.M. Koo, Cyclosporine. *Wolverton S and Wu J. Comprehensive Dermatologic Drug Therapy*. 4th ed. Elsevier;2021
50. Amor KT, Ryan C, Menter A. The use of cyclosporine in dermatology: part I. *J Am Acad Dermatol*. 2010;63(6):925-948. doi:10.1016/j.jaad.2010.02.063
51. Feig JL, Gribetz ME, Lebwohl MG. Chronic lichen sclerosis successfully treated with intralesional adalimumab. *Br J Dermatol*. 2016;174(3):687-689. doi:10.1111/bjd.14212

52. Lowenstein EB, Zeichner JA. Intralesional adalimumab for the treatment of refractory balanitis xerotica obliterans. *JAMA Dermatol.* 2013;149(1):23-24. doi:10.1001/2013.jamadermatol.39
53. Manuepillai N, Saunders H, Veysey E. Management of severe vulvar lichen sclerosus with adalimumab. *Australas J Dermatol.* 2022;63(2):248-250. doi:10.1111/ajd.13814
54. Diab M, Coloe JR, Magro C, Bechtel MA. Treatment of recalcitrant generalized morphea with infliximab. *Arch Dermatol.* 2010;146(6):601-604. doi:10.1001/archdermatol.2010.120
55. Jacquelyn Majerowski and Kenneth B. Gordon, Tumor Necrosis Factor Inhibitors. Wolverton S and Wu J. *Comprehensive Dermatologic Drug Therapy.* 4th ed. Elsevier;2021
56. Wu C, Zou M, Xiong Y, et al. Short- and long-term efficacy of focused ultrasound therapy for non-neoplastic epithelial disorders of the vulva. *BJOG.* 2017;124 Suppl 3:87-92. doi:10.1111/1471-0528.14747
57. Jia R, Wu C, Tang X, et al. Comparison of the efficacy of focused ultrasound at different focal depths in treating vulvar lichen sclerosus. *Int J Hyperthermia.* 2023;40(1):2172220. doi:10.1080/02656736.2023.2172220
58. Prodromidou A, Chatziioannou E, Daskalakis G, Stergios K, Pergaliotis V. Photodynamic Therapy for Vulvar Lichen Sclerosus-A Systematic Review. *J Low Genit Tract Dis.* 2018;22(1):58-65. doi:10.1097/LGT.0000000000000362
59. Gerkowicz A, Szczepanik-Kulak P, Krasowska D. Photodynamic Therapy in the Treatment of Vulvar Lichen Sclerosus: A Systematic Review of the Literature. *J Clin Med.* 2021;10(23):5491. Published 2021 Nov 23. doi:10.3390/jcm10235491
60. Sarvajnamurthy S, Suryanarayan S, Budamakuntala L, Suresh DH. Autologous platelet rich plasma in chronic venous ulcers: study of 17 cases. *J Cutan Aesthet Surg.* 2013;6(2):97-99. doi:10.4103/0974-2077.112671
61. Sclafani AP. Safety, efficacy, and utility of platelet-rich fibrin matrix in facial plastic surgery. *Arch Facial Plast Surg.* 2011;13(4):247-251. doi:10.1001/archfacial.2011.3
62. Chen L, Yang X, Huang G, et al. Platelet-rich plasma promotes healing of osteoporotic fractures. *Orthopedics.* 2013;36(6):e687-e694. doi:10.3928/01477447-20130523-10
63. Paganelli A, Contu L, Condorelli A, et al. Platelet-Rich Plasma (PRP) and Adipose-Derived Stem Cell (ADSC) Therapy in the Treatment of Genital Lichen Sclerosus: A Comprehensive Review. *Int J Mol Sci.* 2023;24(22):16107. Published 2023 Nov 9. doi:10.3390/ijms242216107
64. Medina Garrido C, Cano García A, de la Cruz Cea L, Oreja Cuesta AB. Mid-term symptomatic relief after platelet-rich plasma infiltration in vulvar lichen sclerosus. *Arch Dermatol Res.* 2023;315(6):1527-1532. doi:10.1007/s00403-023-02529-1
65. Behnia-Willison F, Pour NR, Mohamadi B, et al. Use of Platelet-rich Plasma for Vulvovaginal Autoimmune Conditions Like Lichen Sclerosus. *Plast Reconstr Surg Glob Open.* 2016;4(11):e1124. Published 2016 Nov 23. doi:10.1097/GOX.0000000000001124
66. Goldstein AT, Mitchell L, Govind V, Heller D. A randomized double-blind placebo-controlled trial of autologous platelet-rich plasma intradermal injections for the treatment of vulvar lichen sclerosus. *J Am Acad Dermatol.* 2019;80(6):1788-1789. doi:10.1016/j.jaad.2018.12.060
67. Almadori A, Hansen E, Boyle D, et al. Fat Grafting Improves Fibrosis and Scarring in Vulvar Lichen Sclerosus: Results From a Prospective Cohort Study. *J Low Genit Tract Dis.* 2020;24(3):305-310. doi:10.1097/LGT.0000000000000520
68. Boero V, Brambilla M, Sipio E, et al. Vulvar lichen sclerosus: A new regenerative approach through fat grafting. *Gynecol Oncol.* 2015;139(3):471-475. doi:10.1016/j.ygyno.2015.10.014
69. Casabona F, Gasparini G, Cazzani E, Barbazza A, Casabona F, Carmisciano L, Parodi A. Improvement in quality of life and sexual function in patients affected by vulvar lichen sclerosus treated with combined autologous platelet-rich plasma and fat grafting. *Eur J Dermatol.* 2023 Jun 1;33(3):249-254. doi: 10.1684/ejd.2023.4480. PMID: 37594331.
70. Gil-Villalba A, Ayen-Rodriguez A, Naranjo-Diaz MJ, Ruiz-Villaverde R. Laser Therapy for Vulvar Lichen Sclerosus, a Systematic Review. *Life (Basel).* 2023;13(11):2146. Published 2023 Oct 31. doi:10.3390/life13112146
71. Hantash BM, Bedi VP, Struck SK, Chan KF. Immunohistochemical evaluation of the heat shock response to nonablative fractional resurfacing. *J Biomed Opt.* 2010;15(6):068002. doi:10.1117/1.3526355
72. Mitchell L, Goldstein AT, Heller D, et al. Fractionated Carbon Dioxide Laser for the Treatment of Vulvar Lichen Sclerosus: A Randomized Controlled Trial. *Obstet Gynecol.* 2021;137(6):979-987. doi:10.1097/AOG.0000000000004409
73. Krause E, Neumann S, Maier M, et al. LASER treatment in gynaecology -A randomized controlled trial in women with symptomatic lichen sclerosus. *Eur J Obstet Gynecol Reprod Biol.* 2023;287:171-175. doi:10.1016/j.ejogrb.2023.06.003
74. Lee A, Lim A, Fischer G. Fractional carbon dioxide laser in recalcitrant vulvar lichen sclerosus. *Australas J Dermatol.* 2016;57(1):39-43. doi:10.1111/ajd.12305
75. Hobson JG, Ibrahim SF, Mercurio MG. Recalcitrant Vulvar Lichen Sclerosus Treated With Erbium YAG Laser. *JAMA Dermatol.* 2019;155(2):254-256. doi:10.1001/jamadermatol.2018.4461

# Neoplasia arising in lichen sclerosis

*Lois Eva, Shatavisha Dasgupta, Irene van der Avoort, Mario Preti,  
James Scurry, Tania Day*

**V**ulvar squamous cell carcinoma (SCC) is a preventable disease with two main carcinogenic pathways: 1) human papillomavirus (HPV)-associated and 2) HPV-independent (HPV-I) and usually arising from lichen sclerosis (LS). The precursor lesion of HPV-I SCC, historically termed differentiated vulvar intraepithelial neoplasia (dVIN), is now increasingly labeled HPV-I VIN.<sup>1</sup> The precursor of HPV-associated SCC is high-grade squamous intraepithelial lesion (HSIL), historically called usual VIN. Etiology is determined through histopathologic and immunohistochemical assessment. HPV-I and HPV-associated squamous neoplasia each have their own prevention, diagnosis, management, prognosis, and surveillance considerations. An important aim of LS follow-up visits is to identify and treat lesions when they are more easily manageable and then increase the rigor and frequency of surveillance for this higher risk cohort.

## Etiology of squamous neoplasia in lichen sclerosis

The relative incidence of HPV-I versus HPV-associated disease is changing over time with more accurate diagnosis of etiology, demographic shifts, HPV vaccination, prevalence of immunosuppression, and improvements in clinical care of LS (see Chapter 1).<sup>1-3</sup> The traditional concept of HPV-associated neoplasia occurring primarily in younger women as intraepithelial disease and progressing infrequently to cancer is now less true.<sup>2,4,5</sup> As the unvaccinated cohort ages, dual burdens of long-term tobacco use and chronic local or systemic immunosuppressive conditions contribute to emergence of HSIL and HPV-associated cancers in later life and associated with LS.

Compared to HPV-associated SCC matched for disease stage, HPV-I cancers have poorer response to treatment, higher rates of recurrence and greater risk of death from disease.<sup>6-11</sup> Compounding the prognostic distinction, HPV-I cancers are also more likely to present at an advanced stage.<sup>10</sup> Within the category of HPV-I neoplasia, there appear to be at least two carcinogenic pathways stratified by mutated vs wild-type p53 immunohistochemistry (IHC). Among HPV-I SCC, the relative frequency of mutant p53 is 76-80%, p53 wild-type 18-26%, and unclassifiable 1%.<sup>1,12,13</sup> The 5-year survival for p53-mutant SCC is 48%, compared to 64% for p53-wild-type and 83% for HPV-associated cancer.<sup>10</sup> The rate of progression from intraepithelial disease to cancer also varies by these classifications. The 10-year cancer risk of HSIL is 8%, while the progression risk for HPV-I p53 wild-type is 27.8% and HPV-I p53 mutant VIN is 67.4%.<sup>14</sup>



Squamous neoplasia cases are unclassifiable by initial histopathology and IHC in 0.3–4%.<sup>1,12,13</sup> Some of these are p16 non-block positive but with HSIL-like morphology and p53.<sup>11,13,15,16</sup> Others represent ‘double-positives’ with IHC supporting both HPV-associated and HPV-I etiology.<sup>12,14,17,18</sup> Anecdotally, these latter patients have severe or uncontrolled LS, positive oncogenic HPV, and prior lower genital tract HSIL. Given the paucity of data on apparent dual-etiology lesions, caution dictates that clinical management mirror that of HPV-I VIN rather than HSIL.<sup>17</sup>

Multiple case reports and series have described ‘dVIN’ or SCC occurring without clinical and/or histologic evidence of LS. Many of these publications arise from datasets or cases that pre-date routine use of IHC to determine neoplastic etiology, meaning these cohorts include HPV-associated disease.<sup>1,19–21</sup> Recent clinicopathologic work identifies that biopsies from obvious clinical LS are often non-diagnostic due to lack of sclerosis, and that pathologists sometimes mistake benign skin conditions for neoplasia.<sup>19,22–24</sup> Studies integrating expert clinical examination, review of biopsies previous and subsequent to neoplasia, and routine p16 and p53 suggest that lichen planus (LP) and lichen simplex chronicus (LSC) are associated with HPV-associated but not HPV-I neoplasia.<sup>16,18,25</sup> The other major cancer-causing dermatosis on genital skin is hidradenitis suppurativa (HS), in which SCC is a rare complication attributed to the combination of scar, chronic inflammation, and local immune dysfunction.<sup>26,27</sup>

## Prevention strategies for vulvar squamous neoplasia

### General health modifications and vulvar awareness

Tobacco cessation has manifold benefits for health and longevity. Tobacco use appears to increase the risk of vulvar SCC development and recurrence in both HPV-I and HPV-associated disease.<sup>19,28</sup> Systemic immunosuppression contributes to development and recurrence of vulvar neoplasia. Modification of immunosuppressant medication regimens, in collaboration with involved medical specialists or the transplant team, may lessen the burden of vulvar disease.<sup>29</sup>

Public awareness of vulvovaginal conditions is poor. Several LS advocacy groups manage social media accounts and websites to educate and de-stigmatize, link patients to support groups, and lobby government for funding in research, education, and women’s health care. The ISSVD and other medical organizations promote and support campaigns on vulvar awareness and post expert-generated, patient-oriented content. The impact these efforts make on community knowledge and help-seeking is unclear. Clinicians can instruct and support patients in vulvar awareness and self-examination for skin thickening or non-healing areas (see Chapter 3).<sup>30,31</sup> The format of a once-monthly self-assessment is familiar to many women after widespread campaigns on breast health. However, this activity must be paired with a mechanism for earlier medical review if a problem is identified.

Several survey studies document poor exposure to and knowledge of vulvovaginal conditions in specialist training programs.<sup>32,33</sup> In Italy, 35% of gynecology trainees never attended a vulvar clinic and 60% lacked confidence in managing common presentations, especially preinvasive disease. Among US-based members of ISSVD, 79% report being primarily self-taught, with only 19% provided with vulvovaginal disease education in specialist training



and 11% during subspecialty fellowship programs.<sup>33</sup> Survey participants agreed that medical school curricula should include 4 basic competencies in normal anatomy, HPV vaccination, speculum examination, and microscopy. The authors identified the need for structured curriculum implementation with emphasis on dermatologic disorders for gynecology trainees and vaginal disorders and pain syndromes for dermatology trainees. Improved medical competence in identification, initial management, and referral of vulvovaginal conditions is fundamental to efforts to eliminate vulvar cancer.

### **Strategies specific to prevention of HPV-associated neoplasia**

Universal school-based HPV vaccination has the potential to nearly eradicate HPV-associated neoplasia via primary prevention, but implementation has been variable across countries.<sup>34</sup> Adult vaccination provides an additional opportunity for primary prevention. While countries vary in their recommendations and funding for catch-up vaccination, clinicians can identify unvaccinated women at risk of HPV acquisition and discuss the benefits, costs, and limitations of adult immunization. Patients awaiting organ transplant or considering immunosuppressive medications are a target group for HPV vaccination.<sup>35–37</sup>

Vaccination plays a role in secondary prevention when administered to women treated for HSIL.<sup>38</sup> The initial studies suggesting reduction in recurrence risk occurred in women undergoing excisional treatment of cervical HSIL.<sup>39</sup> The rate of subsequent HSIL and need for repeat excision was 60–80% lower in women vaccinated peri-treatment. A study of quadrivalent vaccination after surgical treatment of vulvar HSIL showed fewer subsequent lesions due to the same HPV type, but no significant difference in overall recurrence.<sup>40</sup> A randomized trial of adults with vulvar or anal HSIL aged 27 to 69, of whom 40% were HIV+, was stopped after interim analysis showed no difference in recurrence after nonavalent HPV vaccination.<sup>41</sup> Compared to women with vulvar or anal disease, women with cervical disease are younger, healthier, more likely to have complete surgical resection of HSIL, and more likely to be exposed to new HPV types, all of which better align with vaccine mechanisms.<sup>42</sup> The potential longer-term impact of vaccination on frequency and severity of vulvar and anal recurrences is unknown. Clinicians may offer HPV vaccination to women with vulvar HSIL citing impacts on HPV acquisition, autoinoculation, and cervical disease, even if risk reduction for vulvovaginal recurrence has not been demonstrated.<sup>38,42</sup>

Initial and maintenance therapy of LS with topical corticosteroids does not appear to increase the risk of recurrent HSIL.<sup>43</sup> Given the crucial role LS treatment plays in prevention of HPV-I cancer, an effective topical steroid regimen should continue regardless of diagnosis or management of HPV-associated disease.<sup>21,44–46</sup> Women with comorbid LS and HSIL represent a high-risk group for vulvar SCC and ideally undertake long-term surveillance in a setting that provides colposcopy, digital anorectal examination, and expertise in managing vulvar dermatoses.<sup>16,43</sup>

### **Strategies specific to prevention of HPV-independent neoplasia**

There is an unacceptable delay in diagnosis for many women with LS. Common to many genital dermatoses, this relates to insufficient access to high quality medical care, deferral

of care-seeking by patients, practitioner and health system barriers to genital examination, and poor provider knowledge of vulvovaginal disease. Patients report a dismissive attitude from primary care providers and specialists, often manifesting as repetitive advice to purchase over-the-counter antifungals or to apply time-limited topical steroids in absence of a diagnosis.<sup>47</sup> Recognition of LS at the time of SCC diagnosis unfortunately still occurs, underscoring the need for improvements in public health and medical education systems worldwide.<sup>30,32</sup>

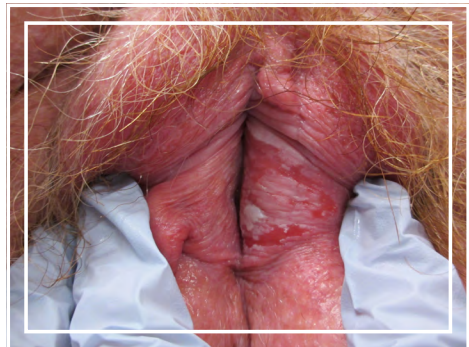Conversely, when women with recent development of LS present promptly to care and receive an immediate correct diagnosis and treatment, the negative sequelae of LS are largely avoidable (see Chapter 6). Topical corticosteroids reduce the inflammation, cell turnover, and fibrosis that drive accumulation of carcinogenic mutations. Counseling around the potential for neoplasia may promote patient detection of skin changes they might then bring to medical attention.

Routine surveillance of LS allows clinicians to titrate topical steroids and biopsy treatment-resistant areas suspicious for neoplasia. Ten percent of patients with HPV-I VIN do not report symptoms.<sup>18,19</sup> Recognition of lesions in a field of abnormal skin may be challenging. Continuity of care, careful inspection, and routine photography all aid in detection of interval lesion development.<sup>48,49</sup> Treatment of small areas of preinvasive disease is less morbid and may be accomplished by a wider range of practitioners, compared to extensive lesions that require partial vulvectomy and flap repair.<sup>14,50,51</sup> Adherence to topical steroids is associated with a lower risk of SCC development in patients with HPV-I VIN.<sup>19,52</sup>

## Diagnosis of squamous neoplasia

### Clinical examination

Squamous precursor lesions vary in color, morphology, surface texture, size, and demarcation from the surrounding abnormal skin (Fig 1). HPV-I precursors are white plaques in 70-75% of cases and pink to red patches or plaques in 25-40%, with more than one morphology present in 10%.<sup>18,19</sup> The surface may have a cobblestone appearance or a roughened, eroded, or verruciform texture.<sup>18,53</sup> HPV-I neoplasia is multifocal in 16-18% and occurs at the periclititoris or labia minora in 39-57%, labium majus in 15-36%, vestibule or posterior fourchette in 18%, and perineum/perianus in 9-21%.<sup>18,19</sup> Isolated HPV-I VIN occurs in 25-60%, with the remainder of cases occurring adjacent to SCC.<sup>18,19</sup> Lesion appearance does not reliably predict HPV-I versus HPV-associated etiology. While HSIL in LS sometimes shows typical findings of acetowhite change or a multi-



**FIGURE 1.** HPV-independent (HPV-I) VIN in a field of LS with irregular red patches and white plaques on inner left labium minus and interlabial sulcus.

color verruciform appearance, it also may appear as white, pink, or red plaques or patches on a background of LS (Fig 2).<sup>16</sup>

Non-healing fissures, erosions, or ulcers and treatment-resistant plaques on background of LS should provoke vulvar biopsy (see Chapters 4 and 9). Lesion recognition is difficult when LS is superinfected or inadequately controlled. Involvement of an experienced vulvar clinician, aggressive treatment of LS and comorbid conditions, and short interval review may clarify the site and number of biopsies required. Clinicians lay the groundwork for effective clinicopathologic correlation by labeling a diagram or photograph with biopsy sites, identifying the concern for HSIL or HPV-I VIN on the pathology request form, and communicating with the pathologist if results are inconsistent with the clinical scenario.<sup>54</sup>

Most biopsies taken for treatment-resistant plaques result as hypertrophic LS, with HSIL, unusual acanthotic lesions, HPV-I VIN, and superficial SCC less often identified. Biopsy of eroded areas most often shows erosive LP or non-specific erosion, but these may be difficult to distinguish from HSIL and HPV-I VIN if IHC is not done.<sup>24,55</sup> Clinician recognition that pathologic diagnosis of HPV-I VIN is challenging promotes discussion about cases and multidisciplinary consensus on the treatment plan.<sup>56,57</sup>

A diagnosis of vulvar HSIL should precipitate examination of the lower genital tract to include the urethral meatus, vagina, cervix (if present), and anus. Some guidelines recommend routine cervical or vaginal HPV and cytology.<sup>58</sup> Multifocal disease is present in 22% of women with LS and HSIL, and more than 20% of women referred to high resolution anoscopy clinics have multizonal disease affecting cervix, vulva, vagina, and/or perianus.<sup>16,59,60</sup>

Examination features that raise suspicion for cancer include a mass that is firm, fungating, simultaneously raised and ulcerated, friable, and different to the surrounding precursor lesion. The subcutaneous tissue underlying the mass may appear discolored and feel indurated. Areas suspicious for cancer should not be excised to obtain diagnosis, as this precludes sentinel node biopsy.<sup>58</sup> Instead, clinicians may obtain one or more deep punch or forceps biopsies from the most worrisome area(s) and send to pathology as an urgent evaluation with notation of concern for invasive disease.<sup>61</sup>

## Histopathology – Evaluation of basal layer atypia

The diagnosis of squamous neoplasia relies on assessment of basal nuclear atypia. The criteria for atypia are 1) chromatin abnormality, 2) nuclear enlargement, 3) nuclear pleomorphism, and

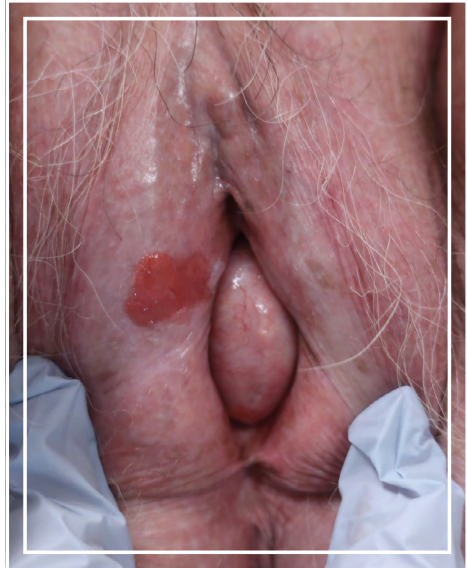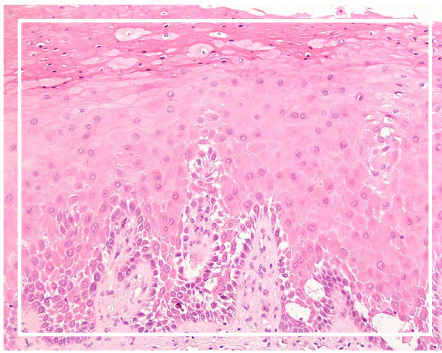


FIGURE 2. HSIL and HPV-associated SCC in a field of LS.

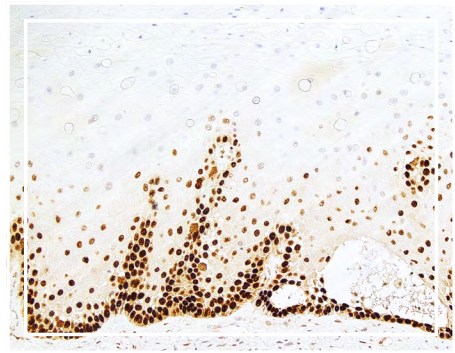
4) mitotic activity. The most common chromatin abnormality is hyperchromasia, in which chromatic crowding produces dark staining. Less common are vesicular nuclei that show sparse chromatin, intranuclear vacuoles, and multiple or bizarre nucleoli.<sup>54,62</sup> Nuclear enlargement is assessed in comparison to normal basal cell nuclei. Nuclear pleomorphism is variation in shape and size of nuclei, which may be large and ovoid or elongated into a spindle shape. Increased mitoses often occur in squamous neoplasia. Abnormal mitoses are more common in HPV-associated rather than HPV-I disease and show dispersed or clumped chromatin and tripolar, tetrapolar, or tripartite morphology with rod- or dot-shaped pieces of extra chromosomes separate to the main spindle.<sup>63</sup> While basal atypia is the essential feature of VIN, it may be subtle and subject to interobserver variation. Architectural and maturational abnormalities may be more obvious to the pathologist, prompting a closer look at the basal layer and request for IHC.

### Histopathology – Evaluation of morphology and dermal features

Historically, pathologists relied on basaloid morphology to indicate HSIL and keratinizing morphology to diagnose HPV-I VIN. However, HSIL is keratinizing in 10% of cases and HPV-I VIN is basaloid in 20% so this strategy is unreliable.<sup>1</sup> The traditional description of HPV-I VIN is of acanthosis with unusual irregular rete ridges and maturation across the epithelium from the basal layer to stratum corneum (Fig 3).<sup>53</sup> The stratum corneum shows confluent parakeratosis or thick hyperkeratosis associated with hypergranulosis. The prickle cell layer shows premature maturation seen as a rapid transition from basal cells with scant cytoplasm to squamous cells with abundant eosinophilic cytoplasm. These suprabasilar cells also show vesicular nuclei with large eosinophilic nucleoli and visible intracellular prickles, representing diminished numbers of desmosomes. When loss of desmosomes is complete, the epithelium becomes acantholytic and appears to disintegrate.<sup>18,54</sup> Parakeratosis, ‘cobblestone’ epithelial appearance from dyskeratosis and spongiosis, abnormal chromatin, angulated nuclei, and altered cellular alignment are reproducibly recognized by gynecologic pathologists.<sup>64</sup> Keratin pearls and thick parakeratosis correlate with the development of SCC.<sup>64</sup> While the majority of HPV-I VIN is acanthotic, it may also appear as atrophic, eroded, or subtle.<sup>18</sup> The inflammatory infiltrate and dermal collagen appearance are variable across morphologic types.



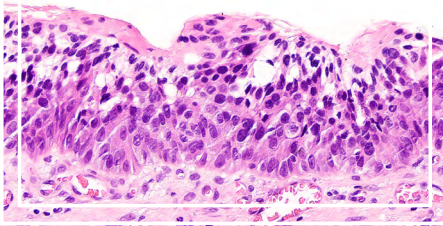
**FIGURE 3a.** Classic HPV-I VIN with thick parakeratosis, premature maturation, irregular acanthosis, acantholysis, nuclear atypia, and minimal dermal sclerosis; H&E x100.



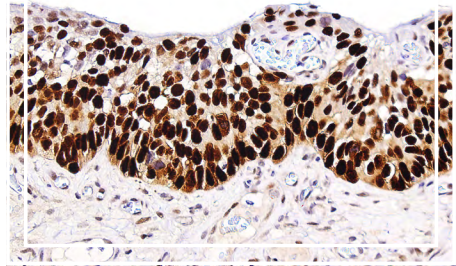
**FIGURE 3b.** Classic HPV-I VIN with basal overexpressed p53 pattern; x100.



The basaloid variant of HPV-I VIN is a mimic for the traditional description of HSIL and shows little change in cell appearance between basal and suprabasilar layers (Fig 4). It often is mildly acanthotic with reduced or absent rete ridges. This morphologic type appears to progress more often and rapidly to SCC than keratinizing HPV-I VIN.<sup>14,65</sup> There is an intermediate variant with more maturation than basaloid but less than standard keratinizing type. Regenerative erosive LP may show marked loss of maturation, nuclear enlargement, and mitotic activity mimicking HSIL or non-keratinizing HPV-I VIN.<sup>24</sup> Features supporting neoplasia in this situation include slight acanthosis, a thin layer of parakeratosis, biopsy location where erosive LP is unlikely to occur, and prior vulvar SCC.

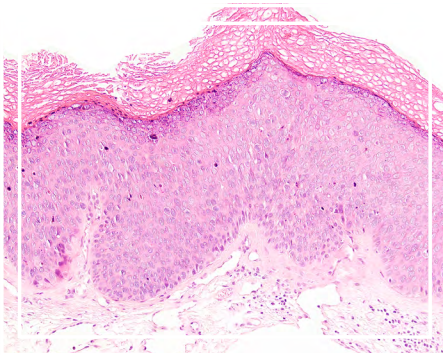


**FIGURE 4a.** Basaloid HPV-I VIN with mild flat acanthosis, minimal maturation between basal layer and surface, and nuclear atypia; H&E x200.

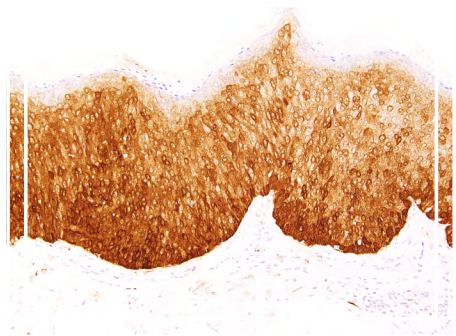


**FIGURE 4b.** Basaloid HPV-I VIN with full-thickness p53 overexpression highlighting enlarged and pleomorphic nuclei; x200.

When HSIL occurs in LS, it is more likely to be keratinizing than basaloid (Fig 5). It may be acanthotic, atrophic, eroded, but usually not acantholytic or subtle.<sup>16</sup> Hyalinized collagen may disappear underneath squamous neoplasia, likely relating to the altered immunologic interaction between stroma and epithelium.<sup>16</sup> This may contribute to histopathologic misdiagnosis of the dermatosis at underlying and adjacent skin and misattribution of cancers to LP or LSC when the actual underlying condition is LS.<sup>25</sup>



**FIGURE 5a.** Keratinizing HSIL in LS: hyperkeratosis and parakeratosis, acanthosis with reduced rete ridges, maturation between basal layer and surface, atypical nuclei, sclerosis, and lymphocytic infiltrate; H&E x100.



**FIGURE 5b.** Keratinizing HSIL in LS with block-positive p16, x100.

When attempting to distinguish between precursor lesions and cancer, pathologists first assess on low power for presence of separated nests in the dermis and tentacles jutting out from the basal layer.<sup>66</sup> If seen, pathologists evaluate at higher power for supporting features like bizarre vesicular nuclei and stromal reaction containing edema and inflammatory cells.

## Immunohistochemistry for p16 and p53

Immunohistochemistry for p16 and p53 is an essential tool in distinguishing neoplasia from its mimics and determining if a lesion is HPV-associated or HPV-I (see Table 1). Genomic integration of oncogenic HPV is associated with block-positive p16 in >95% of lower genital tract cases, making p16 a reliable marker for HSIL.<sup>67</sup> Block-positive is defined as strong nuclear and/or cytoplasmic staining with expression across at least the lower third of the epithelium.<sup>68</sup> Some cases of LSIL show block-positive p16, so assessment of nuclear features and cellular maturation remains important to differentiate it from HSIL. A small fraction of HPV-associated lesions may show non-block positive p16 due to CDKN4A deletion.<sup>69</sup> Block-positive p16 in combination with basal layer atypia yields a diagnosis of HPV-associated neoplasia. In contrast, HPV-I lesions show negative, mosaic, or non-block-positive p16 staining.<sup>17,70</sup>

A supportive p53 stain is of great value in the diagnosis of HPV-I VIN. The initial layer of p53 categorization is aberrant versus wild-type.<sup>10,12,71</sup> Aberrant encompasses null, cytoplasmic, or overexpressed either at the basal layer or across basal and suprabasilar cells. Overexpression is defined as strong staining in >80% of basal nuclei and occurs in at least 40% of HPV-I VIN.<sup>1,71</sup> Aberrant patterns strongly correlate with the presence of TP53 mutations and are also called 'p53-mutant.' Wild-type refers to the pattern seen in normal epithelium: scanty, scattered, light to moderate staining of nuclei at basal and suprabasilar levels. The p53 pattern in HSIL is categorized as wild-type but has a distinctive appearance of basal sparing with moderate to strong staining of mid-epithelial nuclei.<sup>16,71-73</sup>

Null and cytoplasmic p53 patterns only occur in HPV-I VIN, so when present clinch the diagnosis. By contrast, pathologic interpretation of basal overexpression poses challenges and its significance depends on appearance and context. When p53 nuclear staining is strong and continuous, it highlights the difference between normal and enlarged pleomorphic nuclei and facilitates a HPV-I VIN diagnosis.<sup>54,55,74</sup> However, 10-20% of HPV I VIN specimens show p53 patterns with more staining than seen in wild-type but insufficient for the >80% definition of overexpressed.<sup>13</sup> This appearance is also seen in specimens assessed as unusual acanthotic lesions (see next section).<sup>13,54</sup> At present, lesions showing an 'almost overexpressed' p53 pattern defy easy categorization into aberrant versus wild-type, have unclear clinical and mutational status, and complicate research in the field. The wild-type pattern occurs in HPV-I VIN, unusual acanthotic lesions, and LS.<sup>54,69,75</sup> Additional difficulties around p53 interpretation include variation across an individual specimen and relate to the duration and extent of tissue fixation.<sup>69,71</sup>

**TABLE 1 Summary of p53 patterns described in HPV-independent neoplasia<sup>12,13,71</sup>**

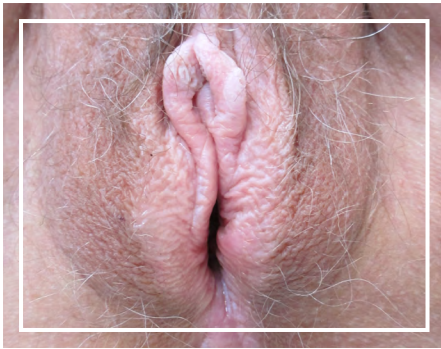	Description of staining	Location of staining	Rate in HPV-I VIN	Rate in unusual acanthotic lesions	Rate in LS
<b>Wild-type-scattered</b>	Heterogenous nuclear staining of variable intensity	Basal Parabasal	26-35%	44-59%	75%
<b>Wild-type-mid-epithelial*</b>	Moderate-strong nuclear staining	Mid-epithelial Spares basal layer	0.4%	0	0
<b>Diffuse overexpression</b>	Strong nuclear staining	Basal and parabasal layers, sometimes extends to upper epithelium	41%	18%	0
<b>Basal overexpression<sup>^</sup></b>	Strong nuclear staining of consecutive cells	Basal	22%	23-56%	17%
<b>Null</b>	Complete absence of nuclear staining	N/A	7-24%	0	0
<b>Cytoplasmic</b>	Diffuse cytoplasmic staining +/- nuclear staining	Basal and upper layers	0-1%	0	0

\* Nearly always seen in HPV-related disease

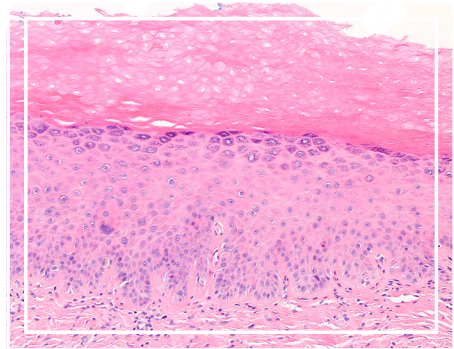
<sup>^</sup> Designation may not have always required >80% of basal cells strongly stained

## Unusual acanthotic lesions in LS

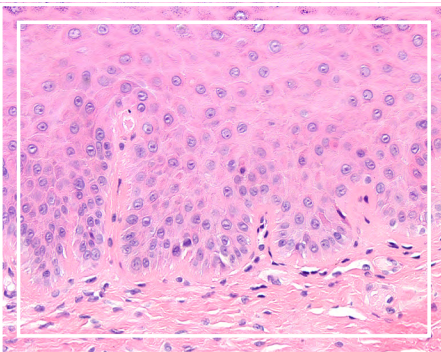
The pathway from LS to vulvar SCC is a biological continuum, thus pinpointing the transition from inflammatory to neoplastic is difficult.<sup>14,76</sup> Efforts to shoehorn a continuous entity into a dichotomous framework of benign versus malignant have contributed to an overlapping array of terminologies and clinical interpretations. Table 2 summarizes the multiple names applied to lesions with acanthosis and altered maturation that are too concerning to be labeled LS but do not show basal atypia (Fig 6). While these lesions have a larger mean epithelial thickness than HPV-I VIN, the rete ridges are less irregular (Fig 7).<sup>18</sup> Nuclei may be slightly enlarged and vesicular, but do not show hyperchromasia, significant pleomorphism, abnormal mitoses, or suprabasilar abnormality. Dermal infiltrate is variable, from sparse to dense and scattered to band-like, and sclerosis or fibrosis may be present or absent.



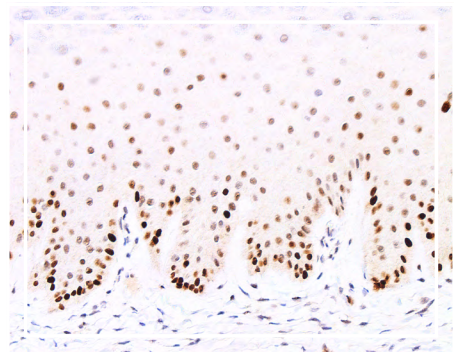
**FIGURE 6.** Unusual acanthotic lesion in LS: thick white plaques with an irregular surface at the clitoral hood and superior labia minora.



**FIGURE 7a.** Unusual acanthotic lesion in LS: thick hyperkeratosis, irregular acanthosis, altered maturation, and dermal fibrosis; H&E x100.



**FIGURE 7b.** Unusual acanthotic lesion in LS: slightly enlarged vesicular nuclei of similar size and occasional mitotic figures; H&E x200.



**FIGURE 7c.** Unusual acanthotic lesion in LS: p53 staining more than expected for wild-type but insufficient to qualify as overexpression; x200.

**TABLE 1** Historical overview of proposed terms for unusual acanthotic lesions

Acronym	Term	Author, year	Descriptors	p53	Comments
SCH	Squamous cell hyperplasia	ISSVD, 1989	<ul style="list-style-type: none"> <li>• Acanthosis</li> <li>• Abnormal maturation</li> <li>• Non-atypical basal nuclei</li> </ul>	Predates routine IHC	<ul style="list-style-type: none"> <li>• Hyperplasia of unknown cause</li> <li>• Confused with LSC</li> <li>• No specific criteria</li> </ul>
VAAD	Vulvar acanthosis and altered differentiation	Nascimento, 2004	<ul style="list-style-type: none"> <li>• Multilayered parakeratosis</li> <li>• Agranulocytosis with superficial epidermal pallor</li> <li>• Marked acanthosis with verruciform architecture</li> </ul>	Wild-type	<ul style="list-style-type: none"> <li>• In vicinity of verrucous SCC</li> <li>• Narrow definition applicable only to a subset of unusual acanthotic lesions</li> <li>• Listed in 2020 WHO classification</li> </ul>



DEVIL	Differentiated exophytic verruciform intraepithelial lesion	Watkins, 2017	<ul style="list-style-type: none"> <li>• Verruciform morphology</li> <li>• Abnormal differentiation</li> </ul>	Wild-type or Basal over-expressed	<ul style="list-style-type: none"> <li>• Acronym unsuitable for patient interactions</li> <li>• Listed in 2020 WHO classification</li> <li>• Absence of p53 mutations</li> <li>• High frequency PIK3CA mutations</li> </ul>
vLSC	Verruciform lichen simplex chronicus	Watkins, 2017 Roy, 2021	<ul style="list-style-type: none"> <li>• Hyperkeratosis</li> <li>• Hypergranulosis</li> <li>• Papillomatosis</li> <li>• Absence of pallor or premature maturation</li> </ul>	Wild-type	<ul style="list-style-type: none"> <li>• Reported as concurrent with 50-60% of lesions called VAAD or DEVIL</li> </ul>
AVL/AVH	Atypical verruciform lesion/hyperplasia	Watkins, 2017	<ul style="list-style-type: none"> <li>• Exophytic, prominent acanthosis or verruciform architecture</li> <li>• No features of HPV</li> <li>• Cases of verruciform carcinoma equivocal for invasion</li> </ul>	Wild-type or Basal over-expressed	<ul style="list-style-type: none"> <li>• Mutation analysis of these led to proposal of DEVIL</li> <li>• 'Atypical' subject to misinterpretation by clinicians</li> </ul>
HPVi(p-53wt) vaVIN or vaVIN if IHC not available	HPV-negative, p53 wild-type, verruciform acanthotic vulvar intraepithelial neoplasia	Parra-Herran, 2022 Cook, 2024	<ul style="list-style-type: none"> <li>• Acanthotic or verruciform architecture</li> <li>• Altered squamous differentiation seen as hyper- or parakeratosis</li> </ul>	Wild-type	<ul style="list-style-type: none"> <li>• Described as neoplastic requiring excision; SCC progression 40% in 3-4 years</li> <li>• Other p53 patterns suggested to represent HPV-I VIN</li> <li>• Mutations in NOTCH1, HRAS, PIK3CA, and others</li> </ul>
VAM	Vulvar aberrant maturation	Day, 2020 Heller, 2020 for ISSVD Difficult Pathologic Diagnoses committee	<ul style="list-style-type: none"> <li>• Thick parakeratosis or hyperkeratosis and/or premature maturation</li> <li>• Epithelial thickness 0.35-2.5mm</li> <li>• Variable rete ridge shape: flat to elongated/ anastomosed</li> <li>• Matures just above basal layer</li> </ul>	Wild-type or Basal over-expressed	<ul style="list-style-type: none"> <li>• Clinically-oriented umbrella term for range of similar lesions of unclear neoplastic status</li> <li>• Not based on molecular distinctions</li> <li>• Scope for initial medical treatment</li> </ul>

The obsolete ISSVD term squamous cell hyperplasia was intended to identify this group of lesions, but the lack of specific criteria invited overly broad use. A cohort study of 36 cases could not identify significant histopathologic differences between entities labeled VAAD, DEVIL and vLSC, suggesting that the terms could be combined.<sup>77</sup> In 2020, the WHO International Classification of Diseases for Oncology, third edition, second revision, placed VAAD

and DEVIL under the category of HPV-I VIN but classified their behavior as unspecified, borderline, or uncertain.<sup>78</sup> A subsequent publication proposed to abolish VAAD and DEVIL and replace them with a new term, HPV-independent p53 wild-type verruciform acanthotic VIN (HPVi(p53wt)vaVIN) or vaVIN if IHC not available.<sup>69</sup> These authors did not mention verruciform LSC, suggesting a view that this label was unnecessary. The authors labeled HPVi(p53wt)vaVIN a neoplastic entity and recommended universal excision by gynecologic oncology, a care pathway that may not be optimal or feasible in some healthcare settings.<sup>76</sup> They based this clinical advice on the presence of oncogenic mutations on molecular analysis and a reported 40% progression rate to SCC.

The group proposing HPVi(p53wt)vaVIN also suggested elimination of the term VAM with the criticism that it relied on histopathologic appearance rather than molecular assessment. However, the narrow definition of HPVi(p53wt)vaVIN encompasses only a subset of unusual acanthotic lesions.<sup>1,79</sup> VAM remains a useful label for lesions more concerning than LS but do not meet histologic and/or IHC criteria for HPV-I VIN or HPVi(p53wt)vaVIN.<sup>76</sup> VAM does not require ‘verruciform’ morphology, encompasses intermediate p53 patterns between wild-type and overexpressed, is easily understandable by clinicians, and invites clinicopathological correlation to determine the next step in management. Regardless of the nomenclature used, the differential diagnosis for unusual acanthotic lesions includes LSC and nodular prurigo, hypertrophic LS, hypertrophic LP, and verrucous carcinoma.<sup>54,79</sup> The array of terminology should become irrelevant once medicine advances to molecular assessment of all tumors and precursors, with individualized prognostic reports available for shared-decision making.

## Treatment and surveillance of neoplasia in lichen sclerosis

### Treatment of unusual acanthotic lesions and HPV-I VIN

Reasons that support immediate excision of lesions suspected to be vaVIN or VAM include bulky or concerning clinical appearance, patient suitability for anesthetic and surgical stress, and location amenable to excision. An initial attempt at medical management may be preferred for smaller, focal, less worrisome lesions, increased surgical risk due to poor health status, and/or challenging periclitoral, periurethral, and perianal locations. Medical management may include increased potency or frequency of topical steroids, intradermal steroid injection, and management of superinfection, followed by short-interval review and excision if the lesion persists.<sup>18</sup>

The European and ISSVD consensus statement on vulvar preinvasive disease establishes that the only treatment option for HPV-I VIN is surgical excision, while HSIL has options of topical medication, laser ablation, and excision.<sup>80</sup> The main reason for this is up to 42% of biopsy-proven HPV-I VIN excisions demonstrate cancer.<sup>19,80,81</sup> The aim of surgery is negative margins as residual disease is associated with increased risk of persistence and recurrence.<sup>28,62,82</sup> When lesions are adjacent to clitoris, urethra, and anus, obtaining clear margins involves risks of urinary, bowel, and sexual dysfunction that must be weighed against the desire to forestall recurrence or progression.<sup>3</sup>

The diagnosis and management of positive margins for HPV-I VIN remains controversial. Pathologic assessment of resection margins is challenging, often hindered by tissue fragmentation or distortion. The presence of a contrasting p53 pattern in adjacent non-neoplas-

tic skin facilitates margin delineation, as when null or overexpressed abuts wild-type.<sup>74,83</sup> When clinicopathologic assessment suggests incomplete excision, immediate re-excision is appropriate.<sup>80</sup> In cases with uncertain histopathology, wild-type IHC, and/or no visible post-operative skin abnormality, clinicians may undertake short-term reassessment, with the option to biopsy or re-excite if examination suggests residual neoplasia. Multidisciplinary collaboration and shared decision-making are essential given the potential for multiple morbid procedures in often elderly and unwell women.

The histopathologic appearance of recurrent HPV-I VIN has not been well described but anecdotally, subsequent lesions may be difficult to identify due to a subtle appearance. The epidermis may appear near-normal on low power, but the basal layer atypia seen on high power is confirmed by an aberrant p53 pattern.<sup>54</sup> Subtle HPV-I VIN does not show suprabasilar squamous cell changes of cytoplasmic eosinophilia, prominent eosinophilic nucleoli, and spongiosis (Fig 8). The hypothesis to explain this subtle variant is that horizontal proliferation of abnormal basal cells is so rapid there is insufficient time for atypical cells to grow upwards in the epithelium.

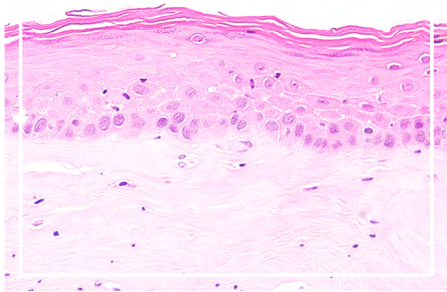


FIGURE 8a. Subtle HPV-I VIN: thinned epithelium, normal maturation, minimal basal atypia, and sclerosis; H&E x200.

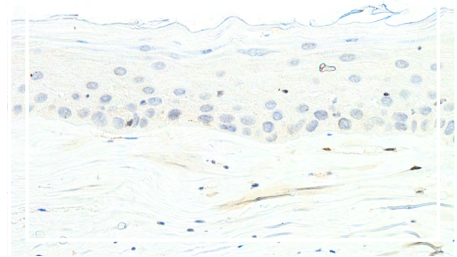


FIGURE 8b. Subtle HPV-I VIN: aberrant negative p53; x200.

## Treatment of HSIL

Vulvar HSIL treatment in women with coexisting LS presents unique challenges. The discomfort often associated with imiquimod application may be worse in LS-affected skin, reducing patient persistence with the regimen. Medication-induced dermatitis complicates assessment of LS control. The possibility of de-novo lichenoid reactions after topical imiquimod exposure has been documented, but not in LS patients.<sup>84,85</sup> Two cohorts assessing imiquimod for HPV-associated vulvar disease report outcomes for 10 patients with LS or LP, with 3 ceasing therapy due to discomfort, 5 showing complete response, and 2 having partial response.<sup>86,87</sup> Among 37 women with HSIL comorbid with LS and/or LP, 22 (60%) were treated with excision(s) alone, 5 (13%) had laser alone, and 10 (27%) had multimodal therapy of whom 3 had imiquimod.<sup>16</sup> Decisions regarding laser ablation versus excision must consider reduced tissue elasticity and redundancy, pre-existing architectural change, and functional impairments relating to LS. Based on the limited available evidence, HSIL treatment in LS may be individualized based on lesion characteristics, patient preference, and provider experience.

## Treatment of vulvar SCC

Vulvar SCC is surgically staged. When depth of invasion is 1mm or less, treatment is wide local excision. Unifocal tumors of <4cm width and depth >1mm require partial vulvectomy and sentinel node biopsy (SNB) with full groin dissection if positive. Larger excisions usually necessitate flap repair. Tumors over 4cm and multifocal cancer require bilateral inguinofemoral lymphadenectomy. Bulky tumors and local metastases often need multimodal therapy with surgery, radiation, and sometimes chemotherapy.<sup>58</sup> While the aim is tumor-free margins of at least 5mm, a margin less than that may strike a balance between anatomic preservation and surgical clearance.<sup>58</sup> Some centers report successful collaboration between dermatology and gynecologic oncology to undertake Mohs micrographic surgery for recurrence or positive margins of vulvar SCC; this has not yet been incorporated into a vulvar cancer guideline.<sup>88-90</sup>

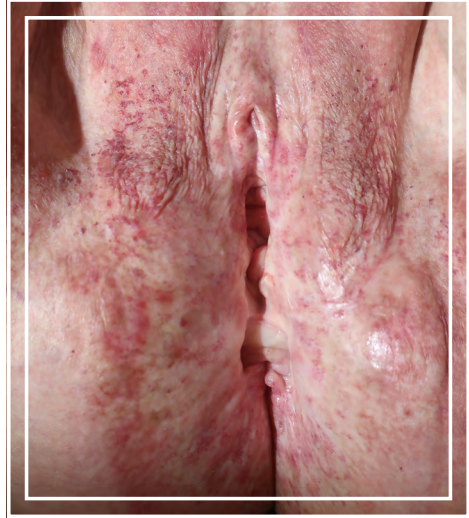Postoperative management of partial vulvectomy with flap repairs requires multidisciplinary input and nursing expertise in wound care. Wound breakdown is common, sometimes leading to prolonged hospitalization and recovery. Various dressing and antibiotic regimes have been reported, but none have been shown to significantly improve outcomes and local protocols vary.<sup>91</sup> The often dramatic postoperative anatomic alteration has associated functional and psychosexual sequelae.<sup>80</sup> Although SNB has reduced the frequency of lymphadenectomy and attendant complications, vulvar and lower extremity lymphedema may still occur and are exacerbated by radiation.<sup>92-94</sup> Many patients benefit from a structured and holistic rehabilitation program provided either within the gynecologic cancer department or through established referral networks.<sup>58,95</sup> This may include a psychologist, physiotherapist, cancer nurse specialist, sexologist, and lymphedema therapist. Topical estrogen and systemic hormone replacement may aid in the sexual health of cancer survivors.<sup>96</sup>

The optimal timing of topical steroid initiation after vulvectomy is unclear and unaddressed in surgical audits and cancer guidelines.<sup>97</sup> Some surgeons recommend deferring for 6 weeks postoperatively due to concerns about wound healing, an assumption that may be misplaced. Major surgery likely exacerbates LS-related inflammation, potentially antagonizing the skin repair process. The practice of delayed or non-initiation of LS treatment contrasts with expert recommendations to re-introduce topical steroids immediately after surgery addressing LS-related architectural change (see Chapter 12).

The role of adjuvant therapy with radiation is to reduce the risk of true recurrence, meaning clonally-matched disease. It is thus recommended after excision with positive margins when re-excision is not possible, and considered for close margins, lymphovascular or perineural invasion, and large or deeply invasive tumors.<sup>58</sup> Over the lifespan, local recurrence occurs in 40-50% of postoperative patients, with the risk calculated by one group as 4% per year.<sup>7,58</sup> While some of these represent true recurrence, many are second primaries in the field of LS.<sup>10,58</sup> The usual treatment of local recurrence is tumor excision with lymphadenectomy if not already done, with curative intent. Exenteration is a possibility in selected cases. Radiation is an option if not previously done and further surgery is impossible. When recurrent disease is incurable, early involvement of specialized palliative care services improves quality of life and clarifies goals for treatment and end-of-life plans.<sup>58</sup>

## Diagnosis and management of LS after vulvar radiation

Radiation therapy causes changes to skin color, texture, and surface integrity, making recognition of changes within residual LS difficult (Fig 9). Chronic radiation dermatitis produces hypo- and hyper-pigmentation, epithelial atrophy, inflammatory infiltrate, and dermal fibrosis, features that overlap with the clinicopathologic diagnosis of LS.<sup>98</sup> Telangiectasia resulting from radiation damage may complicate assessment of steroid overuse. Damage to skin appendages may result in alopecia, dryness, and pathologic difficulty in identifying the specimen site as non-keratinized epithelium, hairless skin, or hair bearing skin. Acquired localized lymphangioma may occur after radiation therapy and produce unusual skin findings on examination and histopathology.<sup>99</sup> Sarcomatoid features in HPV-I vulvar SCC may be more likely after radiation.<sup>100</sup>



**FIGURE 9.** Radiation changes in LS with induration and telangiectasia.

## Surveillance after treatment for SCC and its precursors

The cumulative SCC incidence for 27 years after treatment of HSIL or HPV-I VIN is 15.7%, with nearly half this risk occurring in the first 5 years post-diagnosis and the remainder distributed linearly over the next two decades.<sup>14</sup> In a setting of expert surveillance of HPV-I VIN every 3-4 months for 3 years then 6 monthly thereafter, 43% developed SCC with median time to diagnosis of 25 months.<sup>19</sup> In this same cohort, 31% of patients with HPV-I SCC recurred over a median time of 53 months with a steady risk over the time interval. Regular surveillance detects recurrences at a smaller size than ad hoc review.<sup>101</sup>

Vulvar cancer guidelines offer general recommendations for follow-up intervals in early-stage disease of every 3-6 months for 2 years then 6-12-monthly for up to 5 years, with the possibility of discharge to primary care afterwards.<sup>58,61,95</sup> These documents note a lack of evidence around clinical benefit or cost-effectiveness of longer-term follow-up. The primary surveillance mechanism described is clinical examination of the vulva and groins. For HPV-associated disease, the British Gynaecologic Cancer Society (BGCS) guidelines recommend 'formal vulvoscopy' and timely cervical screening, while the Canadian guideline advises annual cytology and the European guideline suggests HPV testing and/or cytology at 6-12 months if not done at presentation. There is little specific guidance for surveillance type and interval for patients with underlying dermatosis, multifocal, and/or recurrent disease, but a comment that regular follow-up may be appropriate or required.<sup>58,61,95</sup> The vague and

variable nature of these recommendations means providers and their institutions elaborate their own management protocols.

Effective lifelong management with topical steroid maintenance after LS-associated SCC reduces the risk of recurrent neoplasia from 44-47% to 27%.<sup>19,20,52,102</sup> Most international vulvar cancer guidelines do not include recommendations for long-term topical steroid use for vulvar SCC arising in LS. The BGCS 2020 guideline and 2023 Update advise that good control with maintenance therapy is recommended to “improve symptoms, reduce scarring, and reduce progression to SCC.”<sup>95</sup> The lack of attention to LS management in most vulvar cancer guidelines helps explain why some gynecologic oncologists do not routinely recommend topical steroids after cancer surgery, especially in asymptomatic patients.<sup>25,103</sup> Involvement of a vulvar care provider in parallel to oncological follow-up visits may enhance LS control and facilitate continuity in long-term specialist-led care.<sup>48,104</sup>

HPV-associated disease may recur at the same site or anywhere across the lower genital tract, to include cervix, vagina, genitocrural folds, and anus.<sup>105</sup> Several consensus statements advise regular review of all these sites, ideally involving colposcopic assessment of vulva, vagina, and cervix if present, and digital anorectal examination.<sup>80,106–108</sup> When HSIL or HPV-associated SCC occur in a woman with LS, communication between teams helps to establish a surveillance program than combines 3 to 6-monthly skin inspection with 6 to 12-monthly examination of the lower genital tract and a plan for who treats biopsy-proven lesions.

## Limitations of the literature

Despite progress in the histopathologic diagnosis of neoplasia occurring in LS, multiple unanswered questions remain. The relationship between varied morphologic types of HPV-I VIN, different p53 patterns, and clinical trajectory is incompletely understood. There is scant biologic understanding of skin adjacent to vulvar SCC that shows normal epithelial morphology but aberrant p53 expression. The biology, nomenclature, diagnosis, neoplastic potential, and management of unusual acanthotic lesions in LS remains controversial. Some of this difficulty arises from recent increased stringency in the definition of p53 overexpression, which left a subset of lesions straddling the aberrant versus wild-type classifications. It remains unclear why wild-type p53 patterns resembling resting epithelium, as described in HPV-I(p53wt)vaVIN, do not show IHC changes despite having diverse oncogenic mutations. The limited number of expert centers in vulvar neoplasia and variable engagement of academic pathologists with clinicians may produce divergence rather than consensus on these difficult topics. Enhanced communication between expert pathologists, professional societies in vulvar disease and gynecologic oncology, and guideline authors may reduce the risk of producing conflicting documents that serve to confuse providers involved in direct patient care.

Translating the knowledge advancement in diagnosis and prognosis into clinical recommendations is a work-in-progress. The extent of resection and approach to groin nodes remains the same for HPV-associated, HPV-I p53-mutant, and HPV-I p53 wild-type SCC, as these categories do not yet predict which cases are suitable for a less aggressive approach. Issues around margin status, re-excision, and assessment of post-treatment specimens are

areas ripe for scientific exploration. There is scant evidence to inform recommendations on the optimal surveillance interval and mechanisms after treatment of neoplasia, regardless of etiologic type. Clinical trials that aim to assess efficacy of LS treatment strategies inevitably cannot undertake the decades of observation required to provide answers about SCC risk reduction. As a result, providers engaged in vulvar cancer prevention must critically appraise clinical trials that endorse an ‘as needed’ approach to topical steroids or long-term follow-up, in recognition that interventional studies cannot address the lifelong implications of inadequate LS management.

## Conclusions and recommendations

Women with LS may develop HPV-I or HPV-associated vulvar SCC and its precursors. Elimination of vulvar SCC is a worthwhile goal that may be achieved through universal school-age HPV vaccination, improved community and provider knowledge of vulvovaginal conditions, enhanced access to quality vulvovaginal care, prompt diagnosis and effective management of LS, and detection and treatment of precursor lesions.

- Biopsy is indicated for white or red patches, plaques, erosions/ulcers, or fissures that look different to the surrounding abnormal skin and/or do not respond to topical corticosteroids.
- Correct assignment of neoplastic etiology requires p16 and p53 IHC in all cases of suspected squamous neoplasia.
- Although pathologic assessment of HPV-I precursor lesions may be difficult, expert pathology review with clinical correlation is often useful in clarifying the diagnosis and determining an optimal treatment plan.
- Treatment for HPV-I VIN is excision with the aim of clear margins.
- Treatment options for HSIL concurrent with LS include imiquimod, laser ablation, and excision.
- Unusual acanthotic lesions like vaVIN and VAM likely exist on a spectrum of neoplastic potential, in some cases allowing for individualized decisions on immediate excision versus optimized medical management followed by excision for non-response.
- The altered anatomy and skin appearance after vulvar cancer treatment complicates LS surveillance and management, making involvement of an experienced vulvar practitioner in parallel to oncology visits helpful for LS control and long-term follow-up.

## References

1. Thuijs NB, Van Beurden M, Duin S, et al. High-grade vulvar intraepithelial neoplasia: comprehensive characterization and long-term vulvar carcinoma risk. *Histopathology*. 2024;84(2):301-314. doi:10.1111/his.15050
2. Eva LJ, Sadler L, Fong KL, Sahota S, Jones RW, Bigby SM. Trends in HPV-dependent and HPV-independent vulvar cancers: The changing face of vulvar squamous cell carcinoma. *Gynecol Oncol*. 2020;157(2):450-455. doi:10.1016/j.ygyno.2020.01.029
3. Voss FO, Van Beurden M, Veelders KJ, et al. Incidence and Risk Factors for Recurrence and Progression of HPV-Independent Vulvar Intraepithelial Neoplasia. *J Low Genit Tract Dis*. 2024;28(2):153-159. doi:10.1097/LGT.0000000000000794
4. Rasmussen CL, Thomsen LT, Baandrup L, et al. Changes in HPV prevalence in Danish women with vulvar cancer during 28 years – A nationwide study of >1300 cancer cases. *Gynecol Oncol*. 2022;166(3):589-595. doi:10.1016/j.ygyno.2022.06.014



5. Meltzer-Gunnes CJ, Lie AK, Jonassen CGM, et al. Time trends in human papillomavirus prevalence and genotype distribution in vulvar carcinoma in Norway. *Acta Obstet Gynecol Scand.* 2024;103(1):153-164. doi:10.1111/aogs.14702
6. Nooij LS, Ter Haar NT, Ruano D, et al. Genomic Characterization of Vulvar (Pre)cancers Identifies Distinct Molecular Subtypes with Prognostic Significance. *Clin Cancer Res.* 2017;23(22):6781-6789. doi:10.1158/1078-0432.CCR-17-1302
7. Te Grootenhuys NC, Pouwew AW, de Bock GH, et al. Margin status revisited in vulvar squamous cell carcinoma. *Gynecol Oncol.* 2019;154(2):266-275. doi:10.1016/j.ygyno.2019.05.010
8. McAlpine JN, Kim SY, Akbari A, et al. HPV-independent Differentiated Vulvar Intraepithelial Neoplasia (dVIN) is Associated With an Aggressive Clinical Course. *Int J Gynecol Pathol.* 2017;36(6):507-516. doi:10.1097/PGP.0000000000000375
9. McAlpine JN, Leung SCY, Cheng A, et al. Human papillomavirus (HPV)-independent vulvar squamous cell carcinoma has a worse prognosis than HPV-associated disease: a retrospective cohort study. *Histopathology.* 2017;71(2):238-246. doi:10.1111/his.13205
10. Kortekaas KE, Bastiaannet E, Van Doorn HC, et al. Vulvar cancer subclassification by HPV and p53 status results in three clinically distinct subtypes. *Gynecol Oncol.* 2020;159(3):649-656. doi:10.1016/j.ygyno.2020.09.024
11. Eva L, Sadler L, Thompson JM, et al. HPV-independent and HPV-associated vulvar squamous cell carcinoma: two different cancers. *Int J Gynecol Cancer.* 2022;32(9):1108-1114. doi:10.1136/ijgc-2022-003616
12. Kortekaas KE, Solleveld-Westerink N, Tessier-Cloutier B, et al. Performance of the pattern-based interpretation of p53 immunohistochemistry as a surrogate for TP53 mutations in vulvar squamous cell carcinoma. *Histopathology.* 2020;77(1):92-99. doi:10.1111/his.14109
13. Rakislova N, Alemany L, Clavero O, et al. p53 Immunohistochemical Patterns in HPV-Independent Squamous Cell Carcinomas of the Vulva and the Associated Skin Lesions: A Study of 779 Cases. *Int J Mol Sci.* 2020;21(21):8091. doi:10.3390/ijms21218091
14. Thuijs NB, Van Beurden M, Bruggink AH, Steenberg RDM, Berkhof J, Bleeker MCG. Vulvar intraepithelial neoplasia: Incidence and long-term risk of vulvar squamous cell carcinoma. *Int J Cancer.* 2021;148(1):90-98. doi:10.1002/ijc.33198
15. Griesinger LM, Walline H, Wang GY, et al. Expanding the Morphologic, Immunohistochemical, and HPV Genotypic Features of High-grade Squamous Intraepithelial Lesions of the Vulva With Morphology Mimicking Differentiated Vulvar Intraepithelial Neoplasia and/or Lichen Sclerosus. *Int J Gynecol Pathol.* 2021;40(3):205-213. doi:10.1097/PGP.0000000000000708
16. Lin A, Day T, Ius Y, Scurry J. Anogenital High-Grade Squamous Intraepithelial Lesion Comorbid With Vulvar Lichen Sclerosus and Lichen Planus. *J Low Genit Tract Dis.* 2020;24(3):311-316. doi:10.1097/LGT.0000000000000540
17. Yang H, Almadani N, Thompson EF, et al. Classification of Vulvar Squamous Cell Carcinoma and Precursor Lesions by p16 and p53 Immunohistochemistry: Considerations, Caveats, and an Algorithmic Approach. *Mod Pathol.* 2023;36(6):100145. doi:10.1016/j.modpat.2023.100145
18. Day T, Marzol A, Pagano R, Jaaback K, Scurry J. Clinicopathologic Diagnosis of Differentiated Vulvar Intraepithelial Neoplasia and Vulvar Aberrant Maturation. *J Low Genit Tract Dis.* 2020;24(4):392-398. doi:10.1097/LGT.0000000000000569
19. Gallio N, Preti M, Jones RW, et al. Differentiated vulvar intraepithelial neoplasia long-term follow up and prognostic factors: An analysis of a large historical cohort. *Acta Obstet Gynecol Scand.* 2024;103(6):1175-1182. doi:10.1111/aogs.14814
20. Vieira-Baptista P, Pérez-López FR, López-Baena MT, Stockdale CK, Preti M, Bornstein J. Risk of Development of Vulvar Cancer in Women With Lichen Sclerosus or Lichen Planus: A Systematic Review. *J Low Genit Tract Dis.* 2022;26(3):250-257. doi:10.1097/LGT.0000000000000673
21. Leis M, Singh A, Li C, Ahluwalia R, Fleming P, Lynde CW. Risk of Vulvar Squamous Cell Carcinoma in Lichen Sclerosus and Lichen Planus: A Systematic Review. *J Obstet Gynaecol Can JOGC J Obstet Gynecol Can JOGC.* 2022;44(2):182-192. doi:10.1016/j.jogc.2021.09.023
22. Day T, Selim MA, Allbritton JI, Scurry J, Committee (DPDC) for the IDPD. Nonsclerotic Lichen Sclerosus: Definition of a Concept and Pathologic Description. *J Low Genit Tract Dis.* 2023;27(4):358. doi:10.1097/LGT.0000000000000760
23. Weyers W. Hypertrophic lichen sclerosus sine sclerosis: clues to histopathologic diagnosis when presenting as psoriasisiform lichenoid dermatitis. *J Cutan Pathol.* 2015;42(2):118-129. doi:10.1111/cup.12457
24. Day T, Bowden N, Jaaback K, Otton G, Scurry J. Distinguishing Erosive Lichen Planus From Differentiated Vulvar Intraepithelial Neoplasia. *J Low Genit Tract Dis.* 2016;20(2):174-179. doi:10.1097/LGT.0000000000000179
25. Day T, Otton G, Jaaback K, Weigner J, Scurry J. Is Vulvovaginal Lichen Planus Associated With Squamous Cell Carcinoma? *J Low Genit Tract Dis.* 2018;22(2):159-165. doi:10.1097/LGT.0000000000000384
26. Racanelli E, Jfri A, Gefri A, et al. Cutaneous Squamous Cell Carcinoma in Patients with Hidradenitis Suppurativa. *Cancers.* 2021;13(5):1153. doi:10.3390/cancers13051153



27. Fabbrocini G, Ruocco E, De Vita V, Monfrecola G. Squamous cell carcinoma arising in long-standing hidradenitis suppurativa: An overlooked facet of the immunocompromised district. *Clin Dermatol.* 2017;35(2):225-227. doi:10.1016/j.clindermatol.2016.10.019
28. Jamieson A, Tse SS, Brar H, Sadownik LA, Proctor L. A Systematic Review of Risk Factors for Development, Recurrence, and Progression of Vulvar Intraepithelial Neoplasia. *J Low Genit Tract Dis.* 2022;26(2):140-146. doi:10.1097/LGT.0000000000000662
29. Sager R, Frei P, Steiner UC, Fink D, Betschart C. Genital Dysplasia and Immunosuppression: Why Organ-Specific Therapy Is Important. *Inflamm Intest Dis.* 2019;4(4):154-160. doi:10.1159/000502687
30. MacLean AB, Jones RW, Scurry J, Neill S. Vulvar Cancer and the Need for Awareness of Precursor Lesions. *J Low Genit Tract Dis.* 2009;13(2):115-117. doi:10.1097/LGT.0b013e31818b8c13
31. Preti M, Selk A, Stockdale C, et al. Knowledge of Vulvar Anatomy and Self-examination in a Sample of Italian Women. *J Low Genit Tract Dis.* 2021;25(2):166-171. doi:10.1097/LGT.0000000000000585
32. Bevilacqua F, Selk A, Stockdale C, et al. The International Society for the Study of Vulvovaginal Disease (ISSVD) Vulvar Awareness Day Campaign: Knowledge of Vulvovaginal Diseases Among Italian Obstetrics and Gynecology Residents. *J Low Genit Tract Dis.* 2024;28(1):91-94. doi:10.1097/LGT.0000000000000777
33. Venkatesan A, Farsani T, O'Sullivan P, Berger T. Identifying Competencies in Vulvar Disorder Management for Medical Students and Residents: A Survey of US Vulvar Disorder Experts. *J Low Genit Tract Dis.* 2012;16(4):398-402. doi:10.1097/LGT.0b013e318245152b
34. Jit M, Prem K, Benard E, Brisson M. From cervical cancer elimination to eradication of vaccine-type human papillomavirus: Feasibility, public health strategies and cost-effectiveness. *Prev Med.* 2021;144:106354. doi:10.1016/j.ypmed.2020.106354
35. Viganò M, Beretta M, Lepore M, et al. Vaccination Recommendations in Solid Organ Transplant Adult Candidates and Recipients. *Vaccines.* 2023;11(10):1611. doi:10.3390/vaccines11101611
36. Garland SM, Brotherton JML, Moscicki AB, et al. HPV vaccination of immunocompromised hosts. *Papillomavirus Res.* 2017;4:35-38. doi:10.1016/j.pvr.2017.06.002
37. Martínez-Gómez X, Curran A, Campins M, et al. Multidisciplinary, evidence-based consensus guidelines for human papillomavirus (HPV) vaccination in high-risk populations, Spain, 2016. *Eurosurveillance.* 2019;24(7). doi:10.2807/1560-7917.ES.2019.24.7.1700857
38. Di Donato V, Caruso G, Bogani G, et al. HPV Vaccination after Primary Treatment of HPV-Related Disease across Different Organ Sites: A Multidisciplinary Comprehensive Review and Meta-Analysis. *Vaccines.* 2022;10(2):239. doi:10.3390/vaccines10020239
39. Ghelardi A, Parazzini F, Martella F, et al. SPERANZA project: HPV vaccination after treatment for CIN2+. *Gynecol Oncol.* 2018;151(2):229-234. doi:10.1016/j.ygyno.2018.08.033
40. Ghelardi A, Marrai R, Bogani G, et al. Surgical Treatment of Vulvar HSIL: Adjuvant HPV Vaccine Reduces Recurrent Disease. *Vaccines.* 2021;9(2):83. doi:10.3390/vaccines9020083
41. Stankiewicz Karita HC, Hauge K, Magaret A, et al. Effect of Human Papillomavirus Vaccine to Interrupt Recurrence of Vulvar and Anal Neoplasia (VIVA): A Trial Protocol. *JAMA Netw Open.* 2019;2(4):e190819. doi:10.1001/jamanetworkopen.2019.0819
42. Reuschenbach M, Doorbar J, Del Pino M, et al. Prophylactic HPV vaccines in patients with HPV-associated diseases and cancer. *Vaccine.* 2023;41(42):6194-6205. doi:10.1016/j.vaccine.2023.08.047
43. Janke MJ, DeBlanc J, Kobernik EK, et al. Comorbid Vulvar Lichen Sclerosus and High-Grade Squamous Intraepithelial Lesions: A Management Conundrum. *J Low Genit Tract Dis.* 2022;26(4):319-322. doi:10.1097/LGT.0000000000000690
44. Renaud-Vilmer C, Cavalier-Balloy B, Porcher R, Dubertret L. Vulvar lichen sclerosus: effect of long-term topical application of a potent steroid on the course of the disease. *Arch Dermatol.* 2004;140(6):709-712. doi:10.1001/archderm.140.6.709
45. Lee A, Bradford J, Fischer G. Long-term Management of Adult Vulvar Lichen Sclerosus: A Prospective Cohort Study of 507 Women. *JAMA Dermatol.* 2015;151(10):1061. doi:10.1001/jamadermatol.2015.0643
46. Cooper SM, Madnani N, Margesson L. Reduced Risk of Squamous Cell Carcinoma With Adequate Treatment of Vulvar Lichen Sclerosus. *JAMA Dermatol.* 2015;151(10):1059-1060. doi:10.1001/jamadermatol.2015.0644
47. Arnold S, Fernando S, Rees S. Living with vulval lichen sclerosus: a qualitative interview study. *Br J Dermatol.* 2022;187(6):909-918. doi:10.1111/bjd.21777
48. Jones RW, Scurry J, Neill S, MacLean AB. Guidelines for the follow-up of women with vulvar lichen sclerosus in specialist clinics. *Am J Obstet Gynecol.* 2008;198(5):496.e1-496.e3. doi:10.1016/j.ajog.2007.05.031
49. Mauskar MM, Marathe K, Venkatesan A, Schlosser BJ, Edwards L. Vulvar diseases. *J Am Acad Dermatol.* 2020;82(6):1277-1284. doi:10.1016/j.jaad.2019.07.115

50. Steinkasserer L, Hachenberg J, Hillemanns P, Jentschke M. Characterization of patients with vulvar lichen sclerosis and association to vulvar carcinoma: a retrospective single center analysis. *Arch Gynecol Obstet.* 2023;307(6):1921-1928. doi:10.1007/s00404-022-06848-y
51. Bleeker MCG, Visser PJ, Overbeek LH, van Beurden M, Berkhof J. Lichen Sclerosus: Incidence and Risk of Vulvar Squamous Cell Carcinoma. *Cancer Epidemiol Biomark Prev Publ Am Assoc Cancer Res Cosponsored Am Soc Prev Oncol.* 2016;25(8):1224-1230. doi:10.1158/1055-9965.EPI-16-0019
52. Chin S, Scurry J, Bradford J, Lee G, Fischer G. Association of Topical Corticosteroids With Reduced Vulvar Squamous Cell Carcinoma Recurrence in Patients With Vulvar Lichen Sclerosus. *JAMA Dermatol.* 2020;156(7):813-814. doi:10.1001/jamadermatol.2020.1074
53. Yang B, Hart WR. Vulvar Intraepithelial Neoplasia of the Simplex (Differentiated) Type: A Clinicopathologic Study Including Analysis of HPV and p53 Expression. *Am J Surg Pathol.* 2000;24(3):429-441. doi:10.1097/00000478-200003000-00013
54. Heller DS, Day T, Allbritton JJ, et al. Diagnostic Criteria for Differentiated Vulvar Intraepithelial Neoplasia and Vulvar Aberrant Maturation. *J Low Genit Tract Dis.* 2021;25(1):57-70. doi:10.1097/LGT.0000000000000572
55. Day T, Wilkinson E, Rowan D, Scurry J. Clinicopathologic Diagnostic Criteria for Vulvar Lichen Planus. *J Low Genit Tract Dis.* 2020;24(3):317-329. doi:10.1097/LGT.0000000000000532
56. Van De Nieuwenhof HP, Meeuwis KAP, Nieboer TE, Vergeer MCM, Massuger LFAG, De Hullu JA. The effect of vulvar lichen sclerosis on quality of life and sexual functioning. *J Psychosom Obstet Gynecol.* 2010;31(4):279-284. doi:10.3109/0167482X.2010.507890
57. Dasgupta S, De Jonge E, Van Bockstal MR, et al. Histological interpretation of differentiated vulvar intraepithelial neoplasia (dVIN) remains challenging—observations from a bi-national ring-study. *Virchows Arch.* 2021;479(2):305-315. doi:10.1007/s00428-021-03070-0
58. Oonk MHM, Planchamp F, Baldwin P, et al. European Society of Gynaecological Oncology Guidelines for the Management of Patients with Vulvar Cancer - Update 2023. *Int J Gynecol Cancer.* 2023;33(7):1023-1043. doi:10.1136/ijgc-2023-004486
59. Leber K, Van Beurden M, Zijlman HJ, Dewit L, Richel O, Vrouwenraets SME. Screening for intra-anal squamous intra-epithelial lesions in women with a history of human papillomavirus-related vulvar or perianal disease: results of a screening protocol. *Colorectal Dis.* 2020;22(12):1991-1998. doi:10.1111/codi.15320
60. Albuquerque A, Godfrey MAL, Cappello C, et al. Multizonal anogenital neoplasia in women: a cohort analysis. *BMC Cancer.* 2021;21(1):232. doi:10.1186/s12885-021-07949-8
61. rancis JA, Eiriksson L, Dean E, Sebastianelli A, Bahoric B, Salvador S. No. 370-Management of Squamous Cell Cancer of the Vulva. *J Obstet Gynaecol Can.* 2019;41(1):89-101. doi:10.1016/j.jogc.2018.07.004
62. Bigby SM, Eva LJ, Fong KL, Jones RW. The Natural History of Vulvar Intraepithelial Neoplasia, Differentiated Type: Evidence for Progression and Diagnostic Challenges. *Int J Gynecol Pathol.* 2016;35(6):574-584. doi:10.1097/PGP.0000000000000280
63. Scurry J, Baskota SU. HPV-Associated Atypical Mitotic Figures in Squamous Intraepithelial Lesions of the Lower Female Genital Tract. *J Low Genit Tract Dis.* 2016;20(2):165-168. doi:10.1097/LGT.0000000000000172
64. Schechter SA, Chan MP, Muthusamy S, Skala SL, Wang GY. Interobserver Agreement Across Subspecialties for Diagnosis of Differentiated Vulvar Intraepithelial Neoplasia and Predictive Values of 20 Histologic Features. *Arch Pathol Lab Med.* 2023;147(12):1431-1437. doi:10.5858/arpa.2022-0088-OA
65. Carreras-Dieguez N, Saco A, Del Pino M, et al. Vulvar squamous cell carcinoma arising on human papillomavirus-independent precursors mimicking high-grade squamous intra-epithelial lesion: a distinct and highly recurrent subtype of vulvar cancer. *Histopathology.* 2023;82(5):731-744. doi:10.1111/his.14860
66. Lee ES, Allen D, Scurry J. Pseudoepitheliomatous Hyperplasia in Lichen Sclerosus of the Vulva: *Int J Gynecol Pathol.* 2003;22(1):57-62. doi:10.1097/00004347-200301000-00012
67. Shain AF, Wilbur DC, Stoler MH, Quade BJ, Kong CS. Test Characteristics of Specific p16 Clones in the Detection of High-grade Squamous Intraepithelial Lesions (HSIL). *Int J Gynecol Pathol.* 2018;37(1):82-87. doi:10.1097/PGP.0000000000000391
68. Darraugh TM, Colgan TJ, Cox JT, et al. The Lower Anogenital Squamous Terminology Standardization Project for HPV-Associated Lesions: Background and Consensus Recommendations from the College of American Pathologists and the American Society for Colposcopy and Cervical Pathology. *Arch Pathol Lab Med.* 2012;136(10):1266-1297. doi:10.5858/arpa.LGT200570
69. Parra-Herran C, Nucci MR, Singh N, et al. HPV-independent, p53-wild-type vulvar intraepithelial neoplasia: a review of nomenclature and the journey to characterize verruciform and acanthotic precursor lesions of the vulva. *Mod Pathol.* 2022;35(10):1317-1326. doi:10.1038/s41379-022-01079-7

70. Allo G, Yap ML, Cuartero J, et al. HPV-independent Vulvar Squamous Cell Carcinoma is Associated With Significantly Worse Prognosis Compared With HPV-associated Tumors. *Int J Gynecol Pathol.* 2020;39(4):391-399. doi:10.1097/PGP.0000000000000620
71. Tessier-Cloutier B, Kortekaas KE, Thompson E, et al. Major p53 immunohistochemical patterns in situ and invasive squamous cell carcinomas of the vulva and correlation with TP53 mutation status. *Mod Pathol.* 2020;33(8):1595-1605. doi:10.1038/s41379-020-0524-1
72. Thompson EF, Hoang L, Höhn AK, et al. Molecular subclassification of vulvar squamous cell carcinoma: reproducibility and prognostic significance of a novel surgical technique. *Int J Gynecol Cancer.* 2022;32(8):977-985. doi:10.1136/ijgc-2021-003251
73. Jeffreys M, Jeffus SK, Herfs M, Quick CM. Accentuated p53 staining in usual type vulvar dysplasia—A potential diagnostic pitfall. *Pathol - Res Pract.* 2018;214(1):76-79. doi:10.1016/j.prp.2017.11.009
74. Thompson EF, Wong RWC, Trevisan G, et al. p53-Abnormal “Fields of Dysplasia” in Human Papillomavirus–Independent Vulvar Squamous Cell Carcinoma Impacts Margins and Recurrence Risk. *Mod Pathol.* 2023;36(2):100010. doi:10.1016/j.modpat.2022.100010
75. Liegl B, Regauer S. p53 immunostaining in lichen sclerosus is related to ischaemic stress and is not a marker of differentiated vulvar intraepithelial neoplasia (d-VIN). *Histopathology.* 2006;48(3):268-274. doi:10.1111/j.1365-2559.2005.02321.x
76. Bohl T, Day T, Heller D, et al. Comment on HPV-independent, p53-wild-type vulvar intraepithelial neoplasia: a review of nomenclature and the journey to characterize acanthotic precursor lesions of the vulva. Parra-Herran C. et al *Mod Pathol* 2022 Apr 18 doi: 10.1038/s41379-022-01079-7. *Mod Pathol.* 2022;35(12):2031-2032. doi:10.1038/s41379-022-01168-7
77. Roy SF, Wong J, Le Page C, et al. DEVIL, VAAD and vLSC constitute a spectrum of HPV-independent, p53-independent intra-epithelial neoplasia of the vulva. *Histopathology.* 2021;79(6):975-988. doi:10.1111/his.14451
78. WHO Classification of Tumours Editorial Board. *Female genital tumours.* In: 5th ed. ; 2020. <https://tumourclassification.iarc.who.int/chapters/34>
79. Cook E, Van De Vijver K, Parra-Herran C. Diagnosis of verruciform acanthotic vulvar intra-epithelial neoplasia (vaVIN) using CK17, SOX2 and GATA3 immunohistochemistry. *Histopathology.* Published online February 14, 2024;his.15156. doi:10.1111/his.15156
80. Preti M, Joura E, Vieira-Baptista P, et al. The European Society of Gynaecological Oncology (ESGO), the International Society for the Study of Vulvovaginal Disease (ISSVD), the European College for the Study of Vulval Disease (ECSVD) and the European Federation for Colposcopy (EFC) consensus statements on pre-invasive vulvar lesions. *Int J Gynecol Cancer.* 2022;32(7):830-845. doi:10.1136/ijgc-2021-003262
81. Van De Nieuwenhof HP, Bulten J, Hollema H, et al. Differentiated vulvar intraepithelial neoplasia is often found in lesions, previously diagnosed as lichen sclerosus, which have progressed to vulvar squamous cell carcinoma. *Mod Pathol.* 2011;24(2):297-305. doi:10.1038/modpathol.2010.192
82. Regauer S. Residual anogenital lichen sclerosus after cancer surgery has a high risk for recurrence: a clinicopathological study of 75 women. *Gynecol Oncol.* 2011;123(2):289-294. doi:10.1016/j.ygyno.2011.07.010
83. Singh N, Leen SL, Han G, et al. Expanding the Morphologic Spectrum of Differentiated VIN (dVIN) Through Detailed Mapping of Cases With p53 Loss. *Am J Surg Pathol.* 2015;39(1):52-60. doi:10.1097/PAS.0000000000000291
84. Drummond A, Pichler J, Argenziano G, et al. Lichen planopilaris after imiquimod 5% cream for multiple BCC in basal cell naevus syndrome. *Australas J Dermatol.* 2015;56(4). doi:10.1111/ajd.12151
85. Zhao L, Li K, Long F. Development of lichen planus associated with topical imiquimod therapy. *Dermatol Ther.* 2020;33(3). doi:10.1111/dth.13367
86. Westermann C, Fischer A, Clad A. Treatment of vulvar intraepithelial neoplasia with topical 5% imiquimod cream. *Int J Gynaecol Obstet Off Organ Int Fed Gynaecol Obstet.* 2013;120(3):266-270. doi:10.1016/j.jjgo.2012.09.020
87. Regauer S, Eberz B, Reich O. Human Papillomavirus–Induced Squamous Intraepithelial Lesions in Vulvar Lichen Planus. *J Low Genit Tract Dis.* 2016;20(4):360-364. doi:10.1097/LGT.0000000000000248
88. Spiker AM, Hankinson AC, Petrick MG, Marks VJ. Single Institution Review of Mohs Surgery for Vulvar Neoplasms. *Dermatol Surg.* 2019;45(12):1698-1700. doi:10.1097/DSS.0000000000001766
89. Nugent ST, Raj LK, Latif NA, et al. A retrospective case series of Mohs micrographic surgery and interdisciplinary management of female genital skin cancers: Local recurrence rates and patient-reported outcomes. *J Am Acad Dermatol.* 2023;89(2):301-308. doi:10.1016/j.jaad.2023.02.050
90. Virgen CA, Sanchez II, Elsensohn AN, Kraus CN. Vulvar squamous cell carcinoma guidelines do not include tissue-sparing techniques as a treatment option. *Int J Womens Dermatol.* 2023;9(1):e078. doi:10.1097/JW9.0000000000000078

91. Altman AD, Robert M, Armbrust R, et al. Guidelines for vulvar and vaginal surgery: Enhanced Recovery After Surgery Society recommendations. *Am J Obstet Gynecol*. 2020;223(4):475-485. doi:10.1016/j.ajog.2020.07.039
92. Covens A, Vella ET, Kennedy EB, Reade CJ, Jimenez W, Le T. Sentinel lymph node biopsy in vulvar cancer: Systematic review, meta-analysis and guideline recommendations. *Gynecol Oncol*. 2015;137(2):351-361. doi:10.1016/j.ygyno.2015.02.014
93. Huang J, Yu N, Wang X, Long X. Incidence of lower limb lymphedema after vulvar cancer: A systematic review and meta-analysis. *Medicine (Baltimore)*. 2017;96(46):e8722. doi:10.1097/MD.00000000000008722
94. Robison K, Roque D, McCourt C, et al. Long-term follow-up of vulvar cancer patients evaluated with sentinel lymph node biopsy alone. *Gynecol Oncol*. 2014;133(3):416-420. doi:10.1016/j.ygyno.2014.03.010
95. Morrison J, Baldwin P, Buckley L, et al. British Gynaecological Cancer Society (BGCS) vulvar cancer guidelines: Recommendations for practice. *Eur J Obstet Gynecol Reprod Biol*. 2020;252:502-525. doi:10.1016/j.ejogrb.2020.05.054
96. Huffman LB, Hartenbach EM, Carter J, Rash JK, Kushner DM. Maintaining sexual health throughout gynecologic cancer survivorship: A comprehensive review and clinical guide. *Gynecol Oncol*. 2016;140(2):359-368. doi:10.1016/j.ygyno.2015.11.010
97. Martin AL, Stewart JR, Girithara-Gopalan H, Gaskins JT, McConnell NJ, Medlin EE. Trends and Complications of Vulvar Reconstruction After Vulvectomy: A Study of a Nationwide Cohort. *Int J Gynecol Cancer*. 2018;28(8):1606-1615. doi:10.1097/IGC.0000000000001332
98. Bray FN, Simmons BJ, Wolfson AH, Nouri K. Acute and Chronic Cutaneous Reactions to Ionizing Radiation Therapy. *Dermatol Ther*. 2016;6(2):185-206. doi:10.1007/s13555-016-0120-y
99. Papalas JA, Robboy SJ, Burchette JL, Foo W, Selim MA. Acquired vulvar lymphangioma circumscriptum: a comparison of 12 cases with Crohn's associated lesions or radiation therapy induced tumors. *J Cutan Pathol*. 2010;37(9):958-965. doi:10.1111/j.1600-0560.2010.01569.x
100. Wong J, Roy SF, Provencher D, Rahimi K. Vulvar Squamous Cell Carcinoma With Sarcomatoid Features are HPV-independent Lesions: A Subset are Also Associated With TP53-independent Lesions and Radiation Therapy. *Int J Gynecol Pathol*. 2023;42(2):207-211. doi:10.1097/PGP.0000000000000880
101. Oonk MHM, De Hullu JA, Hollema H, et al. The value of routine follow-up in patients treated for carcinoma of the vulva. *Cancer*. 2003;98(12):2624-2629. doi:10.1002/cncr.11837
102. Vue NC, Sassani J, Prairie B, et al. Clinical outcomes with utilization of high-potency topical steroids in patients with lichen sclerosus-associated vulvar cancer. *Gynecol Oncol*. 2024;187:58-63. doi:10.1016/j.ygyno.2024.05.003
103. Pounds R, Tahir S, Dawson C, Woodman C, Luesley D, Yap J. A survey on the use of topical steroids in patients treated for lichen sclerosus-associated vulvar squamous cell carcinoma. *J Obstet Gynaecol*. 2018;38(2):265-269. doi:10.1080/01443615.2017.1352572
104. van den Einden LC, van der Avoort IA, de Hullu JA. Prevention, identification and treatment of vulvar squamous (pre) malignancies: a review focusing on quality of care. *Expert Rev Anticancer Ther*. 2013;13(7):845-859. doi:10.1586/14737140.2013.811059
105. Clarke MA, Deshmukh AA, Suk R, et al. A systematic review and meta-analysis of cytology and HPV-related biomarkers for anal cancer screening among different risk groups. *Int J Cancer*. 2022;151(11):1889-1901. doi:10.1002/ijc.34199
106. Albuquerque A, Stockdale CK, Heller D, et al. Vulvar High-Grade Squamous Intraepithelial Lesions and Cancer as a Risk Factor for Anal Cancer: A Review. *J Low Genit Tract Dis*. 2022;26(1):32-37. doi:10.1097/LGT.0000000000000631
107. Buchanan TR, Zamorano AS, Massad LS, et al. Risk of cervical and vaginal dysplasia after surgery for vulvar intraepithelial neoplasia or cancer: A 6 year follow-up study. *Gynecol Oncol*. 2019;155(1):88-92. doi:10.1016/j.ygyno.2019.07.017
108. Committee Opinion No. 675 Summary: Management of Vulvar Intraepithelial Neoplasia. *Obstet Gynecol*. 2016;128(4):937-938. doi:10.1097/AOG.0000000000001704

# Surgery for complications of lichen sclerosis

*Jennifer Bradford, Matthé Burger, Linn Woelber, Anna Jaeger, Jill Krapf*

Lichen sclerosis (LS) may result in loss of vulvar architecture including resorption of the labia minora, clitoral phimosis, and introital stenosis. Resorption describes adherence of labia minora to the interlabial sulci, which can progress to a coalescence of the labia minora and majora. Labial fusion describes complete or partial midline adherence of labia minora, often with accompanying diminution of introital dimension. This may obstruct urinary outflow with potential for post-micturition dribbling and vulvovaginal contact dermatitis. Clitoral phimosis describes adhesions between the clitoral hood, clitoral frenulum, anterior labia minora, and interlabial sulci. This results in reduced size and mobility of periclitoral structures, producing a spectrum of anatomic change from flattening of anterior anatomy to a non-retractable clitoral hood. Adhesions may occur between the clitoral glans and hood. Clitoral phimosis may be asymptomatic or accompanied by pain, altered sensation, or decreased orgasmic function. Accumulation of keratin debris between the clitoral hood and glans may produce a smegmatic pseudocyst or keratin pearls, often with associated chronic inflammation.<sup>1,2</sup> Infection of a clitoral inclusion cyst may result in a periclitoral abscess with vulvar cellulitis that may require hospitalization, intravenous antibiotics, and surgical drainage. Some clinicians describe the combined effects of LS-related resorption and adhesion as ‘scarring,’ a term well understood by the public but with inherent negativity and non-specificity.

Prevention of architectural change through early LS diagnosis and adequate treatment is superior to surgical intervention (see Chapters 3,6).<sup>3,4</sup> Surgery to address anatomic changes from vulvar LS is an option for patients with directly attributable genitourinary symptoms.<sup>2,5-7</sup> Labial fusion may be surgically ameliorated to manage obstructive urinary symptoms.<sup>8,9</sup> Sexual dysfunction arising from clitoral phimosis may sometimes be mitigated with clitoral adhesiolysis.<sup>5,10,11</sup> Sexual pain due to introital stenosis or non-healing fissure may be improved with superficial scar band release techniques.<sup>8,11,12</sup> Perineoplasty is rarely useful and reserved for severe posterior introital stenosis unresponsive to other approaches.<sup>10,13</sup> Wide local excision and skinning vulvectomy are only appropriate for management of neoplasia as LS recurs at excision borders in more than 40% of cases (see Chapter 11).<sup>14,15</sup> This chapter presents perioperative considerations and procedural approaches for LS-associated loss of architecture causing genitourinary dysfunction.

## Psychosexual and musculoskeletal considerations and non-surgical management strategies

Late diagnosis and inadequate treatment of LS produce negative psychosocial impacts and impaired sexual function (see Chapter 8).<sup>16–19</sup> Diminished quality of life (QoL) arises both from symptoms and feelings of isolation, embarrassment, and stigma around open discussion of genital conditions.<sup>20</sup> Women with vulvar LS achieve poorer scores on the Female Genital Self-Image Scale (FGSIS) compared to matched controls, correlating with reduced sexual function.<sup>21</sup> Sexual health diagnoses often comorbid with LS include hypoactive sexual desire, arousal, and orgasm disorders.<sup>22,23</sup> Psychosexual counseling improves sexual function and QoL in women with LS; the European Dermatology Forum 2023 EuroGuiDerm guideline for LS suggests referral to a sexologist for LS patients experiencing sexual impacts.<sup>21,24,25</sup>

Patients who request genital surgery for LS-related architectural change express a variety of motivations and expectations, with the majority wishing to optimize participation in penile-vaginal intercourse.<sup>26</sup> Key themes relating to requests for surgery include: “desire to be a normal woman,” “desire to sexually satisfy the male partner,” and “desire to regain the experience of intimacy and sexual enjoyment.”<sup>26</sup> For many patients, LS-related architectural change is unlikely to be the sole barrier to a satisfying sexual life and surgery may not restore feelings of normalcy or sexual fulfillment.<sup>25</sup> Couple-based consultation with a sexologist may aid in clarifying relationship goals, identifying the role of non-coital intimacy, and establishing realistic expectations regarding outcomes of surgery.<sup>25,27</sup>

At least half of women with LS experience sexual pain.<sup>18,28,29</sup> Adequate treatment of LS with topical corticosteroids reduces inflammation, changes the dermo-epidermal interaction, and modifies collagen cross-linking. This often results in softening of sclerotic changes, improved tissue elasticity, and prevention of further anatomic alteration.<sup>8,30</sup> Comorbid pelvic floor muscle overactivity and dysfunction serves as both a cause and contributor to sexual pain. Vulvovaginal allodynia and musculoskeletal pain may arise from multiple sources to include painful chronic dermatoses, recurrent candidiasis, pelvic surgery, obstetric events, and abnormality or injury of the spine, pelvic girdle, or lower extremities.<sup>31</sup> Assessment of pelvic floor tightness and tenderness is fundamental to the evaluation of dyspareunia and sexual dysfunction.<sup>32,33</sup> Pain management strategies include maximizing treatment of contributing conditions, avoidance of provoking activities, neuromodulator medications, pelvic floor physiotherapy, and desensitization with vaginal dilators (see Chapter 8). Improvement in vestibular allodynia and pelvic floor dysfunction are prerequisites when the indication for vulvar surgery is sexual or vulvovaginal pain.

## Preoperative considerations

Surgery is not a reason for interruption of topical steroid use. It is essential to optimally control LS with topical corticosteroids in all patients, particularly those planning genital surgery.<sup>8</sup> Goals of treatment are near normal skin color and normal texture (see Chapter 6). Preoperative control of LS-related inflammation likely mitigates the Koebner phenomenon of new areas or flares of LS emerging at the site of cutaneous injury or trauma. Before and after

surgery, it may be helpful to re-review where to place steroids with a mirror, photographic image, or colposcopic camera screen. Patients and other healthcare providers require reassurance that daily topical steroids will not impede or delay wound healing but rather, adequate application prevents postoperative complications such as reforming of adhesions. Concomitant perioperative use of vaginal estrogen is advisable in patients with genitourinary syndrome of menopause (GSM) or other causes of estrogen deficiency.<sup>34</sup> Pre-procedure counseling must emphasize that a satisfactory surgical outcome relies on faithful adherence to the individualized topical steroid and retraction or dilation regimen; complications, persistent functional limitations, and recurrence of adhesions may occur despite these efforts.<sup>25</sup> As with any procedure, informed consent involves discussion of standard surgical risks: bleeding potentially requiring transfusion, infection, organ damage, anesthetic complications, unexpected findings, recurrence, need for additional concurrent or future procedures, poor cosmetic result, acute and chronic postoperative pain, and bowel, bladder, or sexual dysfunction.

## Surgical interventions

### Surgery for clitoral phimosis

Asymptomatic clitoral phimosis does not require intervention. Indications for surgery include clitoral pain, recurrent periclitoral abscess, and decreased arousal and orgasmic function attributable to periclitoral anatomic change. In mild cases, gentle patient-directed soft tissue mobilization may aid in adhesion release.<sup>35</sup> Multiple publications describe a variety of surgical techniques to address clitoral phimosis and stress the importance of effective pre- and postoperative topical corticosteroid application to improve tissue resilience and prevent re-adhesion. This includes patient instruction regarding postoperative manipulation of the clitoral hood to apply steroid ointment to the glans.

Goldstein and Burrows reported 8 cases of clitoral adhesiolysis. The technique involved blunt dissection between the hood and glans with a lacrimal probe, followed by dorsal incision of approximately 5 mm with Iris scissors, then lysis of remaining adhesions under direct visualization.<sup>11,12</sup> In some cases the clitoral hood edges were trimmed with a scalpel to reduce re-adhesion risk. Options for hemostasis included pressure, silver nitrate, electrocautery, or ferric subsulfate solution. Among 4 women who reported decreased clitoral sensitivity prior to surgery, all noted improved sensitivity and orgasm postoperatively.<sup>11</sup> Recurrent adhesion was reported in 32% with a median follow-up of 45 months.<sup>11</sup> Patients universally expressed satisfaction with the surgical outcome and that they would recommend the procedure to others.

Several authors endorse midline incision of the clitoral hood with lateral plication of the edges. Osterzenski described hydrodissection to separate agglutination prior to making a reverse V-shaped incision at the clitoral hood, secured laterally with suture.<sup>36</sup> Of 10 patients followed for 5 years, clitoral pain and orgasmic function were restored within 12 weeks. Alei and colleagues outlined a “hoodplasty” technique in which a dorsal incision with monopolar cautery or scalpel exposed the glans, with resulting flaps plicated laterally.<sup>37</sup>

In a series of 41 LS patients who underwent vulvar surgery, 18 had procedures for clitoral phimosis but the techniques used were not described.<sup>38</sup> Perioperative corticosteroid use



may have been inadequate; the authors required daily clobetasol propionate or mometasone furoate ointment for at least 2 weeks before and 4 weeks after the operation, before decreasing to twice weekly use. Of 18 patients who underwent clitoral adhesiolysis, 11% had recurrent phimosis. Patient-reported outcomes were not stratified by procedure type, but 90% reported satisfaction with their treatment.

Myers and colleagues described office-based lysis of clitoral adhesions in 41 patients, of whom 12% had LS.<sup>39</sup> The authors provided topical local anesthetic or a dorsal clitoral nerve block, used fine Jacobsen mosquito forceps to separate the plane between glans and hood, then removed smegma and keratin pearls. Postoperative management included topical steroids, estrogen, antifungal, and/or emollient, depending on the perceived etiology. Patients reported pain reduction in 76%, improved arousal and orgasm in 63 and 64% respectively, and satisfaction with the procedure in 83%; results from patients with LS were not separately analyzed.

### **Surgery for labial fusion, agglutination, and anterior introital stenosis**

Mild adhesions between labia minora and interlabial sulcus may be softened and further change arrested with topical corticosteroids. Complete labial resorption is irreversible. Midline fusion likewise may respond to topical steroids, but if adhesion persists and results in urinary or sexual symptoms then surgical separation is indicated. Labial separation may be performed with blunt or sharp dissection along the line of adherence. Several authors report use of serial Hegar dilators to achieve adhesiolysis.<sup>40–42</sup>

Adhesions and sclerosis may occur at the clitoral frenulum. In most cases, this may be addressed with a combination of sharp and blunt dissection along existing tissue planes, followed by the patient applying gentle lateral pressure daily until healed.<sup>43</sup> If this is unsuccessful despite adequate topical steroid use, surgeons may offer excision of the affected epithelium with a free full-thickness vaginal flap to enable primary closure.<sup>34</sup>

### **Surgery for posterior introital stenosis**

The array of surgical techniques described for posterior introital stenosis likely arises from regional and international variation in surgical practice patterns and relative roles of gynecology, dermatology, and urology. The clinical goal is to choose the least invasive procedure that sits within a practitioner's skill set and restores genitourinary and sexual function.

Epithelial fissuring at the fossa navicularis and posterior fourchette may accompany sclerotic changes of LS and be exacerbated by estrogen deficiency.<sup>2,43,44</sup> While many cases respond to medical optimization and vaginal dilator use, some patients experience pain or negative associations with previous sexual trauma and are unable to engage in regular dilation. In these cases, division of adhesions may be preferable. Office procedures are feasible with injection of long-acting local anesthetic, then sharp midline dissection in this relatively avascular plane.<sup>8</sup> Patients apply steroid ointment to divided skin edges at a frequency double the preoperative regimen and undergo close surveillance until complete healing. In a cohort of women with LS or LP who underwent simple perineotomy, re-adhesion occurred in 6/35 (17%) and was attributed to steroid non-adherence in 2. All but one of 18 sexually

active women reported reduced pain, with 8 reporting painless intercourse. Of 10 previously apareunic patients, 7 attempted intercourse postoperatively but only 1 had resolution of sexual pain. The perineotomy technique avoids skin excision, suturing, and anti-adhesion products, and usually does not require chemical hemostatic agents.

A more extensive surgical approach involves excision to the dermal layer of a horizontal ellipse at the vestibular-perineal border using sharp and blunt dissection, followed by blunt traction and hemostasis with ferric subsulfate solution.<sup>43</sup> Postoperatively, the patient applies daily topical steroid ointment and separates previously adherent tissues several times daily until completely healed. These authors undertook an outcomes study of mixed surgical procedures for LS-related adhesions; 4 of 13 (31%) women with preoperative dyspareunia reported pain-free intercourse, 7 (54%) reported reduced sexual pain, and 2 (16%) had no change. Approximately one third of patients reported recurrent adhesions.<sup>11</sup>

Multiple authors describe perineoplasty to alleviate posterior introital stenosis in patients with LS.<sup>13,38,45</sup> Excision involves affected vestibular and anterior perineal skin; the lateral border does not extend beyond the major vestibular gland duct. The surgeon releases subcutaneous scar tissue, undermines distal vaginal epithelium, and undertakes tension-free re-approximation of skin horizontally with sutures. In more extensive procedures, vaginal dissection extends 4-5 cm with accompanying lengthwise incisions made at the right and left posterior vagina to create a 3-4 cm advancement flap. Rarely, surgeons undertake a double opposing Z-plasty with VY advancement of the perineum when other techniques are unsuccessful.<sup>46</sup> These studies report low complications rates but persistent sexual dysfunction or pain in one third of patients.<sup>10,11,13,38,47</sup>

## Post-operative care and complications

### General measures

Patients usually experience minimal discomfort during the first 12 hours due to intraoperative use of long-acting local anesthetics. Immediate postprocedural care involves analgesics, rest, and sometimes cool pack application. On the first postoperative day, patients initiate showering or soaking the area with water several times daily, gentle drying, and caution with toileting practices. Several times daily, patients gently separate previously adhered surfaces at the clitoris, labia minora, or posterior fourchette. A soft cushion and loose-fitting clothing aid in comfort. There may be ooze and ecchymoses postoperatively. Patients should seek medical attention if bleeding does not respond to pressure or in case of hematoma, spreading erythema, or wound dehiscence.<sup>34</sup>

When introital stenosis is the indication for surgery, the need for and timing of dilator use depends on extent of the dissection, progress with healing, and an individual's efficacy in manual pressure during the early postoperative phase. Patients may initiate dilator use immediately if incision lines were left open. After procedures with suture line closure or flap repair, surgeons may advise delay of dilator use to 2- 4 weeks post-procedure. Penetrative sexual activity may resume at least 6 weeks after surgery if tolerating admission of a 35 mm dilator or robust digital application of pressure to the surgical site. When feasible and pleasurable, regular intercourse is an alternative to dilators for maintenance of introital dimensions.

## Complications and prevention strategies

Lichen sclerosus obeys the Koebner phenomenon with the potential for initiation or exacerbation of disease in response to any skin trauma or injury, including adhesiolysis, obstetric lacerations, perineoplasty, and posterior repair. A postoperative flare impairs wound healing and increases the risk of re-adhesion. Reported rates of LS flare and associated ramifications are as high as 50% but this may reflect issues of patient selection and postoperative care regimens.<sup>38,47</sup>

One approach to prevention of short-interval LS exacerbation involves doubling the steroid potency and/or frequency on the first postprocedural day, continuing that for 2 weeks, then gradually reducing to preoperative maintenance levels over 6 to 12 weeks.<sup>8</sup> In most cases, patients use their fingers to apply steroids and pressure or retraction as instructed by their surgeon. For deeper vaginal procedures, patients may use a vaginal dilator to deliver steroids to the surgical site. It is not necessary to use oral prednisone. Fortnightly review until healed allows for early identification of koebnerization and re-adhesion. Patient adherence to self-care recommendations is fundamental to a successful outcome; time off from work and assistance from a support person may reduce barriers to engaging with the postoperative regimen.

After any vulvovaginal surgery, pain may worsen, persist, or arise de-novo.<sup>27,48,49</sup> Scant literature addresses the incidence, associated factors, prevention, and management of sustained pain relating to vulvar procedures.<sup>50,51</sup> One study suggested 30% of 19 patients with LS and dyspareunia who had surgery for that indication had persistent pain.<sup>27</sup> Assessment of women presenting with persistent pain after vulvovaginal procedures involves ensuring adequate LS control, excluding infectious or inflammatory vulvovaginitis, neurologic examination over pudendal, ilioinguinal, genitofemoral, and obturator distributions, and gentle internal palpation of pelvic floor and hip rotator musculature. When pain is localized to the previous surgical field, injection of that area with local anesthetic may serve diagnostic and therapeutic purposes.<sup>52-54</sup> Management of persistent postoperative pain often requires a multidisciplinary approach incorporating a combination of neuromodulation, anesthetic injections, physiotherapy, behavioral modifications, and psychologic and/or sex therapy.

## Limitations of the literature

Interpretation of studies is limited by small sample sizes, data from single surgeons or centers, lack of control groups, short follow-up or loss to follow-up, and non-validated outcome tools. Use of variable and possibly inadequate topical steroid regimens may contribute to re-adhesion and persistent sexual dysfunction. Studies have not sufficiently addressed the role of pre- and postoperative topical estrogen in women with LS and GSM. The incidence, management, and prevention of chronic postoperative pain after vulvar surgery remains unexplored.

## Conclusions and recommendations

Vulvar LS can lead to significant architectural change affecting genitourinary and sexual health. Surgery is reserved for patients with functional impairment non-responsive to robust medical management and directly attributable to clitoral phimosis or introital stenosis. Preoperative control of LS-related inflammation with adequate topical corticosteroids

is essential both pre- and post-surgery. Patients unable to adhere to topical steroids are poor candidates for surgery. Improvement rates vary postoperatively and pain may not be improved and might worsen. Clear counseling of risks, benefits, and limitations of surgery is important. There are varied techniques for management of labial fusion, clitoral phimosis, and introital stenosis. Pre- and postoperative strategies to optimize tissue health, address comorbid pain and psychosexual disorders, prevent koebnerization, and minimize re-adhesion likely enhance patients' sexual function and surgical satisfaction.

- Prevention of loss of vulvar architecture through adequate treatment of LS is superior to surgery.
- Psychosexual considerations and concomitant genitopelvic pain conditions must be addressed prior to consideration of surgery, except in cases of acute urinary retention.
- Surgical approaches are not treatment for LS but are sometimes indicated to restore genitourinary function.
- Preoperative objective control of the pallor and texture changes of LS is essential.
- Pre- and postoperative strategies to mitigate risks of koebnerization and re-adhesion include at least daily use of potent or super-potent topical corticosteroids, consideration of peri-operative topical estrogen in the setting of GSM, careful instruction regarding post-procedure care and manual pressure at the surgical site, judicious use of vaginal dilators and/or non-painful intercourse to maintain introital patency, and close specialist follow-up.

## References

1. Krapf J, Mautz T, Lorenzini S, Holloway J, Goldstein A. Clinical Presentation of Clitorodynia Associated with Clitoral Adhesions and Keratin Pearls. *J Sex Med.* 2022;19(Supplement\_3):S14-S14. doi:10.1016/j.jsxm.2022.05.032
2. Krapf JM, Mitchell L, Holton MA, Goldstein AT. Vulvar Lichen Sclerosus: Current Perspectives. *Int J Womens Health.* 2020;Volume 12:11-20. doi:10.2147/IJWH.S191200
3. Kherlopian A, Fischer G. Does compliance to topical corticosteroid therapy reduce the risk of development of permanent vulvar structural abnormalities in pediatric vulvar lichen sclerosus? A retrospective cohort study. *Pediatr Dermatol.* 2022;39(1):22-30. doi:10.1111/pde.14840
4. Lee A, Bradford J, Fischer G. Long-term Management of Adult Vulvar Lichen Sclerosus: A Prospective Cohort Study of 507 Women. *JAMA Dermatol.* 2015;151(10):1061. doi:10.1001/jamadermatol.2015.0643
5. Kirtschig G, Cooper S, Aberer W, et al. Evidence-based (S3) Guideline on (anogenital) Lichen sclerosus. *J Eur Acad Dermatol Venereol.* 2017;31(2). doi:10.1111/jdv.13740
6. Van Der Meijden WI, Boffa MJ, Ter Harnsel B, et al. 2021 European guideline for the management of vulval conditions. *J Eur Acad Dermatol Venereol.* 2022;36(7):952-972. doi:10.1111/jdv.18102
7. Chmel R, Nováčková M, Fait T, Zámečník L, Krejčová L, Pastor Z. Clitoral Phimosis: Effects on Female Sexual Function and Surgical Treatment Outcomes. *J Sex Med.* 2019;16(2):257-266. doi:10.1016/j.jsxm.2018.12.012
8. Bradford J, Fischer G. Surgical Division of Labial Adhesions in Vulvar Lichen Sclerosus and Lichen Planus. *J Low Genit Tract Dis.* 2013;17(1):48-50. doi:10.1097/LGT.0b013e31824f1427
9. Singh N, Mishra N, Ghatage P. Treatment Options in Vulvar Lichen Sclerosus: A Scoping Review. *Cureus.* Published online February 24, 2021. doi:10.7759/cureus.13527
10. Gurumurthy M, Morah N, Gioffre G, Cruickshank ME. The surgical management of complications of vulval lichen sclerosus. *Eur J Obstet Gynecol Reprod Biol.* 2012;162(1):79-82. doi:10.1016/j.ejogrb.2012.01.016
11. Flynn AN, King M, Rieff M, Krapf J, Goldstein AT. Patient Satisfaction of Surgical Treatment of Clitoral Phimosis and Labial Adhesions Caused by Lichen Sclerosus. *Sex Med.* 2015;3(4):251-255. doi:10.1002/sm2.90
12. Goldstein I. Surgical Techniques: Dorsal Slit Surgery for Clitoral Phimosis. *J Sex Med.* 2008;5(11):2485-2488. doi:10.1111/j.1743-6109.2008.01019.x

13. Rouzier R, Haddad B, Deyrolle C, Pelisse M, Moyal-Barracco M, Paniel BJ. Perineoplasty for the treatment of introital stenosis related to vulvar lichen sclerosus. *Am J Obstet Gynecol.* 2002;186(1):49-52. doi:10.1067/mob.2002.119186
14. Abramov Y, Elchalal U, Abramov D, Goldfarb A, Schenker JG. Surgical Treatment of Vulvar Lichen Sclerosus: A Review. *Obstet Gynecol Surv.* 1996;51(3):193-199. doi:10.1097/00006254-199603000-00023
15. Rojavin Y, Salgado CJ, Hsu PW, Liu J, Aikins JK. The surgical management of vulvar lichen sclerosus refractory to medical management. *J Plast Reconstr Aesthet Surg.* 2008;61(7):848-849. doi:10.1016/j.bjps.2007.10.076
16. Arnold S, Fernando S, Rees S. Living with vulval lichen sclerosus: a qualitative interview study. *Br J Dermatol.* 2022;187(6):909-918. doi:10.1111/bjd.21777
17. Sivalingam V, Tamber K. Understanding the impact of life with vulval lichen sclerosus. *Br J Dermatol.* 2022;187(6):840-840. doi:10.1111/bjd.21846
18. Vittrup G, Mørup L, Heilesen T, Jensen D, Westmark S, Melgaard D. Quality of life and sexuality in women with lichen sclerosus: a cross-sectional study. *Clin Exp Dermatol.* 2022;47(2):343-350. doi:10.1111/ced.14893
19. Pope R, Lee MH, Myers A, et al. Lichen Sclerosus and Sexual Dysfunction: A Systematic Review and Meta-Analysis. *J Sex Med.* 2022;19(11):1616-1624. doi:10.1016/j.jsxm.2022.07.011
20. Ranum A, Pearson DR. The impact of genital lichen sclerosus and lichen planus on quality of life: A review. *Int J Women's Dermatol.* 2022;8(3):e042. doi:10.1097/JW9.0000000000000042
21. Hodges KR, Wiener CE, Vyas AS, Turrentine MA. The Female Genital Self-image Scale in Adult Women With Vulvar Lichen Sclerosus. *J Low Genit Tract Dis.* 2019;23(3):210-213. doi:10.1097/LGT.00000000000000481
22. Parish SJ, Hahn SR, Goldstein SW, et al. The International Society for the Study of Women's Sexual Health Process of Care for the Identification of Sexual Concerns and Problems in Women. *Mayo Clin Proc.* 2019;94(5):842-856. doi:10.1016/j.mayocp.2019.01.009
23. Caspersen IS, Højgaard A, Laursen BS. The influence of lichen sclerosus on women's sexual health from a biopsychosocial perspective: a mixed methods study. *J Sex Med.* 2023;20(4):488-497. doi:10.1093/jsxm/qdad018
24. Vittrup G, Westmark S, Riis J, et al. The Impact of Psychosexual Counseling in Women With Lichen Sclerosus: A Randomized Controlled Trial. *J Low Genit Tract Dis.* 2022;26(3):258-264. doi:10.1097/LGT.0000000000000669
25. Kirtschig G, Kinberger M, Kreuter A, et al. *EuroGuiDerm Guideline: Lichen Sclerosus.* Published online 2023. Accessed March 9, 2024. <https://www.guidelines.edf.one/edf-guidelines-and-consensus-statements>
26. Brauer M, Van Lunsen R, Burger M, Laan E. Motives for Vulvar Surgery of Women with Lichen Sclerosus. *J Sex Med.* 2015;12(12):2462-2473. doi:10.1111/jsm.13052
27. Brauer M, Van Lunsen RHW, Laan ETM, Burger MPM. A Qualitative Study on Experiences After Vulvar Surgery in Women With Lichen Sclerosus and Sexual Pain. *J Sex Med.* 2016;13(7):1080-1090. doi:10.1016/j.jsxm.2016.04.072
28. Burrows LJ, Creasey A, Goldstein AT. The Treatment of Vulvar Lichen Sclerosus and Female Sexual Dysfunction. *J Sex Med.* 2011;8(1):219-222. doi:10.1111/j.1743-6109.2010.02077.x
29. Corazza M, Virgili A, Minghetti S, Borghi A. Dyspareunia in vulvar lichen sclerosus: an overview of a distressing symptom. *G Ital Dermatol Venereol.* 2020;155(3). doi:10.23736/S0392-0488.17.05849-7
30. Bradford J, Fischer G. Long-term management of vulval lichen sclerosus in adult women. *Aust N Z J Obstet Gynaecol.* 2010;50(2):148-152. doi:10.1111/j.1479-828X.2010.01142.x
31. Bornstein J, Goldstein AT, Stockdale CK, et al. 2015 ISSVD, ISSWSH and IPPS Consensus Terminology and Classification of Persistent Vulvar Pain and Vulvodinia. *Obstet Gynecol.* 2016;127(4):745-751. doi:10.1097/AOG.0000000000001359
32. Lamvu G, Carrillo J, Ouyang C, Rapkin A. Chronic Pelvic Pain in Women: A Review. *JAMA.* 2021;325(23):2381. doi:10.1001/jama.2021.2631
33. Ghaderi F, Bastani P, Hajebrahimi S, Jafarabadi MA, Berghmans B. Pelvic floor rehabilitation in the treatment of women with dyspareunia: a randomized controlled clinical trial. *Int Urogynecology J.* 2019;30(11):1849-1855. doi:10.1007/s00192-019-04019-3
34. Burger MPM, Obdeijn MC. Complications after surgery for the relief of dyspareunia in women with lichen sclerosus: a case series. *Acta Obstet Gynecol Scand.* 2016;95(4):467-472. doi:10.1111/aogs.12852
35. Morrison P, Kellogg Spadt S, Goldstein A. The Use of Specific Myofascial Release Techniques by a Physical Therapist to Treat Clitoral Phimosis and Dyspareunia. *J Womens Health Phys Ther.* 2015;39(1):17-28. doi:10.1097/JWH.0000000000000023
36. Ostrzenski A. A New, Hydrodissection with Reverse V-Plasty Technique for the Buried Clitoris Associated with Lichen Sclerosus. *J Gynecol Surg.* 2010;26(1):41-48. doi:10.1089/gyn.2009.0047
37. Aboud C, Cristinelli S, Roccaro G, Meningaud JP, Hersant B. Surgical treatment of clitoral phimosis. *J Gynecol Obstet Hum Reprod.* 2021;50(6):101919. doi:10.1016/j.jogoh.2020.101919
38. Lauber F, Vaz I, Krebs J, Günthert AR. Outcome of perineoplasty and de-adhesion in patients with vulvar Lichen sclerosus and sexual disorders. *Eur J Obstet Gynecol Reprod Biol.* 2021;258:38-42. doi:10.1016/j.ejogrb.2020.12.030

39. Myers MC, Romanello JP, Nico E, et al. A Retrospective Case Series on Patient Satisfaction and Efficacy of Non-Surgical Lysis of Clitoral Adhesions. *J Sex Med.* 2022;19(9):1412-1420. doi:10.1016/j.jssxm.2022.06.011
40. Singh P, Han HC. Labial adhesions in postmenopausal women: presentation and management. *Int Urogynecology J.* 2019;30(9):1429-1432. doi:10.1007/s00192-018-3821-1
41. Hatada Y. Two-step surgical approach to labial adhesions in a postmenopausal woman. *Acta Obstet Gynecol Scand.* 2003;82(11):1054-1055. doi:10.1034/j.1600-0412.2003.00028.x
42. Kaplan F, Alvarez J, Dwyer P. Nonsurgical separation of complete labial fusion using a Hegar dilator in postmenopausal women. *Int Urogynecology J.* 2015;26(2):297-298. doi:10.1007/s00192-014-2535-2
43. Cigna ST, Goldstein AT, Krapf J. Vulvar lysis of adhesions: surgical treatment of vulvar granuloma fissuratum. *Am J Obstet Gynecol.* 2021;224(6):622. doi:10.1016/j.ajog.2021.03.013
44. Kennedy CM, Dewdney S, Galask RP. Vulvar Granuloma Fissuratum: A Description of Fissuring of the Posterior Fourchette and the Repair. *Obstet Gynecol.* 2005;105(5, Part 1):1018-1023. doi:10.1097/01.AOG.0000158863.70819.53
45. Goldstein A. Perineoplasty and Vaginal Advancement Flap for Vulvar Granuloma Fissuratum. *J Sex Med.* 2011;8(11):2984-2987. doi:10.1111/j.1743-6109.2011.02528.x
46. Frappell J, Riadin L, Ebeid E, Asmussen T, Morris R. Double Opposing Zplasty with VY Advancement of the perineum. *Eur J Obstet Gynecol Reprod Biol.* 2018;223:46-49. doi:10.1016/j.ejogrb.2018.02.003
47. Rangatchew F, Knudsen J, Thomsen MV, Drzewiecki KT. Surgical treatment of disabling conditions caused by anogenital lichen sclerosus in women: An account of surgical procedures and results, including patient satisfaction, benefits, and improvements in health-related quality of life. *J Plast Reconstr Aesthet Surg.* 2017;70(4):501-508. doi:10.1016/j.bjps.2016.12.008
48. Butrick CW. Persistent Postoperative Pain: Pathophysiology, Risk Factors, and Prevention. *Female Pelvic Med Reconstr Surg.* 2016;22(5):390-396. doi:10.1097/SPV.0000000000000298
49. Lukacz ES, Warren LK, Richter HE, et al. Quality of Life and Sexual Function 2 Years After Vaginal Surgery for Prolapse. *Obstet Gynecol.* 2016;127(6):1071-1079. doi:10.1097/AOG.0000000000001442
50. Aydogan Mathyk B, Aslan Cetin B, Cetin H. Sexual function after Bartholin gland abscess treatment: A randomized trial of the marsupialization and excision methods. *Eur J Obstet Gynecol Reprod Biol.* 2018;230:188-191. doi:10.1016/j.ejogrb.2018.10.015
51. Tszchanz C, Salomon D, Skaria A, Masouyé I, Vecchietti GL, Harms M. Vulvodinia after CO2 Laser Treatment of the Female Genital Mucosa. *Dermatology.* 2001;202(4):371-372. doi:10.1159/000051686
52. Verstraelen H, De Zutter E, DeMuyncck M. Genitofemoral neuralgia: adding to the burden of chronic vulvar pain. *J Pain Res.* 2015;30(8):845-849. Doi:10.2147/JPR.S93107
53. Cooke CM, Flaxman TE, Chen I, Singh S. Safety and efficacy of ilioinguinal and iliohypogastric nerve blocks for treatment of pelvic pain. *J Endo Pelvic Pain Dis.* 2019;11(1):37-44. doi:10.1177/2284026518823383
54. Dickson E, Higgins P, Sehgal R et al. Role of nerve block as a diagnostic tool in pudendalnerve entrapment. *ANZ J Surg.* 2019;89(6):695-699. doi:10.1111/ans.15275

# Lichen sclerosis in childhood and adolescence

*Veronica Boero, Carlotta Caia, Elisa Pesce, Elisabeth Quint, Kalyani Marathe*  
Acknowledgement to medical photographer Caitlin Treuting

Children with lichen sclerosis (LS) may present to general practitioners (GP), pediatricians, dermatologists, pediatric and adolescent gynecologists, urologists, pediatric surgeons, or gastroenterologists.<sup>1,2</sup> Initial medical attendance and subsequent referral patterns depend on the young person's age, type of symptoms, and health system factors. Up to 15% of children with LS are asymptomatic and attend care for some other problem or due to personal or parental concern for change in vulvar skin color.<sup>2-4</sup> Symptoms in children are often combined, heterogeneous, subtle, and sometimes communicated via caregivers. Diagnosis is based on history and examination as obtaining biopsies in children usually requires sedation or general anesthetic. Treatment follows the same principles as LS in adults.

## Differences to adults in symptoms

The main symptoms of LS in women include pruritus, discomfort or burning, sexual pain, and noting changes to skin color or vulvar architecture. Children and their caregivers also may report itch and pain, but frequently describe night awakening with crying, irritability, dysuria, dyschezia, and constipation (see Chapter 2). Genital bleeding, ecchymoses, and petechiae may occur from rubbing or mild trauma and be mistaken for infection or sexual abuse.<sup>5</sup> The diagnosis of LS does not exclude sexual abuse and a suspicion for this should be referred to an experienced multidisciplinary team for further assessment.<sup>2,6</sup> Any form of genital injury or trauma may, through the Koebner phenomenon, act as a trigger for LS development in genetically predisposed children.<sup>7,8</sup>

## Differences to adults in vulvar examination

The general and anogenital examination of children and young adolescents requires different strategies to sexually active young people and adults.<sup>1,9,10</sup> The first step is to discuss with the patient and trusted caregivers what to expect and ask if they feel comfortable with the provider and setting planned for examination. Leading with general examination helps to establish trust and may detect extragenital LS.<sup>9</sup> Clinicians model open and reciprocal communication about the anogenital region using correct anatomical terms. The treating team



explains that the purpose of examination is to better understand the cause of symptoms and inform an effective care plan. It may be helpful to show and describe any anticipated tools, like a light or cotton-tip swab, prior to starting the examination.<sup>11</sup> Consent from the child to proceed is essential. If the child is not ready to undergo examination, schedule a future visit to revisit the issue. Never force a child to do a genital exam. If clinical photography is indicated or desired, explain this indication to the caregiver and obtain consent, gain assent from the patient if age-appropriate, and document the consent process according to institutional policies.

There are several options for examination positioning. Use of lithotomy positions with foot rests is inappropriate in children but may be considered in some older adolescents.<sup>10</sup> The child may lie down on the examination table, beside or on the lap of the caregiver, with knees open in a frog-leg position and soles of the feet touching.<sup>1</sup> Knee-chest or 'cannonball' position facilitates perianal examination. Do not place pressure on the child's extremities to achieve a position. Avoid words like 'relax' or 'finger' as these may trigger trauma in cases of previous sexual abuse.<sup>11</sup> Reassure the patient and caregiver they are in control and can say they wish to stop at any time. Slow movements, gentle touch, and calm instruction allow for progression through the examination. Posterolateral spreading optimizes visualization of labia minora and hymen. Avoid lateral traction in the event of labial adhesions. When obtaining a vulvar culture or molecular test, show the child the flocked swab and describe the sensation as 'tickling' rather than discomfort or pain. At the end, inform the child and caregiver they may return to a more comfortable position and get dressed. Once clothed and seated, use simple language to explain the examination findings and solicit questions or concerns.<sup>11</sup>

Common examination findings in children mirror those of adults: ivory or porcelain white color change, altered skin texture, ecchymoses, fissures, and changes to vulvar anatomy (see Chapter 3 and Fig 1). Fissures may provoke dysuria, frequency, dyschezia, and constipation depending on location, with symptoms usually resolving after institution of LS treatment.<sup>9,12,13</sup> Evidence of subepithelial hemorrhage occurs in up to one third of premenarchal LS cases.<sup>3,5</sup> Infantile pyramidal/perianal protrusions may accompany LS and relate to constipation.<sup>9</sup> Architectural change may be difficult to detect in prepubertal girls as the clitoral hood and labia minora remain small until exposed to estrogen (Fig 2,3). Dermoscopic features in pediatric LS mirror those in adults and include structureless areas with a whipped cream-like appearance, white chrysalis-like structures, erosions,

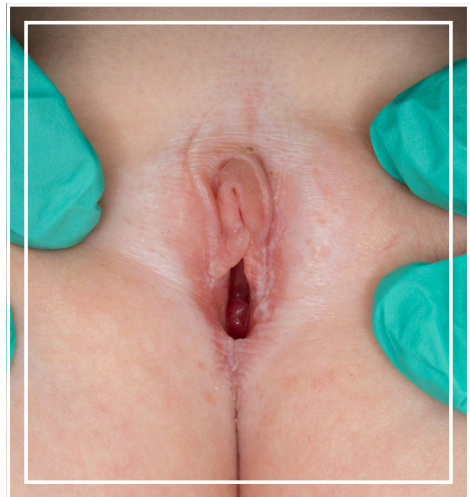
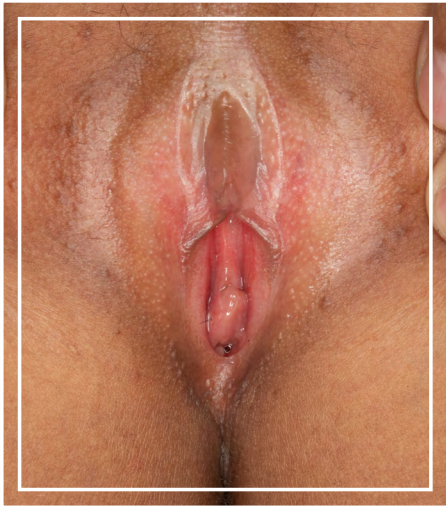
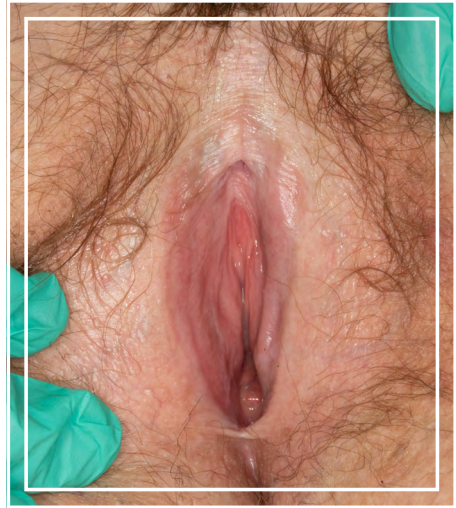FIGURE 1. Prepubertal child with LS: white color change, edema, and abnormal texture ranging from crinkly to hyperkeratotic.

and red-purpuric blotches.<sup>14</sup> Multiple scoring systems for examinations findings exist, but none has yet reached consensus or been validated across populations (see Chapter 16).



**FIGURE 2.** Pubertal child with architectural change due to LS: white color change over periclitoral structures and interlabial sulci, midline fusion of labia minora with clitoral phimosis.



**FIGURE 3.** Adolescent with architectural change due to LS: near normal color and texture with labial resorption and flattened prepuce.

Chronic inflammation from LS may increase the risk of vulvar melanocytic proliferations in childhood.<sup>9</sup> Dark lesions, especially those that increase in size, may provoke clinical concern and discussion of biopsy to exclude melanoma.<sup>15</sup> A systematic review identified 22 case series and reports describing childhood melanocytic nevi, many highlighting diagnostic pitfalls when these are concurrent with LS.<sup>16</sup> At least 42 children have been assigned the diagnosis of vulvar melanoma in case reports, series, or cohort studies published since 1973.<sup>16</sup> No mortality was reported among these cases and one lymph node metastasis was documented. Multiple authors have questioned the validity of a melanoma diagnosis in childhood, with these doubts further supported by zero cases of pediatric vulvar melanoma occurring over 30 years in the Netherlands.<sup>16</sup> Rather than biopsy or excision of vulvar pigmented lesions arising in children with LS, these cases benefit from referral to a specialized center with capacity for dermoscopy and serial photographic surveillance.

## Role of biopsy

The diagnosis of LS in children and young people is primarily clinical. Concern for neoplasia is low in this cohort, while diagnostic uncertainty and non-response to topical steroids are uncommon. If the diagnosis is uncertain, it is often preferable to refer to an expert in pediatric genital dermatoses rather than arrange for biopsy under general anesthetic.

The histopathologic diagnosis of LS is the same across age groups (see Chapter 4). Prepubertal children demonstrate a range of histopathologic findings, from dense inflammation

overlying a band of hyalinized collagen, to subtle lichenoid dermatitis, to an inactive appearance lacking lymphocytic infiltrate or basal layer damage. In a study of 100 biopsies diagnostic for LS in children under 18 years, epidermal atrophy occurred in 50% and vacuolar change was seen in 88%.<sup>17</sup> The number of vessels was generally normal but 88% had dilated vessels and 23% had perivascular hyalinization. Biopsies from younger girls more often included hair follicles and sweat glands, suggesting sampling of the labia majora.<sup>17</sup> The authors suggest this is associated with the smaller size of periclitoral and labial structures, perhaps discouraging practitioners from performing biopsies at these sites. As in adults, biopsy from clinically obvious LS may be non-diagnostic due to a lack of dermal sclerosis. Critical evaluation of clinicopathologic studies across the age spectrum does not support a consistent correlation between dermal features and the duration or activity of disease.<sup>18</sup> The term ‘non-sclerotic lichen sclerosus’ is thus a more accurate way to conceptualize this clinicopathologic situation, rather than using a temporal descriptor like ‘early LS.’

Histologic assessment of pigmented lesions in LS is difficult. Inflammation provokes reactive changes in melanocytes that resemble features of atypia, and epidermal atrophy may “mimic the epidermal consumption sometimes seen in melanoma.”<sup>16</sup> Intracellular breakdown, or acantholysis, may be seen in genital nevi arising in LS, likewise provoking confusion with melanoma. Given the rarity of concurrent LS and melanocytic proliferations in children, these specimens and associated immunohistochemical studies require expert multidisciplinary assessment. Clinicians should not pursue surgical excision based on a pathologic diagnosis of childhood vulvar melanoma in the absence of this high-level review.<sup>16,19</sup>

## What happens in adolescence?

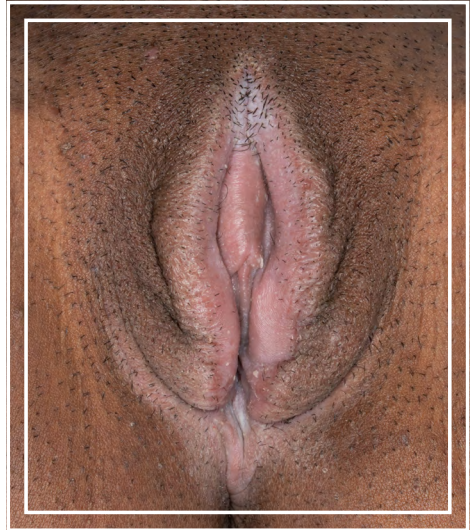The trajectory of LS from adolescence into adulthood is difficult to study and likely involves substantial variation between individuals. Publications on this topic often involve small study sizes, non-validated assessments of symptoms and disease severity, loss to follow-up, and insufficient duration of observation.<sup>20,21</sup> Another challenge is the categorization of patients who have ceased topical steroids into ‘resolved’ or ‘affected.’<sup>21</sup> Persistent symptoms and objectively active disease both qualify as ‘affected.’ However, some patients are asymptomatic with normal skin texture and color but have architectural alterations. It is unknown if this represents recovery with residual anatomic change, temporary quiescence, or ongoing disease activity.<sup>21,22</sup>

Investigators relying on verbal reports of post-pubertal symptoms document ‘regression’ rates of 60–72%.<sup>3,23,24</sup> This is likely an overestimation due to both asymptomatic status and reporting bias. Studies of post-pubertal girls and young women with known premenarchal LS document persistent symptoms, signs, or both in 58–89%.<sup>4,20–22,25–27</sup> This body of evidence overturns the longstanding idea that childhood vulvar LS remits at puberty. Instead, some children experience symptomatic quiescence during adolescence, but the disease may remain active with symptoms and signs sometimes becoming more apparent in adulthood. To date, there is no mechanism for identifying girls who will have persistent disease activity throughout their lives, those who will experience a prolonged period of relative quiescence, and those who will resolve after menarche. As a result, clinicians should offer ongoing sur-

veillance at least annually for patients with pediatric LS until they reach adulthood when their trajectory is more apparent and they achieve autonomy over medical decision-making.<sup>3,4,9</sup>

## Differences to adults in comorbid medical and dermatologic conditions

Girls with Turner syndrome have a 17% life-time risk of LS, with 50% being asymptomatic, so may benefit from vulvar surveillance beginning in adolescence.<sup>9,27,28</sup> Candidal superinfection is rare in prepubertal immunocompetent girls, but Group A streptococcal vulvovaginitis is more common in children than adults.<sup>6</sup> The three dermatoses most frequently seen in premenarchal girls are acute or chronic contact dermatitis, psoriasis, and vitiligo and their manifestations resemble those of adults (see Chapter 5 and Fig 4).<sup>6,9,29</sup> Several small series describe diagnostic difficulty in comorbid vitiligo and LS.<sup>14,30,31</sup> Vitiligo may be isolated to the vulva but usually lacks symptoms. When LS and vitiligo occur together on the vulva, distinguishing features of LS are mild erythema, texture abnormalities, and purpuric areas.<sup>6,14</sup> Dermoscopic features of the two conditions differ and this technique helps clinicians to determine the distribution of each entity without biopsy. Erosive lichen planus and plasma cell vulvitis are rarely identified in children. Chronic vulvar, bladder, and bowel pain conditions are likely under-reported during childhood and may be comorbid with LS as they are in adulthood.<sup>32,33</sup>



**FIGURE 4.** Adolescent with LS and superimposed LSC: grey-pink color change and edema over prepuce, interlabial sulci, inner labia minora, and perineum, increased skin markings at labia majora, and thickened white color change at the anterior commissure and posterior fourchette.

## Treatment strategies specific to pediatric lichen sclerosus

### Initial and maintenance therapy with topical steroids

Identification and treatment of pediatric LS plays a crucial role in prevention of permanent disease impacts. The goal of treatment is to improve symptoms, achieve normal texture and normal to near-normal color, prevent or stabilize architectural change, and reduce the risk of squamous cell carcinoma (SCC) (see Chapter 6). Treatment involves initial therapy with topical corticosteroids and a long-term steroid maintenance regimen. Prescription of topical steroids is accompanied by an explanation to the child and caregiver of the reasons for and goals of treatment, amount to use, and site of application.

British, European, and North American guidelines endorse a daily super-potent or potent

steroid as initial treatment in children, as in adults.<sup>9,10,34</sup> Multiple case series of girls with prepubertal diagnosis of LS, each less than 75 patients, describe use of clobetasol propionate 0.05% ointment daily for several months followed by 'as needed' use and report rates of symptom improvement from 50 to 100% and disease control from 18 to 40%.<sup>25-27,35,36</sup> Another well-documented treatment approach is betamethasone dipropionate 0.05% or methylprednisolone aceponate 0.1% ointment daily until remission, followed by a maintenance regimen tailored to the treatment goals of normalized color and texture. This strategy yielded subjective and objective control in 72-83% of patients.<sup>4,22</sup>

The literature on maintenance therapy in children is scant. Most studies report symptom-driven intermittent use of clobetasol propionate with variable reporting of objective disease activity, 'relapse' rates, and long-term outcomes.<sup>20,37</sup> Extrapolating from adults, maintenance usually involves the same steroid with lower frequency or a lower potency steroid daily.<sup>2,4</sup> Using a treatment goal of objective disease control, 46% of 46 girls were successful with a maintenance regimen of methylprednisolone aceponate 0.1% on weekends and hydrocortisone acetate 1% on weekdays, while 30% (14/46) required daily hydrocortisone acetate 1% ointment.<sup>4</sup> The remainder used other low to medium potency steroids alone or in combination and only 1 child needed a potent steroid daily to achieve disease control. Organizing a first follow-up at one to three months to assess response is a commonly recommended strategy, with ongoing surveillance visits once or twice a year. Taken as a whole, studies on pediatric LS suggests several similarities between children and adults in the therapeutic approach: 1) subjective improvement is easier to obtain than objective disease control, 2) a one-size-fits-all steroid regimen may overtreat those with mild LS and undertreat those with severe disease, and 3) intermittent 'as needed' regimens are unlikely to reliably produce adequate long-term disease control in many girls affected by LS.<sup>4,38</sup>

## Safety of topical steroids in children

Systemic absorption from topical steroid use on the pediatric vulva is rare. A meta-analysis calculated the rate of laboratory-detected hypothalamic-pituitary-adrenal suppression at less than 7%, even with high potency steroids applied over a large surface area for severe atopic dermatitis.<sup>39</sup> The authors did not recommend testing for adrenal suppression in absence of signs and symptoms. One case report described development of Cushing's syndrome in a six-year-old girl with vulvar LS treated for eight weeks with 0.05% clobetasol ointment, resolving after cessation of topical steroid treatment.<sup>40</sup> Robust evidence from children with eczema demonstrates that long-term topical steroids do not cause skin atrophy or striae unless used inappropriately at groins or axilla or with occlusive dressings.<sup>41,42</sup> A study using daily clobetasol propionate 0.05% ointment in children for initial LS therapy reported telangiectasia in 19%, suggesting a less potent steroid may be more suitable as initial therapy in some children (Fig 5).<sup>10,25</sup> Other treatment-related side effects include erythema and candidiasis, with the latter more likely in post-pubertal girls. Erythema reflects steroid overuse, occurs at rates of 5-13%, and resolves with reduction in steroid potency or frequency.<sup>4,25</sup> Clinicians may reassure caregivers and patients that an individualized regimen of topical steroid treatment and maintenance is safe when used under direction of an experienced



clinician and ongoing monitoring permits assessment of medication-related symptoms and titration of dosing.

### Barriers to topical steroid use specific to children

If children or their caregivers report non-response to steroids, the clinician takes a systematic approach as done in adults to identify the reasons and develop a management plan (see Chapter 9). While there are no studies devoted to pediatric LS, the childhood eczema literature suggests steroid phobia is common, reinforced by social media, and leads to treatment under-utilization.<sup>43</sup> The instruction to 'use sparingly' increases parental concerns

about steroids and creates an impression they should only be applied when skin disease is severe.<sup>41</sup> A qualitative study of caregivers revealed they all had been told by friends, pharmacists, and/or GPs that topical steroids are dangerous and the majority stated a preference for 'natural therapy'.<sup>44</sup> Parents and caregivers often expressed difficulty with the concept of chronic disease management, perceiving steroids as 'masking' rather than treating the underlying disease and believing there was a reversible cause for their child's condition that had not yet been detected.<sup>44</sup> As in adults, recurring access to a knowledgeable specialist, thorough and repeated counseling, and provision of written and online resources may reduce anxiety and improve adherence to recommended treatment strategies.

### Alternatives to topical steroids in children

Several guidelines identify topical calcineurin inhibitors as a therapeutic option in children who develop steroid-related side effects or report intolerance to topical steroids.<sup>9,10</sup> Limited evidence documents improvement in symptoms and objective LS control in children, but the adult literature suggests they are less effective than steroids for suppression of inflammation.<sup>10,45</sup> Several case series of 14 or fewer patients describe use of tacrolimus 0.03% ointment once to twice daily for 6 to 16 weeks or pimecrolimus 1% cream daily for 3-4 months as initial therapy.<sup>46-49</sup> A Chinese study documented adverse effects of burning sensation in 21% and itching in 14%.<sup>47</sup> A series of 14 girls reported a 93% total objective response rate with initial clobetasol propionate ointment treatment until objective clearance, then twice-weekly maintenance therapy with tacrolimus.<sup>50</sup> Anecdotally, clinicians find topical calcineurin inhibitors most helpful as part of maintenance therapy when children express intolerance to steroids, they insist on self-administration but their application is imprecise, and/or they report symptoms with less than daily use of steroids but show signs of overuse. There are no long-term studies assessing the outcomes of architectural change and cancer risk in LS patients exclusively managed on topical calcineurin inhibitors.

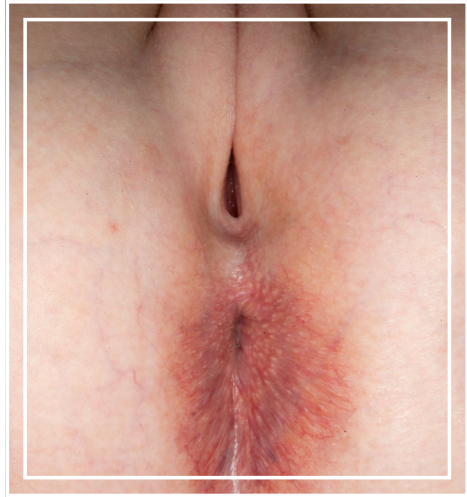


FIGURE 5. Perianal telangiectasia in a prepubertal child with LS.

Calcineurin inhibitors are inappropriate in children under age 2.<sup>9</sup> Use of retinoids, platelet-rich-plasma injections, phototherapy, photodynamic therapy, or laser in children with LS should be considered experimental and reserved for unusual cases managed by experts in pediatric genital dermatoses.<sup>10</sup> Indications for surgery in children are restricted to urinary outflow obstruction due to adhesive disease or biopsy demonstrating neoplasia after expert multidisciplinary review.

## Vulvar care advice specific to children

As in adults, marketing trends promote hygiene practices and products that run counter to medical recommendations for childhood skin care. International pediatrics and dermatology societies advise that young children bathe and shampoo two to three times per week with application of hypoallergenic non-fragranced emollients afterwards. General diaper care advice involves wiping with water-moistened soft cloths or WaterWipes™ and then applying a petrolatum-based emollient.<sup>51</sup> A survey of parents about child-specific hygiene products identified pre-moistened wipes, baby oil/lotion, and baby shampoo/wash as the most frequently purchased with an average use of 21, 9, and 5 times per week respectively.<sup>52</sup> Lower income was correlated with higher consumption of baby products. Parents reported they would spend more money for products containing botanical ingredients like lavender or aloe vera. Clinicians preempt misleading marketing claims with proactive acknowledgment that contact allergies occur with many ‘natural’ additives and provision of guidance around suitable alternatives.

Avoidance of heat, moisture, friction, and prolonged exposure to urine or feces aids in vulvar skin health (see Chapter 7). A soap-free bath may be soothing and some sources advise adding a half cup or vinegar or 1-2 tablespoons of baking soda to the water. Use of a peri bottle or urination in the shower may reduce dysuria relating to vulvar fissures. Cool compresses or chilled medications may relieve mild skin discomfort or burning sensation on application of topicals.<sup>9</sup> Emollients serve as a helpful adjunct to vulvar care and LS management. While one randomized trial in adults focused on Vitamin E oil, any simple ointment or oil serves as an emollient and enhances the skin’s barrier function.<sup>53</sup> Emollient use improves LS symptoms, but is not a substitute for topical steroids in management of clinical signs, architectural change, or mitigation of long-term neoplastic risk.

## Long-term sequelae of undertreated pediatric lichen sclerosis

Among post-pubertal girls and reproductive-age women with LS, 30-66% report their symptoms began before menarche.<sup>3,54</sup> Earlier age at symptom onset correlates with longer interval to diagnosis.<sup>54</sup> Multiple series document an unacceptable delay in diagnosis of 1.3-1.7 years and array of erroneous diagnoses provided to girls with LS.<sup>2,4,27,55</sup> A study of pediatric trainees identified a lack of knowledge, comfort, and confidence in prepubertal vulvovaginal conditions compared to general medical topics.<sup>56</sup>

Inadequate identification and treatment of childhood LS likely increases the risk of long-term sequelae to include architectural change, quality of life impacts, sexual dysfunction,



and development of SCC.<sup>4,27,38,55,57</sup> A 2020 systematic review found only 37 publications addressing long-term implications of LS diagnosed in childhood: 13 cohort studies, 19 case series of 5 or more patients, and 5 reports of 4 or fewer patients.<sup>20</sup> Reported rates of architectural change vary from 20-97% and most studies do not comment on the ramifications experienced by these patients in adulthood.<sup>20,58</sup> Adherence to an individualized maintenance regimen may reduce these rates, with one study documenting progressive anatomic change in 11% of prepubertal girls with LS who used steroids as directed, compared to 62% who did not.<sup>38</sup> Two studies addressed the risk of neoplasia and both suggest that childhood LS diagnosis was associated with the highest lifetime rates of vulvar cancer, although the absolute risk in young women is low.<sup>20,59,60</sup>

A questionnaire study followed by qualitative analysis of 80 and 27 women respectively with histologic diagnosis of LS during childhood highlighted multiple shortfalls in medical care and age-appropriate counseling.<sup>61,62</sup> On reflection of their childhood experiences, 37.5% were not informed they had LS and 34% did not receive topical steroid treatment.<sup>61</sup> They had high rates of recollected symptoms: 82.5% endorsed itch, 57.5% anatomic changes, 56% pain, 40% with urinary or bowel difficulties, and 22.5% had bleeding. As adults, 60% had LS-related impacts on the Dermatology Life Quality Index and 52% showed sexual dysfunction on the Female Sexual Function Index. Only 45% of these women reported attending surveillance visits for LS. On thematic assessment of interviews, women expressed feeling misunderstood and dismissed as children and unable to seek clarification about the diagnosis, management, and potential life impacts.<sup>62</sup> Many reported that follow-up was ceased during childhood, sometimes by a healthcare provider and sometimes by child-caregiver dyads due to asymptomatic status, a perception it was unnecessary, or loss of interest during adolescence. Women lamented the ignorance about LS among the general population and hoped for more coverage in school curricula and the popular press. Based on this qualitative work, the authors identified a need for clinical guidance on LS tailored to life stage, with practical information about treatment, adherence, and provoking factors during the younger years and a shift to discussion of sexuality and psychological impacts during adolescence.

## Limitations of the literature

Small sample sizes, varied management approaches, non-standardized outcome measures, and loss to follow-up are common methodologic limitations of studies on childhood LS. The lack of clearly stated treatment goals and high rates of persistent symptoms and signs suggest myriad opportunities for clinicians and researchers to improve the quality of care and counseling provided to affected young people. Recent publications on the experiences of young women diagnosed in childhood serve as a call to action to produce patient materials and clinical guidelines tailored to each life stage that incorporate recent knowledge acquisition about preventing long-term sequelae of undertreated LS.

## Conclusions and recommendations

The detection and treatment of childhood LS shares many features with adult disease but requires a distinct approach to examination, counseling, maintenance therapy, and fol-

low-up. Effective treatment of LS in children improves skin, bowel, and bladder symptoms and preserves the capacity to develop periclitoral and labial structures during puberty. Clinicians should anticipate that LS will remain active through adolescence and adulthood, even if symptoms remit during this time. Ongoing maintenance therapy and at least annual surveillance likely prevent progressive architectural change and reduce the long-term risk of malignancy.

- The diagnosis of childhood LS is clinical and biopsy is rarely indicated.
- Topical steroid ointments are the mainstay of initial treatment and maintenance therapy.
- Topical calcineurin inhibitors have a limited role as adjunctive or maintenance therapy, but long-term outcome data are lacking.
- The incidence of vulvar melanoma in childhood is either non-existent or exceedingly rare and biopsy of pigmented lesions arising in LS is usually inadvisable.
- Clinicians with experience in pediatric genital dermatoses are best placed to provide individualized management and long-term surveillance of LS diagnosed in childhood.

## References

1. Eyk NV, Allen L, Giesbrecht E, et al. Pediatric vulvovaginal disorders: a diagnostic approach and review of the literature. *J Obstet Gynaecol Can JOGC*. 2009;31(9):850-862. doi:10.1016/S1701-2163(16)34304-3
2. Ismail D, Owen CM. Pediatric vulval lichen sclerosis: a retrospective study. *Clin Exp Dermatol*. 2019;44(7):753-758. doi:10.1111/ced.13894
3. Winfrey OK, Fei YF, Dendrinis ML, Rosen MW, Smith YR, Quint EH. Lichen Sclerosis throughout Childhood and Adolescence: Not Only a Premenarchal Disease. *J Pediatr Adolesc Gynecol*. 2022;35(6):624-628. doi:10.1016/j.jpjg.2022.08.011
4. Ellis E, Fischer G. Prepubertal-Onset Vulvar Lichen Sclerosis: The Importance of Maintenance Therapy in Long-Term Outcomes. *Pediatr Dermatol*. 2015;32(4):461-467. doi:10.1111/pde.12597
5. Di Giuseppe J, Delli Carpini G, Giannella L, et al. A Longitudinal Multiinstitutional Study of Vulvar Lichen Sclerosis: From Childhood to Perimenopause. *J Low Genit Tract Dis*. 2024;28(3):276-281. doi:10.1097/LGT.0000000000000816
6. Menta N, Nussbaum D, Khilnani A, Dowlut-McElroy T, Habeshian KA. Insights from a joint pediatric dermatology-gynecology vulvar clinic: A retrospective study. *Pediatr Dermatol*. 2024;41(1):41-45. doi:10.1111/pde.15489
7. Warrington SA, de San Lazaro C. Lichen sclerosis et atrophicus and sexual abuse. *Arch Dis Child*. 1996;75(6):512-516. doi:10.1136/adc.75.6.512
8. Wood PL, Bevan T. Lesson of the week Child sexual abuse enquiries and unrecognised vulval lichen sclerosis et atrophicus. *BMJ*. 1999;319(7214):899-900. doi:10.1136/bmj.319.7214.899
9. Simms-Cendan J, Hoover K, Marathe K, Tyler K. NASPAG Clinical Opinion: Diagnosis and Management of Lichen Sclerosis in Pediatric and Adolescent Patients. *J Pediatr Adolesc Gynecol*. 2022;35(2):112-120. doi:10.1016/j.jpjg.2021.09.008
10. Kirtschig G, Kinberger M, Kreuter A, et al. EuroGuiDerm Guideline: *Lichen Sclerosis*. Published online 2023. Accessed March 9, 2024. <https://www.guidelines.edf.one/edf-guidelines-and-consensus-statements>
11. Habeshian K, Fowler K, Gomez-Lobo V, Marathe K. Guidelines for pediatric anogenital examination: Insights from our vulvar dermatology clinic. *Pediatr Dermatol*. 2018;35(5):693-695. doi:10.1111/pde.13586
12. Arlen AM, Wang M, Vash-Margita A. Lichen Sclerosis in Prepubertal Girls: An Uncommon but Treatable Cause of Lower Urinary Tract Symptoms. *Urology*. 2020;137:e1-e2. doi:10.1016/j.urology.2019.12.029
13. Wang M, Arlen AM, Vash-Margita A. Characteristics Among Premenarchal Girls With Lichen Sclerosis. *J Low Genit Tract Dis*. 2021;25(2):152-157. doi:10.1097/LGT.0000000000000584
14. Veronesi G, Virdi A, Leuzzi M, et al. Vulvar vitiligo and lichen sclerosis in children: A clinical challenge. *Pediatr Dermatol*. 2021;38(5):1012-1019. doi:10.1111/pde.14771
15. Mulcahy M, Scurry J, Day T, Otton G. Genital melanocytic naevus and lichen sclerosis. *Pathology (Phila)*. 2013;45(6):616-618. doi:10.1097/PAT.0b013e3283653b5d
16. Morrel B, van der Avoort IAM, Damman J, Mooyaart AL, Pasmans SGMA. A Scoping Review and Population Study Regarding Prevalence and Histopathology of Juvenile Vulvar Melanocytic Lesions. A Recommendation. *JID Innov Skin Sci Mol Popul Health*. 2022;2(5):100140. doi:10.1016/j.xjidi.2022.100140

17. Morrel B, Ewing-Graham PC, Van Der Avoort IAM, Pasmans SGMA, Damman J. Structured analysis of histopathological characteristics of vulvar lichen sclerosis in a juvenile population. *Hum Pathol.* 2020;106:23-31. doi:10.1016/j.humpath.2020.09.003
18. Day T, Selim MA, Allbritton JI, Scurry J, Committee (DPDC) for the IDPD. Nonsclerotic Lichen Sclerosis: Definition of a Concept and Pathologic Description. *J Low Genit Tract Dis.* 2023;27(4):358. doi:10.1097/LGT.0000000000000760
19. Morrel B, Pasmans SGMA, Mooyart AL, van der Avoort IAM. Tread carefully when considering vulvar melanoma in a child or adolescent. *Skin Health Dis.* 2023;3(4):e233. doi:10.1002/ski2.233
20. Morrel B, van Eersel R, Burger CW, et al. The long-term clinical consequences of juvenile vulvar lichen sclerosis: A systematic review. *J Am Acad Dermatol.* 2020;82(2):469-477. doi:10.1016/j.jaad.2019.08.030
21. Boero V, Cavalli R, Caia C, et al. Pediatric vulvar lichen sclerosis: Does it resolve or does it persist after menarche? *Pediatr Dermatol.* 2023;40(3):472-475. doi:10.1111/pde.15308
22. Smith SD, Fischer G. Childhood Onset Vulvar Lichen Sclerosis Does Not Resolve at Puberty: A Prospective Case Series. *Pediatr Dermatol.* 2009;26(6):725-729. doi:10.1111/j.1525-1470.2009.01022.x
23. Kammire MS, Anderson K, Howell JO, McShane DB, Corley SB, Morrell DS. Pediatric Vulvar Lichen Sclerosis: A Survey of Disease Course. *J Pediatr Adolesc Gynecol.* 2021;34(5):597-602. doi:10.1016/j.jpjag.2021.04.010
24. Focseneanu MA, Gupta M, Squires KC, Bayliss SJ, Berk D, Merritt DF. The course of lichen sclerosis diagnosed prior to puberty. *J Pediatr Adolesc Gynecol.* 2013;26(3):153-155. doi:10.1016/j.jpjag.2012.12.002
25. Casey GA, Cooper SM, Powell JJ. Treatment of vulvar lichen sclerosis with topical corticosteroids in children: a study of 72 children. *Clin Exp Dermatol.* 2015;40(3):289-292. doi:10.1111/ced.12519
26. Powell J, Wojnarowska F. Childhood vulvar lichen sclerosis: an increasingly common problem. *J Am Acad Dermatol.* 2001;44(5):803-806. doi:10.1067/mjd.2001.113474
27. Lagerstedt M, Karvinen K, Joki-Erkkilä M, Huotari-Orava R, Snellman E, Laasanen S. Childhood Lichen Sclerosis—A Challenge for Clinicians. *Pediatr Dermatol.* 2013;30(4):444-450. doi:10.1111/pde.12109
28. Chakhtoura Z, Vigoureux S, Courtillot C, Tejedor I, Touraine P. Vulvar lichen sclerosis is very frequent in women with Turner syndrome. *J Clin Endocrinol Metab.* 2014;99(4):1103-1104. doi:10.1210/jc.2013-3480
29. Fischer G, Rogers M. Vulvar Disease in Children: A Clinical Audit of 130 Cases. *Pediatr Dermatol.* 2000;17(1):1-6. doi:10.1046/j.1525-1470.2000.01701.x
30. Dennin MH, Stein SL, Rosenblatt AE. Vitiligo variant of lichen sclerosis in young girls with darker skin types. *Pediatr Dermatol.* 2018;35(2):198-201. doi:10.1111/pde.13399
31. Sink JR, Silverberg NB. Genital vitiligo in children: Factors associated with generalized, non-segmental vitiligo. *Pediatr Dermatol.* 2020;37(1):64-68. doi:10.1111/pde.13998
32. Dunford A, Rampal D, Kielly M, Grover SR. Vulval Pain in Pediatric and Adolescent Patients. *J Pediatr Adolesc Gynecol.* 2019;32(4):359-362. doi:10.1016/j.jpjag.2019.03.005
33. Doiron RC, Kogan BA, Tolls V, Irvine-Bird K, Nickel JC. Childhood bladder and bowel dysfunction predicts irritable bowel syndrome phenotype in adult interstitial cystitis/bladder pain syndrome patients. *Can Urol Assoc J Assoc Urol Can.* 2017;11(8):255-259. doi:10.5489/cuaj.4251
34. Lewis FM, Tatnall FM, Velangi SS, et al. British Association of Dermatologists guidelines for the management of lichen sclerosis, 2018. *Br J Dermatol.* 2018;178(4):839-853. doi:10.1111/bjd.16241
35. Patrizi A, Gurioli C, Medri M, Neri I. Childhood Lichen Sclerosis: A Long-Term Follow-up. *Pediatr Dermatol.* 2010;27(1):101-103. doi:10.1111/j.1525-1470.2009.01050.x
36. Smith Y. Clobetasol propionate in the treatment of premenarchal vulvar lichen sclerosis. *Obstet Gynecol.* 2001;98(4):588-591. doi:10.1016/S0029-7844(01)01496-X
37. Mashayekhi S, Flohr C, Lewis FM. The treatment of vulval lichen sclerosis in prepubertal girls: a critically appraised topic. *Br J Dermatol.* 2017;176(2):307-316. doi:10.1111/bjd.15202
38. Kherlopian A, Fischer G. Does compliance to topical corticosteroid therapy reduce the risk of development of permanent vulvar structural abnormalities in pediatric vulvar lichen sclerosis? A retrospective cohort study. *Pediatr Dermatol.* 2022;39(1):22-30. doi:10.1111/pde.14840
39. Wood Heckman LK, Davallow Gajjar L, Conaway M, Rogol AD. Evaluation of Hypothalamic-Pituitary-Adrenal Axis Suppression following Cutaneous Use of Topical Corticosteroids in Children: A Meta-Analysis. *Horm Res Paediatr.* 2018;89(6):389-396. doi:10.1159/000489125
40. Notay M, Fazel N, Awasthi S. Cushing Syndrome Induced by Topical Corticosteroids for the Treatment of Lichen Sclerosis. *J Pediatr Adolesc Gynecol.* 2019;32(1):83-85. doi:10.1016/j.jpjag.2018.09.004
41. Mooney E, Rademaker M, Dailey R, et al. Adverse effects of topical corticosteroids in paediatric eczema: A Australasian consensus statement. *Australas J Dermatol.* 2015;56(4):241-251. doi:10.1111/ajd.12313

42. Hong E, Smith S, Fischer G. Evaluation of the Atrophogenic Potential of Topical Corticosteroids in Pediatric Dermatology Patients. *Pediatr Dermatol*. 2011;28(4):393-396. doi:10.1111/j.1525-1470.2011.01445.x
43. Nickles MA, Coale AT, Henderson WJA, Brown KE, Morrell DS, Nieman EL. Steroid phobia on social media platforms. *Pediatr Dermatol*. 2023;40(3):479-482. doi:10.1111/pde.15269
44. Smith SD, Hong E, Fearnis S, Blaszczyński A, Fischer G. Corticosteroid phobia and other confounders in the treatment of childhood atopic dermatitis explored using parent focus groups. *Australas J Dermatol*. 2010;51(3):168-174. doi:10.1111/j.1440-0960.2010.00636.x
45. Goldstein AT, Creasey A, Pfau R, Phillips D, Burrows LJ. A double-blind, randomized controlled trial of clobetasol versus pimecrolimus in patients with vulvar lichen sclerosis. *J Am Acad Dermatol*. 2011;64(6):e99-e104. doi:10.1016/j.jaad.2010.06.011
46. Mazzilli S, Diluvio L, Di Prete M, et al. Tacrolimus 0.03% ointment for treatment of paediatric lichen sclerosis: a case series and literature review. *J Int Med Res*. 2018;46(9):3724-3728. doi:10.1177/0300060518778219
47. Li Y, Xiao Y, Wang H, Li H, Luo X. Low-concentration topical tacrolimus for the treatment of anogenital lichen sclerosis in childhood: maintenance treatment to reduce recurrence. *J Pediatr Adolesc Gynecol*. 2013;26(4):239-242. doi:10.1016/j.jpjag.2012.11.010
48. Boms S, Gambichler T, Freitag M, Altmeyer P, Kreuter A. Pimecrolimus 1% cream for anogenital lichen sclerosis in childhood. *BMC Dermatol*. 2004;4(1):14. doi:10.1186/1471-5945-4-14
49. Böhm M, Frieling U, Luger TA, Bonsmann G. Successful treatment of anogenital lichen sclerosis with topical tacrolimus. *Arch Dermatol*. 2003;139(7):922-924. doi:10.1001/archderm.139.7.922
50. Anderson K, Ascanio NM, Kinney MA, Krowchuk DP, Jorizzo JL. A retrospective analysis of pediatric patients with lichen sclerosis treated with a standard protocol of class I topical corticosteroid and topical calcineurin inhibitor. *J Dermatol Treat*. 2016;27(1):64-66. doi:10.3109/09546634.2015.1054777
51. Rogers S, Thomas M, Chan B, Hinckley SK, Henderson C. A Quality Improvement Approach to Perineal Skin Care: Using Standardized Guidelines and Novel Diaper Wipes to Reduce Diaper Dermatitis in NICU Infants. *Adv Neonatal Care*. 2021;21(3):189-197. doi:10.1097/ANC.0000000000000795
52. Gao X, Simpson EL. Market Trends in Baby Skin Care Products and Implications for Clinical Practice. *Pediatr Dermatol*. 2014;31(6):734-738. doi:10.1111/pde.12424
53. Virgili A, Minghetti S, Borghi A, Corazza M. Long-term maintenance therapy for vulvar lichen sclerosis: the results of a randomized study comparing topical vitamin E with an emollient. *Eur J Dermatol EJD*. 2013;23(2):189-194. doi:10.1684/ejd.2013.1987
54. Krapf JM, Smith AB, Cigna ST, Goldstein AT. Presenting Symptoms and Diagnosis of Vulvar Lichen Sclerosis in Premenopausal Women: A Cross-Sectional Study. *J Low Genit Tract Dis*. 2022;26(3):271-275. doi:10.1097/LGT.0000000000000679
55. Nerantzoulis I, Grigoriadis T, Michala L. Genital lichen sclerosis in childhood and adolescence—a retrospective case series of 15 patients: early diagnosis is crucial to avoid long-term sequelae. *Eur J Pediatr*. 2017;176(10):1429-1432. doi:10.1007/s00431-017-3004-y
56. Rosen MW, Alaniz VI, Kobernik EK, Booms S, Smith YR, Quint EH. Pediatric Resident Training in Prepubertal Vulvar Conditions. *J Pediatr Adolesc Gynecol*. 2018;31(1):7-12. doi:10.1016/j.jpjag.2017.09.002
57. Van De Nieuwenhof HP, Meeuwis KAP, Nieboer TE, Vergeer MCM, Massuger LFAG, De Hullu JA. The effect of vulvar lichen sclerosis on quality of life and sexual functioning. *J Psychosom Obstet Gynecol*. 2010;31(4):279-284. doi:10.3109/0167482X.2010.507890
58. Morrel B, Ten Kate-Booij MJ, van Dijk C, et al. Outcome Measures in Adult Vulvar Lichen Sclerosis: A Case Series of Women Diagnosed as Juveniles. *J Low Genit Tract Dis*. 2024;28(3):295-299. doi:10.1097/LGT.0000000000000820
59. Bleeker MCG, Visser PJ, Overbeek LIH, van Beurden M, Berkhof J. Lichen Sclerosis: Incidence and Risk of Vulvar Squamous Cell Carcinoma. *Cancer Epidemiol Biomark Prev Publ Am Assoc Cancer Res Cosponsored Am Soc Prev Oncol*. 2016;25(8):1224-1230. doi:10.1158/1055-9965.EPI-16-0019
60. Halonen P, Jakobsson M, Heikinheimo O, Riska A, Gissler M, Pukkala E. Lichen sclerosis and risk of cancer. *Int J Cancer*. 2017;140(9):1998-2002. doi:10.1002/ijc.30621
61. Morrel B, Van Der Avoort IAM, Ewing-Graham PC, et al. Long-term consequences of juvenile vulvar lichen sclerosis: A cohort study of adults with a histologically confirmed diagnosis in childhood or adolescence. *Acta Obstet Gynecol Scand*. 2023;102(11):1469-1478. doi:10.1111/aogs.14668
62. Morrel B, Kampherbeek JHJ, Ten Kate-Booij MJ, et al. Growing up with juvenile vulvar lichen sclerosis, the experiences and care needs of adult women with lichen sclerosis since childhood: a qualitative exploration. *Br J Dermatol*. Published online May 21, 2024;ljae203. doi:10.1093/bjd/ljae203

# Lichen sclerosis in pregnancy, postpartum, and breastfeeding

(alphabetical order)

*Tania Day, Melissa Mauskar, Amanda Selk*

**L**ichen sclerosis (LS) may occur at any age and be diagnosed during pregnancy and postpartum. Increased contact with healthcare providers provides an opportunity for diagnosis and optimization of genital skin health before birth. Alterations in hormonal status and irritant exposures throughout the puerperium may exacerbate vulvar symptoms and produce flares in LS activity.

## Lichen sclerosis during pregnancy and birth

### Disease course during pregnancy

There are conflicting reports about the course of LS in pregnancy. A systematic review of 7 studies found 12/85 women (14%) reported improvement, 65/85 (76%) were unchanged, and 7/85 (8%) felt their symptoms worsened.<sup>1</sup> An Australian study of 29 patients with 33 pregnancies found the amount of topical corticosteroid required for LS control remained stable pre-pregnancy, during pregnancy, and postpartum.<sup>2</sup> Among 22 British LS patients with 36 pregnancies managed with clobetasol propionate 0.05% ointment, all had stable disease during pregnancy.<sup>3</sup>

An online survey study of 134 LS patients with 206 previous pregnancies likely reflects the experiences of women without access to vulvar specialists.<sup>4</sup> Symptom reduction occurred during 44% of pregnancies, with more improvement in the second and third trimesters compared to the first. The rate of topical corticosteroid use pre-pregnancy in this community sample was 69/115 (60%), dropping to 35% during pregnancy. Women reported a range of medical advice discouraging corticosteroid treatment, with 19/115 (17%) being told to stop, 10 (9%) advised to decrease, and 5 (4%) told to change the steroid type. It is unclear how negative messages from midwives or nurses, pharmacists, package inserts, social networks, and the internet contributed to treatment avoidance.

### Reassurance about topical corticosteroids during pregnancy

There is overwhelming evidence supporting the use of topical corticosteroids in LS management, with safety demonstrated by studies of patients with widespread dermatoses requiring larger doses than what is used for LS.<sup>5</sup> Anecdotally, some patients stop medications in

pregnancy due to fear. However, there is no association between maternal exposure to topical steroids and untoward outcomes pertaining to mode of delivery, congenital abnormalities, preterm birth, low Apgar scores, or fetal death.<sup>5</sup> While there is a possible association between large cumulative topical corticosteroid use in pregnancy and low birth weight, this finding is inapplicable to the lower doses typically used for maintenance therapy of vulvar LS.<sup>5</sup> Clinicians should actively reassure reproductive-age and pregnant women with LS that consistent topical corticosteroid use is safe for them and their babies.

## Mode of birth

Mode of birth need not be impacted by a diagnosis of LS when the disease is well controlled with topical steroids (see Chapter 6). Patients report anxiety about their suitability for vaginal birth, but cases in which cesarean was required due to LS are isolated.<sup>2,4,6</sup> Spontaneous vaginal birth occurred in 82% of the Australian cohort, 2/33 (6%) had instrumental vaginal birth for standard obstetric indications, and there were 4/33 (12%) cesarean births. The indication for one cesarean was severe LS-related architectural change in a woman who did not adhere to steroid treatment.<sup>2</sup>

The outcomes of 36 pregnancies in the British cohort were spontaneous vaginal birth in 26 (79%), instrumental birth in 4 (11%), and cesarean for standard obstetric indications in 3 (8%). Episiotomy occurred in 9/30 (30%) vaginal births, an additional 7 women (23%) had first or second degree tears, and the single third degree laceration (3%) was sustained by a primiparous patient who had not yet initiated topical steroids.<sup>3</sup> These rates of perineal trauma are equivalent to the general British population.

The community-based survey cohort had a spontaneous vaginal birth rate of 59%, while 8% had an instrumental vaginal birth, 23% had a planned cesarean birth, and 11% had an unplanned cesarean birth. This distribution resembles the general population in North America, from which the study population was primarily derived. Nine (4%) women requested cesarean due to LS and 7 (3%) reported a medical provider advised surgery due to LS.<sup>4</sup> The reported rate of obstetric anal sphincter injury was 16/137 vaginal births (12%), which is twice the general population rate. Perineal massage was discussed antenatally in 31% and performed in 21% of the patients. Poorer birth outcomes in this study may be attributable to inadequate LS control, arising from obstetric care providers' inexperience with LS and widespread steroid phobia among clinicians and patients.<sup>7,8</sup>

During pregnancy, women ideally attend parallel visits with their vulvar and maternity care providers to maximize skin health in preparation for birth and plan for their post-birth steroid regimen and surveillance. There is evidence to support antenatal perineal massage during the third trimester and active perineal support during birth to prevent severe obstetric laceration.<sup>9</sup> One approach to prevention of postpartum LS exacerbation involves doubling the steroid potency and/or frequency on the first day after birth, continuing that for two weeks, then gradually reducing to pre-pregnancy maintenance levels over 6 to 12 weeks.<sup>10</sup>

Based on the limited available data, women with well controlled LS are suitable for the same antenatal care pathway, birth location, and birth attendants as women without LS. Women with poorly controlled LS identified during labor likely benefit from intrapartum medical

review, risk stratification around instrumental birth and episiotomy, an experienced clinician undertaking laceration repair, and counseling regarding postpartum management.

## Lichen sclerosus in the postpartum period

### Outcomes in women managed by LS experts

The cohort of 29 Australian women reported an increase in topical steroid compliance rates from 69% pre-pregnancy to 76% during pregnancy, followed by a decline postpartum to 60% with associated worsening of disease control.<sup>2</sup> In the British cohort of 36 pregnancies in 22 LS patients, one patient reported a postpartum flare of symptoms that improved following increased use of steroid.<sup>3</sup> The theoretical risk of koebnerization of LS in perineal lacerations was not demonstrated in either of these studies, with only one case of LS emerging in the perineal laceration across all 51 patients.<sup>2,3</sup>

### Community-based patient-reported experiences

Postpartum symptom exacerbation including itch, burning, discomfort, tearing, and changes to skin texture was reported in 60% of pregnancies, while the rate of corticosteroid treatment use was 65%.<sup>4</sup> Postpartum disease flare may reflect the natural history of LS exposed to a combination of skin injury during birth, lochia, sanitary products, decreased self-care, hormonal alterations, and/or urinary incontinence. Exacerbation may also result from patient- or provider-driven steroid avoidance during this vulnerable time for vulvovaginal health.<sup>4</sup> There was a 30% incidence of postpartum depression in this cohort, over twice the reported international rate. The authors link postpartum mental health concerns with worry around LS in pregnancy in the face of inadequate or erroneous information from healthcare providers.<sup>4</sup>

### Vulvovaginal comorbidities in the puerperium

Vulvovaginal symptoms occur in half of postpartum women and up to 60% report dyspareunia.<sup>11,12</sup> Contributors to these symptoms include hypoestrogenism, obstetric trauma, pelvic floor dysfunction, contact dermatitis, underlying skin conditions, and psychosocial stressors.<sup>13</sup> Diagnosis and management are challenging due to the multifactorial and inter-related nature of postpartum vulvovaginal conditions and patient attention being shifted to the newborn. Hypoestrogenism may increase the risk of contact dermatitis provoked by pads, blood, hygiene products, and incontinence. Discomfort from obstetric trauma may be exacerbated by fissures arising from atrophy, dermatitis, and pelvic floor hypertonicity, and yielding a vicious cycle of escalating sexual pain.<sup>12</sup>

When postpartum women report vulvovaginal symptoms but their LS is well controlled, clinicians must evaluate for other explanations (see Chapter 9).<sup>13</sup> Pertinent history includes pre-pregnancy dermatologic and pain conditions, specifics of the birth experience, breastfeeding and contraception status, bleeding pattern, exposure to vulvar irritants, partner and family supports, and current mental health. Vulvar examination may reveal wound concerns including breakdown, granulation tissue, poor approximation of edges, and non-anatomical repairs. Cutaneous candidiasis is less common in states of estrogen deficiency but may occur in settings of obesity, diabetes, immunosuppression, and skin occlusion.<sup>14</sup> Signs of



hypoestrogenism appear at the vestibule as thinned, smooth, red to pale shiny epithelium. The distal vagina may show reduced color and rugation. Pain at the base of the hymen with gentle pressure from a cotton swab or fingertip suggests allodynia. Alterations in vaginal discharge may be seen at the vestibule and distal vagina or with wet mount inspection of an introduced swab. Speculum examination is often uncomfortable for postpartum women and may not contribute to diagnostic efforts; clinicians should use discretion regarding risks and benefits of this examination component. Internal musculoskeletal assessment provides information about tenderness attributable to pelvic floor dysfunction. Vaginal examination also permits assessment of uterine or adnexal tenderness and cervicouterine involution. Depending on findings, testing for chlamydia, gonorrhea, trichomonas, *Streptococcus pyogenes*, and *Candida albicans* may be useful.<sup>13</sup>

## Lichen sclerosus during breastfeeding and estrogen supplementation

There is scant research on the relationship between breastfeeding and LS. The online survey cohort had a breastfeeding rate of 93% for a mean of 12 months. Seven (6%) patients were told to stop corticosteroid treatment and 94% described insufficient information from maternity care providers specific to LS and breastfeeding.<sup>4</sup>

The duration and severity of postpartum estrogen deprivation depends on duration and frequency of breastfeeding, underlying ovulatory function, and use of hormonal contraception. When assessed by gynecologic examination and  $\text{pH} > 5$ , 48% of 117 women showed signs of vulvovaginal atrophy at a median of 6 weeks post-birth.<sup>12</sup> In this cohort, the rate of complete or partial breastfeeding was 84% and dyspareunia was 70%. Sexual pain occurred in 80% of breastfeeding and 50% of bottle-feeding patients; while statistically insignificant, the study was underpowered to assess the relationship between dyspareunia and feeding mechanism.<sup>12</sup>

Treatment options for postpartum dyspareunia include lubricants, vaginal moisturizers, pelvic floor physiotherapy, and topical estrogen. Current formulations are equivalent to 10mcg of estradiol per dose. Despite displaying the same symptoms and signs as genitourinary syndrome of menopause (GSM), treatment of lactational hypoestrogenism is not routinely offered to postpartum women.<sup>12</sup> This may relate to medical inattention to women's sexual function and quality of life in combination with historic concerns about serum absorption of estrogen decreasing breast milk quantity.

The minimal impact of low-dose vaginal estrogen on bloodstream estrogen levels has primarily been evaluated in postmenopausal women. Untreated postmenopausal women show estradiol levels of 1.3 to 4.9pg/mL, with a maximum expected level of 10.7pg/mL.<sup>15</sup> Women treated with 25mcg of vaginal estradiol as a gel or tablet show a mean increase of 4pg/mL, with mean levels ranging from 7.4 to 22.7pg/mL.<sup>15</sup> Mean serum levels are lower with tablet versus gel formulations and at dosing of 10mcg of estradiol.<sup>15</sup> Estriol shows weaker estrogenic activity than estradiol, is the main estrogen present during pregnancy, and is undetectable in serum during postmenopause.<sup>16,17</sup> After vaginal application of 0.5 mg estriol, peak levels vary between individuals but reduce to baseline within 24 hours.<sup>17</sup> Placement of estrogen products in the lower third of the vagina likely decreases estrogen

absorption, and serum levels may decline further once the vagina is well estrogenized.<sup>15</sup>

A single-center, randomized, placebo-controlled pilot study evaluated the effect of vaginal estrogen therapy in 59 primiparas with second-degree or greater perineal laceration for 3 months postpartum. Participants inserted 1g estradiol 0.01% cream intravaginally twice weekly.<sup>18</sup> Unfortunately, study enrollment was discontinued early due to the COVID-19 pandemic. Patients using estradiol had a 50% improvement in Vulvar Assessment Scale scores and expressed higher satisfaction compared to controls. There were no significant differences in measures of vaginal health and sexual function.<sup>18</sup> Several additional lines of scientific enquiry support the safety of postpartum estrogen in higher doses than encountered in products marketed for GSM. A randomized trial of combined versus progesterone-only oral contraception initiated at 2 weeks postpartum did not show a difference in breastfeeding continuation rates or infant growth parameters.<sup>19</sup> After provision of transdermal estradiol doses as high as 100mcg/24 hours, there was no detectable estradiol in breast milk or reduced lactational ability.<sup>20</sup>

The available data indicates that low-dose vaginal estrogen applied to the vestibule and vagina is safe and may improve postpartum vulvovaginal symptoms and examination findings.<sup>12</sup> Extrapolating from care of LS during postmenopause, adding topical estrogen to topical corticosteroids may benefit patients in whom hypoestrogenism likely contributes to irritative and sexual symptoms.

## Limitations of the literature

The publications on LS and pregnancy are limited to small retrospective cohorts, case reports and case series, and an online survey study. This leaves major gaps in understanding the behavior of LS during pregnancy and the puerperium, optimal postpartum management regimens, and long-term pelvic health outcomes stratified by LS control and mode of birth.

## Conclusions and recommendations

Effective treatment of LS during pregnancy with topical corticosteroids appears to improve women's experiences and birth outcomes. Clinicians should provide reassurance regarding the safety of topical corticosteroids throughout pregnancy and breastfeeding, advice around perineal massage, and mode of birth being dictated by standard obstetric indications. Postpartum exacerbation of LS is common and may require increased potency or frequency of topical steroids and increased surveillance to ensure adequate disease control and exclude other contributing conditions.

- Obstetric lacerations do not appear to be more common or complex in LS patients who are adequately treated with topical steroids.
- Koebnerization of LS in obstetric scars is rare when disease is well controlled.
- Providers caring for preconceptional and pregnant women with LS should provide reassurance regarding topical steroids, encourage adherence to treatment regimens regardless of pregnancy or breastfeeding status, counsel regarding the postpartum potential for flare, hypoestrogenism, and sexual pain, and offer short-interval follow-up post-birth to proactively address concerns.

- Topical vulvovaginal estrogen may be a helpful adjunctive therapy during lactational amenorrhea.
- Vulvar clinicians play an important role in supporting pregnant women and maternity care providers to continue effective LS treatment and to individually tailor postpartum management plans.

## References

1. Debaene B, Vandeweege S, Verstraelen H. Vulvar lichen sclerosus in pregnancy: Unaddressed needs and systematic review. *Skin Health Dis.* 2023;3(5):e281. doi:10.1002/ski2.281
2. Nguyen Y, Bradford J, Fischer G. Lichen sclerosus in pregnancy: A review of 33 cases. *Aust N Z J Obstet Gynaecol.* 2018;58(6):686-689. doi:10.1111/ajo.12812
3. Trokoudes D, Lewis FM. Lichen sclerosus - the course during pregnancy and effect on delivery. *J Eur Acad Dermatol Venereol JEADV.* 2019;33(12):e466-e468. doi:10.1111/jdv.15788
4. Shaffer AB, Cigna ST, Pope R, Krapf JM. Pregnancy, parturition and postpartum considerations among patients with vulvar lichen sclerosus: A retrospective cross-sectional online survey. *BJOG Int J Obstet Gynaecol.* 2024;131(3):327-333. doi:10.1111/1471-0528.17601
5. Chi CC, Wang SH, Wojnarowska F, Kirtschig G, Davies E, Bennett C. Safety of topical corticosteroids in pregnancy. *Cochrane Database Syst Rev.* 2015;2015(10):CD007346. doi:10.1002/14651858.CD007346.pub3
6. Helm KF, Gibson LE, Muller SA. Lichen sclerosus et atrophicus in children and young adults. *Pediatr Dermatol.* 1991;8(2):97-101. doi:10.1111/j.1525-1470.1991.tb00294.x
7. Delpero E, Sriharan A, Selk A. Steroid Phobia in Patients With Vulvar Lichen Sclerosus. *J Low Genit Tract Dis.* 2023;27(3):286-290. doi:10.1097/LGT.0000000000000753
8. Nic Dhonncha E, O'Connor C, O'Connell G, Quinlan C, Roche L, Murphy M. Adherence to treatment with prescribed topical corticosteroid therapy and potential barriers to adherence among women with vulvar lichen sclerosus: a prospective cross-sectional study. *Clin Exp Dermatol.* 2021;46(4):734-735. doi:10.1111/ced.14527
9. Okeahialam NA, Sultan AH, Thakar R. The prevention of perineal trauma during vaginal birth. *Am J Obstet Gynecol.* 2024;230(3S):S991-S1004. doi:10.1016/j.ajog.2022.06.021
10. Bradford J, Fischer G. Surgical division of labial adhesions in vulvar lichen sclerosus and lichen planus. *J Low Genit Tract Dis.* 2013;17(1):48-50. doi:10.1097/LGT.0b013e31824f1427
11. Rosen NO, Pukall C. Comparing the Prevalence, Risk Factors, and Repercussions of Postpartum Genito-Pelvic Pain and Dyspareunia. *Sex Med Rev.* 2016;4(2):126-135. doi:10.1016/j.sxmr.2015.12.003
12. Lev-Sagie A, Amsalem H, Gutman Y, Esh-Broder E, Daum H. Prevalence and Characteristics of Postpartum Vulvovaginal Atrophy and Lack of Association With Postpartum Dyspareunia. *J Low Genit Tract Dis.* 2020;24(4):411-416. doi:10.1097/LGT.0000000000000548
13. Ram-Weiner M, Hayman-Mendelson A, Allouche-Kam H, Lev-Sagie A. Postpartum dyspareunia: clinical evaluation, causes, and treatment outcomes. *J Sex Med.* 2023;20(3):324-331. doi:10.1093/jsxmed/qdac040
14. Day T, Chapman-Burgess E, Scurry J. Clinicopathologic Overlap of Vulvar Psoriasis and Candidiasis. *J Low Genit Tract Dis.* 2024;28(2):175-182. doi:10.1097/LGT.0000000000000801
15. Santen RJ, Mirkin S, Bernick B, Constantine GD. Systemic estradiol levels with low-dose vaginal estrogens. *Menopause N Y N.* 2020;27(3):361-370. doi:10.1097/GME.0000000000001463
16. Ali ES, Mangold C, Peiris AN. Estriol: emerging clinical benefits. *Menopause N Y N.* 2017;24(9):1081-1085. doi:10.1097/GME.0000000000000855
17. Te West N, Day R, Graham G, et al. Serum concentrations of estriol vary widely after application of vaginal oestriol cream. *Br J Clin Pharmacol.* 2021;87(5):2354-2360. doi:10.1111/bcp.14635
18. Smith PE, McLaughlin EM, Pandya LK, Hade EM, Lynch CD, Hudson CO. A pilot randomized controlled trial of vaginal estrogen on postpartum atrophy, perineal pain, and sexual function. *Int Urogynecology J.* 2022;33(12):3383-3390. doi:10.1007/s00192-022-05149-x
19. Espy E, Ogburn T, Leeman L, Singh R, Ostrom K, Schrader R. Effect of progestin compared with combined oral contraceptive pills on lactation: a randomized controlled trial. *Obstet Gynecol.* 2012;119(1):5-13. doi:10.1097/AOG.0b013e31823dc015
20. Perheentupa A, Ruokonen A, Tapanainen JS. Transdermal estradiol treatment suppresses serum gonadotropins during lactation without transfer into breast milk. *Fertil Steril.* 2004;82(4):903-907. doi:10.1016/j.fertnstert.2004.02.141

# Lichen sclerosus and advancing age

*Dolly Taiwò, Emily Delpero, Natalie Saunders, Miriam Keltz Pomeranz*

Over the lifespan, women experience changes in lichen sclerosus (LS)-related symptoms, signs, and quality of life (QoL) impacts. In parallel, there are alterations in urogenital structure and function relating to menopause, weight gain, incontinence, prolapse, and medical comorbidities. Conditions associated with the aging process may exacerbate LS, impede treatment, and challenge the clinician to address a range of non-modifiable disease triggers. In settings of profound dementia or life-limiting illness, the management of LS may transition to a comfort care model in discussion with caregivers and health care proxies.

## Menopause and lichen sclerosus

### Distinguishing between genitourinary syndrome of menopause and LS

The experience of peri- and postmenopause varies greatly across individuals. Menopause is defined retrospectively as 1 year after the final menses. For several years prior to menopause, women may experience irregular menses, hot flashes, night sweats, sleep disruption, brain fog, reduced libido, diminished sexual function, urinary difficulties, and vulvovaginal symptoms. Genitourinary syndrome of menopause (GSM) encompasses urinary and vulvovaginal changes arising from hypoestrogenism. Common GSM symptoms include vulvar irritation, sensation of dryness, altered quantity and consistency of vaginal discharge, urinary urgency, dysuria, recurrent urinary tract infections (UTI), and changes to urine stream initiation, flow, and cessation. Sexual difficulties involve diminished lubrication, perception of friction, skin fragility, fissures, post-coital bleeding, and reduced desire, arousal, and/or orgasm. Many of these symptoms are also reported by women with LS. Itch is more characteristic of LS and dryness of GSM, but both conditions may be asymptomatic.<sup>1,2</sup>

Examination and microscopy findings consistent with persistent hypoestrogenism include diminished vaginal rugae, reduced discharge, elevated vaginal pH, parabasal cells, colonization by enteric flora, urethral caruncle, smooth pale vulvar skin, thinned vestibular and vaginal epithelium, diminished tissue elasticity, and decreased subcutaneous fat.<sup>2,3</sup> The paleness of GSM is symmetric with indistinct borders and affects the hairless skin, vestibule, and vagina. In contrast, LS often shows a more porcelain white color often affecting the interlabial folds, labia majora, perineum, and perianus, areas spanning hairless and hair bearing skin. In both LS and GSM, less resilient thinned epithelium predisposes to fissures, erosions, or

petechiae from touch, wiping, sex, or examination. However, LS may show more dramatic manifestations of skin trauma like ecchymoses with a range of abnormal skin textures, from thinned and crinkled to thickened with a rough surface.

There is some overlap in architectural changes attributable to hypoestrogenism versus LS.<sup>2</sup> Careful inspection informed by clinical experience aids in distinguishing between the two conditions. Both GSM and LS may display diminution of the labia minora and periclitoral structures, and/or mild synechiae between the clitoral hood and glans. However, a flattened and non-retractable clitoral hood does not typically arise from isolated hypoestrogenism and instead provokes concern for LS or erosive lichen planus (LP).<sup>4,5</sup> Reduced introital dimensions may occur in both, but only lichenoid disorders cause midline fusion of labia minora or a tight sclerotic band at posterior fourchette. A short course of topical estrogen improves symptoms and signs of GSM but will not modify the appearance of LS.<sup>5</sup>

There is no minimum set of signs and symptoms required for a diagnosis of GSM and its reported prevalence varies from 27-84% of postmenopausal women.<sup>6</sup> The vague definition provides an opportunity for LS and other vulvovaginal conditions to be misdiagnosed as GSM.<sup>2</sup> Clinicians must recognize GSM as a diagnosis of exclusion and undertake careful history, examination, and pertinent investigations to identify infectious, inflammatory, or neoplastic entities.<sup>7</sup>

## Systemic menopause hormone therapy with LS

The goals of menopause management are to address symptoms, improve QoL, minimize side effects, and reduce the risk of treatment-related harms. This requires an individualized approach with awareness of ease-of-use, accessibility, and cost of locally available products. Systemic menopause hormone therapy (MHT) addresses vasomotor-related symptoms like hot flashes, night sweats, insomnia, and brain fog. An additional indication is prevention of osteoporosis in postmenopausal women with increased risk of future fracture.<sup>8,9</sup> The common guidance for MHT use is the lowest effective dose for the shortest necessary timeframe. However, the QoL and sexual impacts of estrogen deficiency may persist throughout menopause. Clinicians considering dose reduction or cessation should ensure they are not adhering to an arbitrary perceived maximum duration, inflating potential risks of continued use, or discounting women's experiences of benefit.<sup>9-11</sup> Menopause management and systemic MHT prescribing are complex topics, so this section provides only a brief overview.

## There are several categories of systemic MHT<sup>11</sup>

### Estrogen therapy

Unopposed estrogen is appropriate for women without a uterus. Estrogen may be delivered by tablet, transdermal patch, gel, lotion, ring, and subcutaneous implant. 17- $\beta$  estradiol is structurally identical to estrogen secreted by the ovary. Oral estrogens undergo first-pass hepatic metabolism, resulting in increased thyroid binding globulin and sex hormone binding globulin.<sup>8,9</sup> Thyroid medication dose may require adjustment. Oral estrogens are less suitable for patients with thrombophilia, migraine headache with aura, active gallbladder disease, and hypertriglyceridemia. Transdermal preparations avoid impacts on hepatic proteins and lipid profiles and minimally alter the risk of venous thromboembolism.<sup>9</sup> However,

women may report reactions to adhesives or issues with application and consistent absorption. Any form of exogenous estrogen serves as an additional risk factor for vulvovaginal candidiasis in patients already on topical steroids for LS.<sup>12,13</sup> Beyond these considerations, choice of route depends on patient preference, product availability, cost, and clinician familiarity.

## Estrogen/progestogen therapy

Progesterone provides endometrial protection for patients with a uterus who require estrogen therapy. Oral micronized progesterone may improve sleep outcomes, but otherwise progestogens have no recognized health benefit for menopausal women.<sup>14</sup> A variety of synthetic progestogens may be delivered by tablet, transdermal patch, vaginal pessaries, and levonorgestrel-containing intrauterine device. Micronized progesterone is available in capsules and identical to that secreted by the ovary during the luteal phase. Vaginal micronized progesterone is not a standard approach to combined MHT due to insufficient long-term studies documenting the quantity and frequency required for endometrial protection.<sup>15</sup>

Progesterone administration may be cyclic or continuous. The frequency of cyclic regimens depends on the estrogen dose with standard dosing requiring 12 days per month and very-low estrogen dosing requiring two to four 12-day courses of progesterone annually. The concerns around progestogens and breast cancer risk identified by the Women's Health Initiative study center on daily oral medroxyprogesterone.<sup>16</sup> There is no significant change to breast cancer risk in women using micronized progesterone or dydrogesterone for less than 5 years.<sup>17</sup>

## Tissue-selective estrogen complex

The combination of conjugated estrogens with bazedoxifene yields a tissue-selective estrogen complex administered with a once daily tablet. Bazedoxifene is a selective estrogen receptor modulator (SERM) with profound inhibitory effect on the endometrium. Although long-term safety data is not yet available, the product does not appear to stimulate breast tissue or increase cardiovascular risks. The fixed-dose regimen precludes adjustment if symptoms persist during treatment.<sup>9</sup>

## Tibolone

Tibolone is a synthetic steroid with estrogenic, progestogenic, and androgenic activity via its metabolites. It improves bone health, sexual function, and vasomotor symptoms, although estrogen is more effective for the latter. In women with a uterus, treatment may begin 12 months after final menses. In those with previous hysterectomy, it may be administered when menopausal symptoms begin.<sup>9</sup> Tibolone does not stimulate the endometrium, does not require concomitant progesterone, and should not be prescribed with estrogen. Safety concerns include an increased risk of recurrent breast cancer and stroke in women over 60.<sup>18,19</sup>

## Local therapy of GSM in patients with LS

Up to 40% of patients on systemic MHT require local therapy to address GSM and the two approaches may be used in combination.<sup>20</sup> Menopausal patients with LS who report irrita-

tive and sexual symptoms despite objective control with topical steroids may benefit from hormonal treatment. Topical estrogen thickens the vaginal epithelium, reduces vaginal pH, increases local secretions, diminishes the density of autonomic and sensory innervation, improves incontinence, and reduces the incidence of UTI.<sup>21</sup> It requires chronic use for ongoing effect. Some genitourinary repercussions of estrogen deficiency are progressive and irreversible, but may be prevented by early initiation and long-term continuation of individualized multimodal therapy that includes topical hormonal medication.<sup>22,23</sup> Vulvovaginal emollients and pelvic floor physiotherapy also may benefit women with GSM (see Chapters 7 and 8).

Topical estrogen is safe for almost all women. Contraindications to use are unexplained vaginal bleeding and sensitivity to the product. Current low-dose estrogen products and prasterone do not change serum estrogen levels over time nor increase cardiovascular risks.<sup>11,24</sup> Local estrogen therapy does not require endometrial protection or ultrasound monitoring. Current evidence supports the safety of topical estrogen in survivors of hormonally-mediated cancer.<sup>25,26</sup> There are multiple options for local hormonal therapy of GSM, with selection guided by availability, cost, and patient preference.<sup>7</sup> It is unknown if any product is more effective or better tolerated in women with LS. While it is postulated that estrogenized skin responds better to topical steroid management of genital dermatoses, studies have not been done to evaluate this hypothesis.

## Estrogens

There are several topical estrogen products with different compounds, delivery mechanisms, and dosing schedules. Available products vary over time and across countries, with new formulations periodically introduced and others retired. There is no substantial difference in efficacy between different agents but effects are dose-dependent.<sup>18</sup> 17- $\beta$  estradiol is formulated as a 0.01mg vaginal tablet or soft gel insert, 0.01% cream, and 2mg slow-release ring placed every 3 months.<sup>9</sup> The tablet is placed nightly for 2 weeks then 2-3 times per week. Cream is applied at 2-4g daily for 1-2 weeks then 1g once to twice weekly. Estriol is formulated as a 0.1% cream with 0.5g delivered per applicator, or 0.5mg insert to use nightly for 2-3 weeks then twice weekly.<sup>9</sup> Conjugated estrogen is delivered as a 0.625mg/g cream. It may be administered in a cyclic 21 days on and 7 days off pattern or twice weekly.

## Prasterone

Prasterone is synthetic dehydroepiandrosterone, a precursor hormone made by the adrenal glands. It is administered as a 6.5mg vaginal insert for nightly use. The mechanism of action at the vagina is unclear and may involve tissue conversion to estrogens and androgens.<sup>27</sup> The most frequently reported side effect is vaginal discharge. There are no restrictions on duration of use with the only contraindicated being undiagnosed persistent genital bleeding. There is no change to serum estradiol levels with prasterone administration at 12, 26, or 52 weeks of use.<sup>27</sup>

## Ospemifene

Ospemifene is an oral SERM with an estrogen-like effect at the vagina that improves GSM-related dyspareunia. The dosing is 60mg daily. It provokes vasomotor symptoms in 10% of users.<sup>9</sup>



## Testosterone

Testosterone is not a standard component of local or systemic MHT. Its current indication is management of hypoactive sexual desire disorder and is dosed topically at 1/10<sup>th</sup> the male dose.<sup>28</sup> Testosterone use in women requires monitoring to maintain serum concentrations in the physiologic premenopausal range.

## The role of fractional laser in GSM

The promotion and dissemination into practice of fractional laser devices for treatment of GSM occurred before high quality evidence was available to support their use. Multiple authors across many countries published nonrandomized studies with short-term follow-up and described fractional laser as promising, effective, and/or beneficial with scant risk.<sup>29</sup> Over the past 5 years, several well-designed sham-controlled studies have documented no difference between groups and a substantial placebo-response rate.<sup>30–32</sup> Immediate side effects attributable to fractional laser include pain and burning. Case series document post-laser complications of persistent pain and dyspareunia, vaginal agglutination and fibrosis, change in vaginal caliber, and coital lacerations.<sup>10,29,33</sup> Given the rare but serious risks, lack of benefit, and potential to complicate LS and LP, fractional laser devices should not be used in routine clinical practice for patients with genitourinary complaints (see Chapter 10).<sup>34,35</sup>

## Impact of incontinence and pelvic organ prolapse on lichen sclerosis

### Urinary incontinence

The incidence of urinary incontinence (UI) increases with age and is often undertreated due to non-presentation of affected patients, inadequate access to care, unsuitability of treatments, and persistence despite attempts at management.<sup>36,37</sup> The prevalence of UI is reported as 3% in women under 35, rising to 38–70% in women over 60, and 43–77% in nursing home residents.<sup>38,39</sup> Risk factors include advancing age, family history, obesity, tobacco use, parity, vaginal birth, chronic straining, collagen tissue disorders, and pelvic floor denervation.<sup>40–44</sup> Treatment for urge UI includes reducing dietary triggers, tobacco cessation, bladder training, topical estrogen, medications that relax the detrusor muscle, and intravesical botox injections. Non-surgical management of stress urinary incontinence (SUI) includes weight loss, reduction of cough and valsalva, topical estrogen, pelvic floor strengthening, and pessaries.<sup>45–48</sup> Addressing chronic constipation may aid in UI management. Surgical approaches to SUI include tension-free vaginal slings, laparoscopic colposuspension, and urethral bulking agents.

Chronic exposure to urine is proposed as a factor in development of male LS.<sup>49</sup> In women, the role of UI in initiation or exacerbation of LS is unclear. Some epidemiologic studies suggest an association, but this may reflect the role of confounders like age and obesity.<sup>50</sup> Selection and information bias likely contribute to associative findings, as women diagnosed with LS may be more often asked about UI by their care providers, or feel more comfortable disclosing it, than women attending other types of medical appointments.

Incontinence-associated dermatitis (IAD) is a common form of irritant contact dermatitis

resulting from chronic skin exposure to moisture, alkalinity resulting from ammonia, and friction through contact with absorption products. Alkalinity damages the skin barrier function through decreased stratum corneum cohesion, increases pathogens in the local microbiome, and activates fecal proteases and lipases that further damage the epidermis.<sup>51,52</sup> These alterations, in concert with moisture-related susceptibility to shear stress, make the skin vulnerable to laceration, erosion, and ulceration. Exposure to irritants and trauma results in cytokine release, inflammatory cell infiltration, and vasodilation, seen clinically as an erythematous rash. In milder cases, this may occur over labia majora at the site of maximal skin contact with pads.<sup>1,53</sup> In severe cases with long-term occlusion from diapers, the rash may be extensive and accompanied by edema and bullae.<sup>51</sup> Affected skin is susceptible to secondary bacterial or fungal infection. In patients with LS, IAD is a reason for non-response to topical steroids but may be difficult to distinguish from steroid overuse and cutaneous candidiasis. Constant moisture and frequent washing may also diminish topical steroid durability, necessitating an increase in frequency or potency to maintain the same effect on LS.

Management of IAD is multimodal and begins with attempts to reduce the incontinence burden through multimodal treatment based on UI etiology. Care is required with introducing topical products as elderly patients have increased susceptibility to allergens like lanolin, bacitracin, neomycin, cetrimide, and propylene glycol that may be components of products marketed for rashes.<sup>52</sup> Regular gentle skin cleaning with a pH-neutral soap substitute or bath oil is important for comfort and hygiene, but excessive cleaning may worsen skin integrity and barrier function.<sup>52</sup> Achieve drying with patting, not rubbing. A simple emollient or barrier ointment is applied after cleansing (see Chapter 7). Evidence for topical steroids and antifungals in IAD is limited to care reports and series, with caution advised for steroids due to association with candidiasis. Ambulatory patients may be able to use absorbent 'period' underwear rather than pads. Frequent position changes and adequate nutrition help prevent pressure ulcers.

## Fecal incontinence

Fecal incontinence (FI) affects 20% of women over age 65 and is likely underreported.<sup>54</sup> Risk factors in addition to those for UI include bariatric surgery, chronic diarrhea, fecal impaction, hemorrhoids and previous hemorrhoidectomy, inflammatory bowel disease, fistula, and radiation.<sup>54</sup> There are two main etiologies of anal sphincter dysfunction - mechanical and neurologic. Rectal prolapse may accompany FI or occur independently and cause mucoid or bloody rectal discharge.<sup>55</sup> Initial treatment of FI includes dietary changes, fecal bulking agents, pelvic floor physiotherapy, and biofeedback. While adherence to these measures is difficult, 70-80% of patients who persist report improvement.<sup>54</sup> Medications include antitility agents, anticholinergics, and bile acid binders, but few studies guide use or report response rates. Surgery addresses previous sphincter injury and involves overlapping plication. Postoperative continence rates decline with time, with maximal success rates peaking at 80% and falling below 60% at 5 years.<sup>54</sup> Sacral and posterior nerve stimulation may decrease FI episodes in patients with both neurologic and structural etiologies of FI. Anal bulking agents are of unclear long-term utility with high placebo-response rates. The only cure for FI is colostomy, which has high satisfaction rates and produces dramatic improvements in QoL but represents a major surgery usually reserved for patients with severe, refractory disease.<sup>54</sup>

Fecal incontinence also causes IAD, often presenting with pain or itch and a red rash sometimes accompanied by skin breakdown and bleeding.<sup>56</sup> The usual location is perianal, but it may extend over the buttocks, natal cleft, thighs, and vulva. The goal of skin management is to reduce the duration of contact with feces through immediate non-soap cleansing after each episode, followed by barrier ointment. Most commercial wipes are inappropriate for perianal hygiene as they contact multiple allergens and irritants.<sup>57,58</sup> When there is no practical alternative, it is possible to obtain wipes containing only water with a single hypoallergenic preservative. There are no studies addressing FI in patients with LS, but anecdotally it is nearly impossible to normalize perianal skin color, texture, and function when these conditions are comorbid.

## Pelvic organ prolapse

Pelvic organ prolapse (POP) reflects diminished ligamentous and endopelvic fascial support of the bladder, anorectum, uterus, and vagina. Risk factors mirror those of UI. Patients may be asymptomatic or report a pressure or dragging sensation, incomplete emptying of bladder or bowels, sexual dysfunction, and the need to manually reduce the prolapse to void. The grade of POP is established in reference to the hymen, with procidentia referring to the entire uterus persisting outside the body. Vaginal epithelium often keratinizes when chronically prolapsed beyond the hymen, making it susceptible to development of LS.<sup>59,60</sup> Friction, moisture, and occlusion relating to contact between vulvar skin and prolapsed organs may exacerbate LS. Therapeutic strategies for POP include behavioral modifications, pelvic floor physiotherapy, pessaries, and surgery. Vaginal approaches to POP surgery may involve incisions over the posterior fourchette and perineum. Optimal pre- and postoperative LS control may reduce koebnerization, lessen discomfort during recovery, and mitigate the risk of fibrotic band formation at the incision site (see Chapter 12).

Pessary management improves QoL and may be as effective as surgery in maintaining intrapelvic location of organs. Complications occur in at least 20% of users, including increased or malodorous discharge, bleeding, vaginal erosions or ulcers, and de-novo UI.<sup>61,62</sup> These issues may provoke irritant contact dermatitis and worsen LS control. Pessary users may experience pain from an ill-fitting or dislodged device and potentially misattribute this discomfort to a LS flare. Vesicovaginal and rectovaginal fistulae rarely occur, usually arising from years of pessary neglect. One large series reported comorbid vulvar dermatosis in 3% of pessary users and did not impact pessary complication rates.<sup>61</sup> Vaginal estrogen is often recommended in conjunction with pessary use and is associated with device continuation, but it is unclear if it improves outcomes or reduces complications.<sup>61,63</sup> Familiarity with pessary complications aids vulvar providers in determining if LS symptom exacerbation is directly or indirectly due to pessary management of POP.

## Treatment considerations for lichen sclerosis with comorbidities of advancing age

There are multiple goals for treatment of LS, including reducing symptom burden, enhancing QoL, preserving anatomy, and reducing the risk of neoplasia (see Chapter 6). Adherence to topical treatment regimens is a challenge across ages in dermatologic conditions.<sup>64</sup> In older

patients, polypharmacy for numerous medical problems may produce a sense of treatment overload and difficulty in prioritizing LS care. Immunosenescence and diabetes contribute to the risk of candidal superinfection of LS, further exacerbated by SGLT-2 inhibitors.<sup>65,66</sup>

Older patients may have mobility and dexterity concerns that limit access to vulvar skin.<sup>67</sup> Obesity exacerbates the challenge of reaching the vulva with one's fingertips. Some patients adopt suboptimal strategies to apply treatment to vulvar skin, like rubbing steroid ointment on a pad. These practices may be detected through careful history and noting steroid dermatitis over areas unaffected by LS like mons, outer labia majora, and buttocks. Creative solutions to overcome access challenges include long-handled mirrors, large cotton tip applicators, medical dilators, and assistance from partners or caregivers.

Cognitive decline may interfere with regular steroid application or may manifest as resistance to examination and genital contact. Carers may be reluctant to touch the vulva to apply topical medications and may avoid lateral movement of labia majora and buttocks to place ointments on affected areas. Education, redirection, and reinforcement of vulvar care practices are elements of each patient encounter. Inclusion of family members and carers helps to overcome memory loss and encourages a team approach to supporting ongoing treatment of LS.<sup>68</sup>

Quiescence of LS in older women is possible but not common or predictable. Assessment for LS inactivity involves decreasing the potency and frequency of steroid while providing interval assessment of skin appearance. If the skin shows normal color and texture after several months on minimal or no topical corticosteroid, it is acceptable to cease therapy but continue longer-interval surveillance visits.

As medical and cognitive comorbidities arise, the risk-benefit ratio of LS treatment may shift. Vulvar examination and steroid application may cause distress in patients with advanced dementia. Patients with life-limiting illness and minimal LS-attributable symptoms may decide they no longer wish to prioritize previously desirable treatment goals like prevention of scarring and vulvar cancer. In these situations, clinicians should initiate frank discussions about burdens of treatment and surveillance versus the possibility of unmanaged LS leading to late diagnosis of cancer. As with other areas of medicine, transition to a comfort-care approach involves a discussion around the decision to refrain from biopsies or excisions of suspected neoplasia.

## Limitations of the literature

There is little evidence of guide management of LS in advancing age. The breadth of vulvovaginal comorbidities in older women with LS has not been explored. The impact of systemic and local hormonal therapy on LS symptoms and management is unknown. There are no studies on the effect of interventions for POP and UI on LS severity and topical steroid requirements. Publications on IAD do not address the complexities of comorbid LS and interplay between the two skin conditions. Likewise, the unique problems of LS management in the nursing home setting have not been investigated. The paucity of data speaks to socio-cultural neglect of the genital health, sexual function, and QoL of older women and presents a challenge to researchers to explore these questions.

## Conclusions and recommendations

Lichen sclerosus continues to pose significant QoL burdens to affected older women, regardless of sexual activity, cognitive ability, or concurrent medical problems. Many postmenopausal women with LS have vasomotor symptoms and/or GSM and may benefit from systemic and/or local hormonal therapy. Common comorbidities of advancing age, like obesity, mobility limitations, incontinence, and prolapse, complicate LS management. Management of incontinence-associated dermatitis superimposed on LS is challenging and requires a multidisciplinary approach, multimodal therapy, and a change in patient and provider expectations around skin appearance and outcomes. Cessation of treatment for LS due to dementia or life-limiting illness requires an open discussion of the patient experience of treatment and surveillance, logistical aspects of steroid application and visit attendance, and desires regarding potentially reversible causes of morbidity and mortality.

- Lichen sclerosus and other genital dermatoses may be misdiagnosed as GSM, but usually are distinguishable through careful history, examination, and sometimes histopathology.
- Treatment of vulvovaginal estrogen deficiency with topical estrogen is safe for nearly all postmenopausal women.
- Fractional laser ablation does not play a role in the management of estrogen deficiency concurrent with LS.
- Vulvar care providers are well placed to ask about menopause symptoms, incontinence, and prolapse, advise on initial behavioral measures, consider pharmaceutical options, and encourage engagement with continence clinics, physiotherapy, and medical specialists with expertise in the relevant condition.

## References

1. Lev-Sagie A. Vulvar and Vaginal Atrophy: Physiology, Clinical Presentation, and Treatment Considerations. *Clin Obstet Gynecol.* 2015;58(3):476-491. doi:10.1097/GRF.0000000000000126
2. Vieira-Baptista P, Marchitelli C, Haefner HK, Donders G, Pérez-López F. Deconstructing the genitourinary syndrome of menopause. *Int Urogynecology J.* 2017;28(5):675-679. doi:10.1007/s00192-017-3295-6
3. Angelou K, Grigoriadis T, Diakosavvas M, Zacharakis D, Athanasiou S. The Genitourinary Syndrome of Menopause: An Overview of the Recent Data. *Cureus.* Published online April 8, 2020. doi:10.7759/cureus.7586
4. Aerts L, Rubin RS, Randazzo M, Goldstein SW, Goldstein I. Retrospective Study of the Prevalence and Risk Factors of Clitoral Adhesions: Women's Health Providers Should Routinely Examine the Glans Clitoris. *Sex Med.* 2018;6(2):115-122. doi:10.1016/j.esxm.2018.01.003
5. Vyas A. Genital Lichen Sclerosus and its Mimics. *Obstet Gynecol Clin North Am.* 2017;44(3):389-406. doi:10.1016/j.ogc.2017.05.004
6. The 2020 genitourinary syndrome of menopause position statement of The North American Menopause Society. *Menopause.* 2020;27(9):976-992. doi:10.1097/GME.0000000000001609
7. Pérez-López FR, Phillips N, Vieira-Baptista P, Cohen-Sacher B, Fialho SCAV, Stockdale CK. Management of postmenopausal vulvovaginal atrophy: recommendations of the International Society for the Study of Vulvovaginal Disease. *Gynecol Endocrinol.* 2021;37(8):746-752. doi:10.1080/09513590.2021.1943346
8. Davis SR, Baber RJ. Treating menopause — MHT and beyond. *Nat Rev Endocrinol.* 2022;18(8):490-502. doi:10.1038/s41574-022-00685-4
9. Davis SR, Taylor S, Hemachandra C, et al. The 2023 Practitioner's Toolkit for Managing Menopause. *Climacteric.* 2023;26(6):517-536. doi:10.1080/13697137.2023.2258783
10. Kaunitz AM, Pinkerton JV, Manson JE. Women harmed by vaginal laser for treatment of GSM—the latest casualties of fear and confusion surrounding hormone therapy. *Menopause.* 2019;26(4):338-340. doi:10.1097/GME.0000000000001313

11. Crandall CJ, Mehta JM, Manson JE. Management of Menopausal Symptoms: A Review. *JAMA*. 2023;329(5):405-420. doi:10.1001/jama.2022.24140
12. Fischer G, Bradford J. Vulvovaginal Candidiasis in Postmenopausal Women: The Role of Hormone Replacement Therapy. *J Low Genit Tract Dis*. 2011;15(4):263-267. doi:10.1097/LGT.0b013e3182241f1a
13. Day T, Chapman-Burgess E, Scurry J. Clinicopathologic Overlap of Vulvar Psoriasis and Candidiasis. *J Low Genit Tract Dis*. 2024;28(2):175-182. doi:10.1097/LGT.0000000000000801
14. Nolan BJ, Liang B, Cheung AS. Efficacy of Micronized Progesterone for Sleep: A Systematic Review and Meta-analysis of Randomized Controlled Trial Data. *J Clin Endocrinol Metab*. 2021;106(4):e942-e951. doi:10.1210/clinem/dgaa873
15. Sriprasert I, Mert M, Mack WJ, Hodis HN, Shoupe D. Use of oral estradiol plus vaginal progesterone in healthy postmenopausal women. *Maturitas*. 2021;154:13-19. doi:10.1016/j.maturitas.2021.09.002
16. Chlebowski RT, Rohan TE, Manson JE, et al. Breast Cancer After Use of Estrogen Plus Progestin and Estrogen Alone: Analyses of Data From 2 Women's Health Initiative Randomized Clinical Trials. *JAMA Oncol*. 2015;1(3):296. doi:10.1001/jamaoncol.2015.0494
17. Stute P, Wildt L, Neulen J. The impact of micronized progesterone on breast cancer risk: a systematic review. *Climacteric*. 2018;21(2):111-122. doi:10.1080/13697137.2017.1421925
18. Lethaby A, Ayeleke RO, Roberts H. Local oestrogen for vaginal atrophy in postmenopausal women. *Cochrane Gynaecology and Fertility Group*, ed. *Cochrane Database Syst Rev*. 2016;2016(11). doi:10.1002/14651858.CD001500.pub3
19. Formoso G, Perrone E, Maltoni S, et al. Short and long term effects of tibolone in postmenopausal women. In: *The Cochrane Collaboration*, ed. *Cochrane Database of Systematic Reviews*. John Wiley & Sons, Ltd; 2012:CD008536.pub2. doi:10.1002/14651858.CD008536.pub2
20. Johnston S, Bouchard C, Fortier M, Wolfman W. Guideline No. 422b: Menopause and Genitourinary Health. *J Obstet Gynaecol Can*. 2021;43(11):1301-1307.e1. doi:10.1016/j.jogc.2021.09.001
21. Hirschberg AL, Bitzer J, Cano A, et al. Topical estrogens and non-hormonal preparations for postmenopausal vulvovaginal atrophy: An EMAS clinical guide. *Maturitas*. 2021;148:55-61. doi:10.1016/j.maturitas.2021.04.005
22. Nappi RE, Martini E, Cucinella L, et al. Addressing Vulvovaginal Atrophy (VVA)/Genitourinary Syndrome of Menopause (GSM) for Healthy Aging in Women. *Front Endocrinol*. 2019;10:561. doi:10.3389/fendo.2019.00561
23. Cucinella L, Tiranini L, Cassani C, et al. Insights into the vulvar component of the genitourinary syndrome of menopause (GSM). *Maturitas*. Published online April 2024:108006. doi:10.1016/j.maturitas.2024.108006
24. Phillips NA, Bachmann GA. The genitourinary syndrome of menopause. *Menopause*. 2021;28(5):579-588. doi:10.1097/GME.0000000000001728
25. McVicker L, Labeit AM, Coupland CAC, et al. Vaginal Estrogen Therapy Use and Survival in Females With Breast Cancer. *JAMA Oncol*. 2024;10(1):103. doi:10.1001/jamaoncol.2023.4508
26. Agrawal P, Singh SM, Able C, et al. Safety of Vaginal Estrogen Therapy for Genitourinary Syndrome of Menopause in Women With a History of Breast Cancer. *Obstet Gynecol*. 2023;142(3):660-668. doi:10.1097/AOG.0000000000005294
27. Portman DJ, Goldstein SR, Kagan R. Treatment of moderate to severe dyspareunia with intravaginal prasterone therapy: a review. *Climacteric*. 2019;22(1):65-72. doi:10.1080/13697137.2018.1535583
28. Parish SJ, Simon JA, Davis SR, et al. International Society for the Study of Women's Sexual Health Clinical Practice Guideline for the Use of Systemic Testosterone for Hypoactive Sexual Desire Disorder in Women. *J Sex Med*. 2021;18(5):849-867. doi:10.1016/j.jsxm.2020.10.009
29. Mortensen OE, Christensen SE, Løkkegaard E. The evidence behind the use of LASER for genitourinary syndrome of menopause, vulvovaginal atrophy, urinary incontinence and lichen sclerosis: A state-of-the-art review. *Acta Obstet Gynecol Scand*. 2022;101(6):657-692. doi:10.1111/aogs.14353
30. Cruff J, Khandwala S. A Double-Blind Randomized Sham-Controlled Trial to Evaluate the Efficacy of Fractional Carbon Dioxide Laser Therapy on Genitourinary Syndrome of Menopause. *J Sex Med*. 2021;18(4):761-769. doi:10.1016/j.jsxm.2021.01.188
31. Page A, Verbakel JY, Verhaeghe J, Latul YP, Housmans S, Deprest J. Laser versus sham for genitourinary syndrome of menopause: A randomised controlled trial. *BJOG Int J Obstet Gynaecol*. 2023;130(3):312-319. doi:10.1111/1471-0528.17335
32. Li FG, Maheux-Lacroix S, Deans R, et al. Effect of Fractional Carbon Dioxide Laser vs Sham Treatment on Symptom Severity in Women With Postmenopausal Vaginal Symptoms: A Randomized Clinical Trial. *JAMA*. 2021;326(14):1381. doi:10.1001/jama.2021.14892
33. Gordon C, Gonzales S, Krychman ML. Rethinking the techno vagina: a case series of patient complications following vaginal laser treatment for atrophy. *Menopause*. 2019;26(4):423-427. doi:10.1097/GME.0000000000001293
34. Preti M, Vieira-Baptista P, Digesu GA, et al. The clinical role of LASER for vulvar and vaginal treatments in gynecology and female urology: An ICS/ISSVD best practice consensus document. *Neurourol Urodyn*. 2019;38(3):1009-1023. doi:10.1002/nau.23931

35. Gunter J. Genitourinary Syndrome of Menopause and the False Promise of Vaginal Laser Therapy. *JAMA Netw Open*. 2023;6(2):e2255706. doi:10.1001/jamanetworkopen.2022.55706
36. Mardon RE, Halim S, Pawlson LG, Haffer SC. Management of Urinary Incontinence in Medicare Managed Care Beneficiaries: Results From the 2004 Medicare Health Outcomes Survey. *Arch Intern Med*. 2006;166(10):1128. doi:10.1001/archinte.166.10.1128
37. Lee UJ, Feinstein L, Ward JB, et al. Prevalence of Urinary Incontinence among a Nationally Representative Sample of Women, 2005–2016: Findings from the Urologic Diseases in America Project. *J Urol*. 2021;205(6):1718-1724. doi:10.1097/JU.0000000000001634
38. Offermans MPW, Du Moulin MFMT, Hamers JPH, Dassen T, Halfens RJG. Prevalence of urinary incontinence and associated risk factors in nursing home residents: A systematic review. *NeuroUrol Urodyn*. 2009;28(4):288-294. doi:10.1002/nau.20668
39. Wu JM, Vaughan CP, Goode PS, et al. Prevalence and Trends of Symptomatic Pelvic Floor Disorders in U.S. Women. *Obstet Gynecol*. 2014;123(1):141-148. doi:10.1097/AOG.0000000000000057
40. Marcelissen T, Anding R, Averbeck M, Hanna-Mitchell A, Rahnama'i S, Cardozo L. Exploring the relation between obesity and urinary incontinence: Pathophysiology, clinical implications, and the effect of weight reduction, ICI-RS 2018. *NeuroUrol Urodyn*. 2019;38(S5). doi:10.1002/nau.24072
41. Blomquist JL, Muñoz A, Carroll M, Handa VL. Association of Delivery Mode With Pelvic Floor Disorders After Childbirth. *JAMA*. 2018;320(23):2438-2447. doi:10.1001/jama.2018.18315
42. Pizzoferrato AC, Thuillier C, Vénara A, et al. Management of female pelvic organ prolapse—Summary of the 2021 HAS guidelines. *J Gynecol Obstet Hum Reprod*. 2023;52(3):102535. doi:10.1016/j.jogoh.2023.102535
43. Lukacz ES, Warren LK, Richter HE, et al. Quality of Life and Sexual Function 2 Years After Vaginal Surgery for Prolapse. *Obstet Gynecol*. 2016;127(6):1071-1079. doi:10.1097/AOG.0000000000001442
44. Hannestad YS, Lie RT, Rortveit G, Hunskaar S. Familial risk of urinary incontinence in women: population based cross sectional study. *BMJ*. 2004;329(7471):889-891. doi:10.1136/bmj.329.7471.889
45. Brown HW, Braun EJ, Wise ME, et al. Small-Group, Community-Member Intervention for Urinary and Bowel Incontinence. *Obstet Gynecol*. 2019;134(3):600-610. doi:10.1097/AOG.00000000000003422
46. Culbertson S, Davis AM. Nonsurgical Management of Urinary Incontinence in Women. *JAMA*. 2017;317(1):79. doi:10.1001/jama.2016.18433
47. Fitz FF, Gimenez MM, De Azevedo Ferreira L, Matias MMP, Bortolini MAT, Castro RA. Pelvic floor muscle training for female stress urinary incontinence: a randomised control trial comparing home and outpatient training. *Int Urogynecology J*. 2020;31(5):989-998. doi:10.1007/s00192-019-04081-x
48. Christmas MM, Iyer S, Daisy C, Maristany S, Letko J, Hickey M. Menopause hormone therapy and urinary symptoms: a systematic review. *Menopause*. 2023;30(6):672-685. doi:10.1097/GME.0000000000002187
49. Bunker C, Patel N, Shim T. Urinary Voiding Symptomatology (Micro-incontinence) in Male Genital Lichen Sclerosus. *Acta Derm Venereol*. 2013;93(2):246-248. doi:10.2340/00015555-1481
50. Kirby L, Gran S, Kreuser-Genis I, Owen C, Simpson R. Is urinary incontinence associated with lichen sclerosus in females? A systematic review and meta-analysis. *Skin Health Dis*. 2021;1(1):e13. doi:10.1002/ski2.13
51. Beele H, Smet S, Van Damme N, Beeckman D. Incontinence-Associated Dermatitis: Pathogenesis, Contributing Factors, Prevention and Management Options. *Drugs Aging*. 2018;35(1):1-10. doi:10.1007/s40266-017-0507-1
52. Lima AL, Timmermann V, Illing T, Elsner P. Contact Dermatitis in the Elderly: Predisposing Factors, Diagnosis, and Management. *Drugs Aging*. 2019;36(5):411-417. doi:10.1007/s40266-019-00641-4
53. Kraus CN. Vulvar Lichen Sclerosus. *JAMA Dermatol*. 2022;158(9):1088. doi:10.1001/jamadermatol.2022.0359
54. Meyer I, Richter HE. Impact of Fecal Incontinence and Its Treatment on Quality of Life in Women. *Womens Health*. 2015;11(2):225-238. doi:10.2217/WHE.14.66
55. Boredeianou L, Paquette I, Johnson E, et al. Clinical Practice Guidelines for the Treatment of Rectal Prolapse. *Dis Colon Rectum*. 2017;60(11):1121-1131. doi:10.1097/DCR.0000000000000889
56. Bliss DZ, Funk T, Jacobson M, Savik K. Incidence and Characteristics of Incontinence-Associated Dermatitis in Community-Dwelling Persons With Fecal Incontinence. *J Wound Ostomy Continence Nurs*. 2015;42(5):525-530. doi:10.1097/WON.0000000000000159
57. Aschenbeck KA, Warshaw EM. Allergenic Ingredients in Personal Hygiene Wet Wipes. *Dermatitis*. 2017;28(5):317-322. doi:10.1097/DER.0000000000000275
58. Newton J, Richardson S, Van Oosbre AM, Yu J, Silence C. A cross-sectional study of contact allergens in feminine hygiene wipes: a possible cause of vulvar contact dermatitis. *Int J Women's Dermatol*. 2022;8(4):e060. doi:10.1097/JW9.0000000000000060



59. Zendell K, Edwards L. Lichen Sclerosus With Vaginal Involvement: Report of 2 Cases and Review of the Literature. *JAMA Dermatol.* 2013;149(10):1199. doi:10.1001/jamadermatol.2013.4885
60. Bhargava K, Lewis FM. Lichen sclerosus occurring on vaginal mucosa secondary to uterine prolapse. *J Obstet Gynaecol.* 2013;33(3):319. doi:10.3109/01443615.2012.738720
61. Omosigho U, Propst K, Ferrando CA. Outcomes in Women With Pelvic Organ Prolapse Presenting With Pessary-Related Complications. *Urogynecology.* 2024;30(2):147-152. doi:10.1097/SPV.0000000000001402
62. Gold RS, Baruch Y, Amir H, Gordon D, Groutz A. A tailored flexible vaginal pessary treatment for pelvic organ prolapse in older women. *J Am Geriatr Soc.* 2021;69(9):2518-2523. doi:10.1111/jgs.17223
63. Dessie SG, Armstrong K, Modest AM, Hacker MR, Hota LS. Effect of vaginal estrogen on pessary use. *Int Urogynecology J.* 2016;27(9):1423-1429. doi:10.1007/s00192-016-3000-1
64. Thorneloe RJ, Bundy C, Griffiths CEM, Ashcroft DM, Cordingley L. Nonadherence to psoriasis medication as an outcome of limited coping resources and conflicting goals: findings from a qualitative interview study with people with psoriasis. *Br J Dermatol.* 2017;176(3):667-676. doi:10.1111/bjd.15086
65. Mounsey SJ, Teo YX, Calonje JE, Lewis FM. Gliflozin (SGLT2 inhibitor) induced vulvitis. *Int J Dermatol.* 2023;62(1):62-65. doi:10.1111/ijd.16449
66. Forman JL, Mercurio MG. Vulvar Pruritus in Postmenopausal Diabetic Women With Candidiasis Secondary to Sodium-Glucose Cotransporter Receptor-2 Inhibitors. *J Low Genit Tract Dis.* 2023;27(1):68-70. doi:10.1097/LGT.0000000000000704
67. Watkins P. The use of emollient therapy for ageing skin. *Nurs Older People.* 2011;23(5):31-38. doi:10.7748/nop2011.06.23.5.31.c8530
68. Wijaya M, Lee G, Fischer G. Why do some patients with vulval lichen sclerosus on long-term topical corticosteroid treatment experience ongoing poor quality of life? *Australas J Dermatol.* 2022;63(4):463-472. doi:10.1111/ajd.13926

## Future directions

*Gudula Kirtschig, Hans Verstraelen, Andrew Goldstein, Leia Mitchell,  
Jaclyn Lanthier, Rosalind Simpson*

Inclusion of female subjects in medical research has only been mandated in the United States (US) since 1993, marking a pivotal shift towards the inclusion of women and people of color in government-funded clinical trials.<sup>1</sup> Around the world, groups within and external to governments have highlighted persistent gender inequities in what diseases are prioritized, which researchers receive funding, and how studies collect and interpret data on women. During the past several years, multiple countries have undertaken a deeper commitment to addressing gender bias in medicine: the US President announced the inaugural White House Initiative on Women's Health Research in November 2023, the European Union undertook the 2023 European Scoping Study to tackle high-burden, under-researched medical conditions like LS, and the United Kingdom (UK) committed to a 2022 Women's Health Strategy for England.<sup>2</sup> This emerging visibility of women's health research provides an opportunity for the community of LS practitioners and patients to advance our work in prevention, diagnosis, treatment, advocacy, education, and implementation to improve the lives of girls and women with LS.

### Investigating pathogenesis to identify preventative and therapeutic targets

Improved understanding of LS pathogenesis may provide novel prevention strategies and therapeutic targets.<sup>3</sup> Tran and colleagues propose three categories of potential immune and genetic targets, defined by their mechanistic role in LS development: 1) loss of self-tolerance leading to autoimmune inflammation, 2) disruption of fibroblast and collagen homeostasis, and 3) oxidative stress.<sup>4</sup> Although a preclinical animal model for LS is lacking, knowledge of these pathways may be gained through proteomics, transcriptomics, epigenetics, and analysis of non-coding RNAs such as microRNAs.<sup>5-12</sup>

Loss of self-tolerance and the emergence of extracellular matrix protein-1 (ECM-1) autoantibodies has long been suspected to involve local triggers in the context of a predisposing genetic background.<sup>13</sup> Four genes have been identified as associated with propensity to LS but this requires further evaluation.<sup>14</sup>

Autoimmune inflammation in LS manifests as dermal T-cell infiltration, consisting of CD8+ cells, followed in quantity by CD4+ T cells and FOXP3+ regulatory T (Treg) cells. The inflammatory infiltrate shows pronounced expression of chemokine receptors CXCR3 and CCR5

with a proinflammatory cytokine profile of upregulated IFN- $\gamma$ , TNF- $\alpha$ , and interleukins (IL) IL-1 $\alpha$ , IL-7, IL-15. A positive feedback loop driven by IFN- $\gamma$  results in further recruitment of Th1 cells.<sup>4,15</sup> This constellation of effects represents a Th1 cellular immunity response that activates macrophages and stimulates B-cell production of IgM and IgG. Janus kinase (JAK) inhibitors, used to treat a variety of immune-mediated dermatologic conditions, owe their immunomodulatory effects to blocking downstream cytokine signaling. A multicenter trial of a topical JAK 1/2 inhibitor, ruxolitinib, is underway for LS.<sup>16</sup>

The Th1 autoimmune profile also likely involves dysregulation of Treg-cell-mediated suppression through dysfunctional rather than reduced Treg cells.<sup>4</sup> Overexpression of miR-NA-155 or miR-155, a key immune regulator, likely plays an important role in Treg dysregulation and therefore represents a therapeutic target for multiple disease processes.<sup>17</sup> Another potential mechanism of T-cell-related immune dysregulation involves PD-1/PD-L1 checkpoint inhibitors that are involved in programmed cell death; several PD1 inhibitors are approved as cancer immunotherapy but cause an array of autoimmune phenomenon.<sup>6</sup>

The sclerosis that defines LS histopathology likely arises from fibroblast proliferation and persistence, with increased expression of collagens type I, III, and V. This process is mediated by miR-155 expression, decreases in FOXO3 and CDKN1B suppressor gene expression, increased expression of galectin-7 that paradoxically inhibits fibroblast growth, and increased matrix metalloprotein 9 (MMP9) activity resulting from ECM-1 autoimmunity.<sup>5,18</sup> Reduction in dermal elastin fibers is associated with aberrantly high collagen V deposition while focal basement membrane disruption likely results from excessive MMP9 collagenase activity. An miR-155 inhibitor may represent a multimodal therapeutic approach that could target both autoimmune inflammation and dermal fibroblast and collagen homeostasis in LS.

Oxidative stress appears to influence LS perpetuation through several pathways. Reactive oxygen species likely interact with apoptotic macromolecules to create new epitopes for autoimmunity activation. Overexpression of p53 in basal keratinocytes may represent a compensatory mechanism against oxidative stress. Reduced levels of antioxidant enzymes like superoxide dismutase contribute to oxidative damage. Finally, oxidative stress is likely also involved in the emergence of cell proliferation and immortality that produce malignant transformation within LS to SCC.<sup>19</sup>

The contribution of vulvovaginal, urinary, and gut microbiota to LS pathogenesis and perpetuation is largely unexplored. The accuracy of results in microbiome studies relies on appropriate use of site-specific primers. Assessment of skin requires the V1-V3 region of the 16S rRNA gene, while evaluation of fecal bacteria requires the V4 region.<sup>20</sup> Four studies have used amplicon sequencing of V3 and/or V4 regions targeting vulvovaginal skin in 5 premenarchal girls and 62 adults with LS compared to 54 controls.<sup>21-24</sup> These studies suggest no difference in local diversity ( $\alpha$ -diversity) but possible increased diversity across different sites ( $\beta$ -diversity) with no single species identified as distinct to LS. In contrast, assessment of microbiota at interlabial sulci of 6 treatment-naïve postmenopausal women with LS versus 12 controls found a loss of  $\alpha$ -diversity and depletions of *Lactobacillus jensenii* and *Bacteroides* species.<sup>25</sup> Further work in this area would benefit from larger sample sizes and metagenomic shotgun sequencing.

## Establishing diagnostic criteria and a clinical severity scale

Exact diagnostic criteria for LS are not established. A major problem arises partly from non-specific signs and symptoms of LS, especially in early disease. This often results in a delayed diagnosis of LS and consequently the development of irreversible architectural change. This is particularly frustrating, as prompt diagnosis with appropriate treatment will prevent such irreversible damage. Histological examination of the tissue can be helpful in making a diagnosis, however, it is important to biopsy the right area (see Chapter 4).

There is likewise no widely accepted scoring system available to assess disease progression. A number of scoring systems are suggested; however, these are not agreed upon and have not found their way into clinical practice (see Table 1). Therefore, the first step is to establish diagnostic criteria that forecast the likelihood of a diagnosis of LS according to a set of signs and symptoms, and then develop a scoring system that enables evaluation of disease progression.

**TABLE 1 Proposed lichen sclerosis scoring systems**

Classification system	Components
Günther scale <sup>26</sup>	Score for diagnosing and assessing treatment response encompassing 4 patient-assessed symptoms: pruritus, burning, soreness, dyspareunia and 6 clinician-assessed features: erosions, hyperkeratosis, fissures, agglutination, stenosis, and atrophy
VASS - Vulvar architectural severity scale <sup>27</sup>	Scale based on anatomical subunits used to grade architectural damage that scores 4 components, each described as none to severe
CIV <sup>28</sup>	Scale developed to grade Clitoral phimosis, Interlabial sulci involvement, and Vulvar introitus narrowing from minimal to extremely severe
Sheinis & Selk <sup>29</sup>	Delphi exercise in which experts graded essential disease signs and architectural changes with a 4-point Likert scale and determined what elements should be included in future scales
CLISSCO - Clinical lichen sclerosis score <sup>30</sup>	Score included 3 symptoms, 3 signs, and 6 architectural changes rated using a 0-4 Likert-scale
SWIFT <sup>31</sup>	Predictive tool for identifying likely cases of premenarchal LS using features of Soreness, Whitening, Incontinence, Fissures, and clitoral hood Thickening
VASSI - Vulvar lichen sclerosis Area and Sign Severity Index <sup>32</sup>	Score judging the presence and extent of non-permanent signs of hyperkeratosis, fissures/erosions, and ecchymoses in 5 areas of the vulva using a 0-4 Likert-scale to assess disease activity

## Demanding longer-term outcome data and higher quality interventional trials

Despite its high prevalence and disease impacts, vulvovaginal conditions remain an under-researched area and the lack of high-quality evidence perpetuates interprovider variation and low-value interventions.<sup>33</sup> Recent systematic reviews addressing topical treat-

ments for LS, laser therapy, and platelet rich plasma identified that pertinent studies were hampered by poor methodological quality with heterogeneous populations and outcome reporting.<sup>34-36</sup> The European Commission identified LS as a condition receiving insufficient research funding relative to the levels expected based on disease burden.<sup>37</sup>

The need for consistent outcome measurement in LS clinical trials was highlighted in the 2018 Lichen Sclerosus Priority Setting Partnership.<sup>3</sup> The effort to produce a Core Outcome Set (COS) for LS is underway, in parallel with the international movement to develop and promote COS through initiatives such as COMET (Core Outcomes Measures for Effectiveness Trials), CROWN (Core Outcomes for Women's and Neonatal Health) and the CHORD COUSIN Collaboration for skin diseases.<sup>38-40</sup> The 'Core Outcome Set for Research in Lichen Sclerosus' (CORALS) initiative is led by an international multi-stakeholder steering group with the aim to establish international consensus on outcome domains and tools. To date, the group achieved agreement on *quality of life - LS specific, symptoms, and clinical (visible) signs* as essential domains that should be incorporated into study protocols with immediate effect.<sup>41</sup> Current work involves identifying elements for each domain and validated measurement tools while balancing data richness with feasibility and generalizability across varied health systems. The LS Priority Setting Partnership also highlighted the need to assess long-term outcomes for both active and well-controlled LS over the entire lifespan. This would require a prospectively maintained multicenter database and a commitment to continue surveillance of patients diagnosed in childhood even when disease appears inactive.

While many interventions have been suggested for LS clinical trials, study priority should be based on relevance to the clinical and patient community, feasibility to achieve methodologic quality, minimization of duplication, and the ethical obligation to provide subjects with access to effective and proven topical steroid management.<sup>42,43</sup> Single-center uncontrolled reports on medical devices do little to advance quality care for women with LS. Investigators with limited experience in managing vulvar dermatoses are not well placed to design studies comparing topical steroids with other interventions. Robust peer review is essential to break the harm cycle of irresponsible promotion of costly medications or procedures, dissemination of experimental interventions into routine practice, gradual accumulation of data on non-efficacy and complications, eventual retreat from that intervention, then emergence of another purported 'miracle' solution. Open access publication ensures the range of stakeholders has access to key positive findings and unsuccessful strategies.

## Advocacy, education, & implementation challenges

Inadequate patient, provider, and general public knowledge creates multiple barriers to prompt diagnosis and effective management of LS.<sup>44</sup> Community unfamiliarity with LS contributes to the sense of isolation and stigma that may prevent care-seeking, reduce treatment self-efficacy, and diminish QoL.<sup>45-48</sup> Support groups such as Lichen Sclerosus Support Network, The Lost Labia Chronicles, and Lichen Sclerosus and Vulval Cancer Awareness UK alleviate this by providing visibility for the condition and a safe space for patients to express their feelings, share experiences, and connect with a community.<sup>49</sup> These groups and their social media platforms also provide encouragement and advice about self-advocacy and strategies to navigate the healthcare system. Support group leaders often transition to

expanded patient advocacy roles - creating community educational content, lobbying for funding and access to quality care, promoting clinical research, and driving the dissemination of patient-oriented evidence-based resources. Non-profit foundations, condition-specific groups, and healthcare provider organizations are also active in health advocacy for LS.<sup>50</sup>

Enhanced collaboration between patients and medical societies is key to future progress in LS research and education. One pathway for this is patient representation in the design of major research initiatives. Advocates guide investigators in prioritizing research questions, addressing feasibility and tolerability of interventions, assessing suitability of follow-up mechanisms, and advising on construction and language of consents, surveys, and patient-derived outcome measures. After studies are published, patient advocates promote knowledge dissemination through support groups and social media to enhance health literacy and informed decision-making.

Collaboration between medical and patient organizations likewise represents a strategy to address unacceptable gaps in healthcare provider knowledge of LS and other vulvovaginal conditions. Despite being common and impactful, LS sits at the intersection of general practice (GP), gynecology, dermatology, and sexual health but is not considered 'core business' of any of these specialties.<sup>51,52</sup> Provider awareness of LS should begin in professional schools with case-based modules that include high-quality photographs, clinical notes, pathology reports, and online resources.<sup>53</sup> General practice training in women's health should incorporate exposure to genital skin conditions in addition to family planning, general gynecology, and pregnancy modules. Dermatology training programs should offer opportunities for exposure to vulvar skin conditions, speculum examination, vaginitis, and HPV-associated disease, while gynecology programs should support involvement in a dedicated vulvar clinic. Specialist credentialing examinations should incorporate routine questions on vulvovaginal disease and continuing medical education programs in sexual health, gynecology, and dermatology should ensure regular sessions addressing advancements in diagnosis and treatment. Establishing smoother referral processes and promoting payment for multidisciplinary communication helps to bridge gaps between specialties and improve the patient journey.

Gender bias in medical systems and culture contributes to inadequate care of LS. Compared to female GPs, male practitioners report reluctance to take a sexual history, inexperience in gynecologic complaints, and insecurity about genitopelvic examination.<sup>54,55</sup> Gender bias is well documented in assessment of disability, treatment of pain, content of clinical practice guidelines, and reimbursement for surgical procedures done for female versus male patients.<sup>56-60</sup> While there is scant literature addressing the relationship between gender bias and inadequacies in vulvovaginal care, it likely has far-reaching consequences to include interpersonal interactions that minimize patient experiences of LS, non-prioritization of dedicated vulvar clinics, non-allocation of trainees to these clinics, unfavorable hiring practices, maldistribution of operating room resources, and disadvantage in research publication and funding processes.

## Limitations of the literature

Inter- and intraobserver reliability in LS diagnosis and severity assessment has been difficult to achieve outside of single-center studies. Clarification of nomenclature is an essential first

step to achieving consensus among researchers and clinicians. There is ongoing controversy regarding the relative importance of signs more specific to LS, like white color change and ecchymoses, compared to signs seen in other conditions, like fissures and edema. Experts have also encountered difficulty in achieving consensus on the degree of concern associated with a given finding and how the constellation of features yields a severity score. There are conflicting reports about the similarity or divergence of clinical features in childhood versus adult LS.<sup>61–63</sup> This lack of consensus impacts on all clinical research on LS, manifesting as heterogeneous study populations, variable interpretations of response to treatment, and inability to compare studies done in different centers. The CORALS group may find that none of the work to date achieves the objective of a reproducible, reliable assessment tool that functions across diverse populations, countries, and health systems.

## Conclusions and recommendations

Addressing gaps in high quality LS-related research, advocacy, education, and implementation requires a collective commitment from national health departments and scientific policy makers, medical professionals, patients, non-profits organizations, specialist training oversight bodies, and medical schools.

- As with any chronic disease, funding and collection of long-term prospective multi-center data is essential to understand LS epidemiology and treatment outcomes.
- Consensus-based and validated severity scoring systems and core outcome sets are essential to delivering methodologically sound and externally valid clinical trials of LS interventions.
- Collaboration between patient support groups, patient advocates, clinical academics, and medical organizations yields benefits in research quality and implementation.
- The tireless work of researchers and advocates has achieved admirable progress in documenting gender bias in medicine, highlighting the public health importance of LS, raising community awareness, and establishing the need for improved provider education and knowledge translation.

## References

1. House - Energy and Commerce. H.R.4 - National Institutes of Health Revitalization Act of 1993. Published online March 24, 1993. Accessed July 28, 2024. <https://www.congress.gov/bill/103rd-congress/house-bill/4>
2. The White House. Launch of White House Initiative on Women's Health Research. Published online 2023. Accessed July 27, 2024. [https://www.whitehouse.gov/gpc/briefing-room/2023/11/17/launch-of-white-house-initiative-on-womens-health-research/?utm\\_source=link](https://www.whitehouse.gov/gpc/briefing-room/2023/11/17/launch-of-white-house-initiative-on-womens-health-research/?utm_source=link).
3. Simpson RC, Cooper SM, Kirtschig G, et al. Future research priorities for lichen sclerosis – results of a James Lind Alliance Priority Setting Partnership. *Br J Dermatol*. 2019;180(5):1236-1237. doi:10.1111/bjd.17447
4. Tran DA, Tan X, Macri CJ, Goldstein AT, Fu SW. Lichen Sclerosis: An autoimmunopathogenic and genomic enigma with emerging genetic and immune targets. *Int J Biol Sci*. 2019;15(7):1429-1439. doi:10.7150/ijbs.34613
5. Oyama N, Hasegawa M. Lichen Sclerosis: A Current Landscape of Autoimmune and Genetic Interplay. *Diagnostics*. 2022;12(12):3070. doi:10.3390/diagnostics12123070
6. Gleue CA, Xie F, Deschaine M, et al. Differential proteomic expression in indolent vulvar lichen sclerosis, transforming vulvar lichen sclerosis and normal vulvar tissue. *Exp Dermatol*. 2022;31(12):1920-1926. doi:10.1111/exd.14660
7. Xie F, Dasari S, Deschaine M, et al. Differential proteomic expression profiles in vulvar lichen planus as com-



- pared to normal vulvar tissue, vulvar lichen sclerosis, or oral lichen planus: An exploratory study. *Exp Dermatol*. 2023;32(9):1498-1508. doi:10.1111/exd.14854
8. Wang L, Lv Q, Guo J, Wang J, Pan J. Transcriptome Profiling and Network Analysis Provide Insights Into the Pathogenesis of Vulvar Lichen Sclerosis. *Front Genet*. 2022;13:905450. doi:10.3389/fgene.2022.905450
  9. Wang L, Yi JL, Chen HY, Wang PL, Shen YL. Level of Foxp3, DNMTs, methylation of Foxp3 promoter region, and CD4 + CD25 + CD127low regulatory T cells in vulvar lichen sclerosis. *Kaohsiung J Med Sci*. 2021;37(6):520-527. doi:10.1002/kjm2.12356
  10. Ren L, Zhao Y, Huo X, Wu X. MiR-155-5p promotes fibroblast cell proliferation and inhibits FOXO signaling pathway in vulvar lichen sclerosis by targeting FOXO3 and CDKN1B. *Gene*. 2018;653:43-50. doi:10.1016/j.gene.2018.01.049
  11. Tan X, Ren S, Yang C, et al. Differentially Regulated miRNAs and Their Related Molecular Pathways in Lichen Sclerosis. *Cells*. 2021;10(9):2291. doi:10.3390/cells10092291
  12. Yang M, Sun K, Chang J. Screening differential circular RNAs expression profiles in Vulvar Lichen Sclerosis. *Biomed Eng Online*. 2022;21(1):51. doi:10.1186/s12938-022-01013-7
  13. Wolf B, Horn LC, Höckel M. Anogenital lichen sclerosis: Change of tissue position as pathogenetic factor. *Gynecol Oncol Rep*. 2017;20:73-74. doi:10.1016/j.gore.2017.03.003
  14. Haefner HK, Welch KC, Rolston AM, et al. Genomic Profiling of Vulvar Lichen Sclerosis Patients Shows Possible Pathogenetic Disease Mechanisms. *J Low Genit Tract Dis*. 2019;23(3):214-219. doi:10.1097/LGT.0000000000000482
  15. De Luca DA, Papara C, Vorobyev A, et al. Lichen sclerosis: The 2023 update. *Front Med (Lausanne)*. 2023;10:1106318. doi:10.3389/fmed.2023.1106318
  16. Incyte Corporation. A Study to Evaluate the Efficacy and Safety of Ruxolitinib Cream in Participants With Lichen Sclerosis ClinicalTrials.gov ID NCT05593445. Published online January 24, 2024. Accessed July 28, 2024. <https://clinicaltrials.gov/study/NCT05593445?a=9#study-overview>
  17. Terlou A, Santegoets LAM, van der Meijden WI, et al. An autoimmune phenotype in vulvar lichen sclerosis and lichen planus: a Th1 response and high levels of microRNA-155. *J Invest Dermatol*. 2012;132(3 Pt 1):658-666. doi:10.1038/jid.2011.369
  18. Fischer S, Greene C, Hopson A, et al. (021) A Novel Model to Study Fibrosis and Scarring in Vulvar Lichen Sclerosis. *The Journal of Sexual Medicine*. 2023;20(Supplement\_2):qdad061.021. doi:10.1093/jsxmed/qdad061.021
  19. Paulis G, Berardesca E. Lichen sclerosis: the role of oxidative stress in the pathogenesis of the disease and its possible transformation into carcinoma. *Res Rep Urol*. 2019;11:223-232. doi:10.2147/RRU.S205184
  20. Kong HH. Details Matter: Designing Skin Microbiome Studies. *Journal of Investigative Dermatology*. 2016;136(5):900-902. doi:10.1016/j.jid.2016.03.004
  21. Chattopadhyay S, Arnold JD, Malayil L, et al. Potential role of the skin and gut microbiota in premenarchal vulvar lichen sclerosis: A pilot case-control study. *PLoS One*. 2021;16(1):e0245243. doi:10.1371/journal.pone.0245243
  22. Liu X, Zhuo Y, Zhou Y, Hu J, Wen H, Xiao C. Analysis of the Vulvar Skin Microbiota in Asymptomatic Women and Patients With Vulvar Lichen Sclerosis Based on 16S rRNA Sequencing. *Front Cell Dev Biol*. 2022;10:842031. doi:10.3389/fcell.2022.842031
  23. Brunner A, Medvecz M, Makra N, et al. Human beta defensin levels and vaginal microbiome composition in post-menopausal women diagnosed with lichen sclerosis. *Sci Rep*. 2021;11(1):15999. doi:10.1038/s41598-021-94880-4
  24. Nygaard S, Gerlif K, Bundgaard-Nielsen C, et al. The urinary, vaginal and gut microbiota in women with genital lichen sclerosis - A case-control study. *Eur J Obstet Gynecol Reprod Biol*. 2023;289:1-8. doi:10.1016/j.ejogrb.2023.08.004
  25. Pyle HJ, Evans JC, Artami M, et al. Assessment of the Cutaneous Hormone Landscapes and Microbiomes in Vulvar Lichen Sclerosis. *J Invest Dermatol*. 2024;144(8):1808-1816.e11. doi:10.1016/j.jid.2024.01.027
  26. Günther AR, Duclos K, Jahns BG, et al. Clinical scoring system for vulvar lichen sclerosis. *J Sex Med*. 2012;9(9):2342-2350. doi:10.1111/j.1743-6109.2012.02814.x
  27. Almadori A, Zenner N, Boyle D, et al. Development and Validation of a Clinical Grading Scale to Assess the Vulvar Region: The Vulvar Architecture Severity Scale. *Aesthet Surg J*. 2020;40(12):1319-1326. doi:10.1093/asj/sjz342
  28. Boero V, Liverani CA, Brambilla M, et al. The "CIV Classification," a New Proposal for the Architectural Grading of Vulvar Lichen Sclerosis. *J Low Genit Tract Dis*. 2021;25(4):291-295. doi:10.1097/LGT.0000000000000627
  29. Sheinis M, Selk A. Development of the Adult Vulvar Lichen Sclerosis Severity Scale-A Delphi Consensus Exercise for Item Generation. *J Low Genit Tract Dis*. 2018;22(1):66-73. doi:10.1097/LGT.0000000000000361
  30. Erni B, Navarini AA, Huang D, Schoetzau A, Kind A, Mueller SM. Proposition of a severity scale for lichen sclerosis: The "Clinical Lichen Sclerosis Vash." *Dermatol Ther*. 2021;34(2):e14773. doi:10.1111/dth.14773
  31. Wang M, Wininger M, Vash-Margita A. The SWIFT Model for Lichen Sclerosis Among Premenarchal Girls. *J Low Genit Tract Dis*. 2022;26(1):46-52. doi:10.1097/LGT.0000000000000634

32. MC2 Therapeutics. Efficacy and Safety of MC2-25 Cream & Vehicle in Women With Vulvar Lichen Sclerosis (VLS) (Orchid 1). Published online June 20, 2024. Accessed July 28, 2024. <https://clinicaltrials.gov/study/NCT06132919>
33. Drumm C, Chawla S, Kravvas G, Spencer A, Bunker CB, Watchorn RE. Representation of genital dermatoses in dermatological literature. *Br J Dermatol*. 2023;188(4):563-564. doi:10.1093/bjd/ljac117
34. Pergialiotis V, Bellou I, Biliou EC, Varnava P, Mitsopoulou D, Doumouchtsis SK. An arm-based network meta-analysis on treatments for vulvar lichen sclerosis and a call for development of core outcome sets. *American Journal of Obstetrics and Gynecology*. 2020;222(6):542-550.e6. doi:10.1016/j.ajog.2019.10.095
35. Tasker F, Kirby L, Grindlay DJC, Lewis F, Simpson RC. Laser therapy for genital lichen sclerosis: A systematic review of the current evidence base. *Skin Health and Disease*. 2021;1(3):e52. doi:10.1002/ski.252
36. Villalpando BK, Wyles SP, Schaefer LA, Bodiford KJ, Bruce AJ. Platelet-rich plasma for the treatment of lichen sclerosis. *Plast Aesthet Res*. 2021;8:63. doi:10.20517/2347-9264.2021.86
37. European Commission. Directorate General for Research and Innovation. Scoping Study on Evidence to Tackle High-Burden under-Researched Medical Conditions: *Discussion Paper*. Publications Office; 2023. Accessed July 28, 2024. <https://data.europa.eu/doi/10.2777/311040>
38. Core Outcome Measures in Effectiveness Trials. Accessed July 28, 2024. <https://www.comet-initiative.org/>
39. Molloy EJ, Gale C, Marsh M, Bearer CF, Devane D, Modi N. Developing core outcome set for women's, newborn, and child health: the CROWN Initiative. *Pediatr Res*. 2018;84(3):316-317. doi:10.1038/s41390-018-0041-9
40. The CHORD COUSIN collaboration. Accessed July 28, 2024. <https://www.c3outcomes.org/>
41. Simpson RC, Kirtschig G, Selk A, et al. Core outcome domains for lichen sclerosis: a CORALS initiative consensus statement. *Br J Dermatol*. 2023;188(5):628-635. doi:10.1093/bjd/ljac145
42. Chalmers I, Glasziou P. Avoidable waste in the production and reporting of research evidence. *Lancet*. 2009;374(9683):86-89. doi:10.1016/S0140-6736(09)60329-9
43. European Dermatology Forum. EDF Guidelines and consensus statements. Accessed July 28, 2024. <https://www.guidelines.edf.one/edf-guidelines-and-consensus-statements>
44. Krapf JM, Mitchell L, Holton MA, Goldstein AT. Vulvar Lichen Sclerosis: Current Perspectives. *Int J Womens Health*. 2020;12:11-20. doi:10.2147/IJWH.S191200
45. Arnold S, Fernando S, Rees S. Living with vulvar lichen sclerosis: a qualitative interview study. *British Journal of Dermatology*. 2022;187(6):909-918. doi:10.1111/bjd.21777
46. Sadownik LA, Koert E, Maher C, Smith KB. A Qualitative Exploration of Women's Experiences of Living With Chronic Vulvar Dermatoses. *J Sex Med*. 2020;17(9):1740-1750. doi:10.1016/j.jsxm.2020.06.016
47. Sivalingam V, Tamber K. Understanding the impact of life with vulvar lichen sclerosis. *Br J Dermatol*. 2022;187(6):840. doi:10.1111/bjd.21846
48. Ranum A, Pearson DR. The impact of genital lichen sclerosis and lichen planus on quality of life: A review. *Int J Womens Dermatol*. 2022;8(3):e042. doi:10.1097/JW9.0000000000000042
49. Wehbe-Alamah H, Kornblau BL, Haderer J, Erickson J. Silent no more! The lived experiences of women with lichen sclerosis. *J Am Acad Nurse Pract*. 2012;24(8):499-505. doi:10.1111/j.1745-7599.2012.00715.x
50. Bu X, Jezewski MA. Developing a mid-range theory of patient advocacy through concept analysis. *J Adv Nurs*. 2007;57(1):101-110. doi:10.1111/j.1365-2648.2006.04096.x
51. Margesson LJ. Practice gaps: Practice gaps "down there": failures in education, physical examination, recognition, diagnosis, therapy, follow-up care, and cancer surveillance in lichen sclerosis. *JAMA Dermatol*. 2013;149(10):1203. doi:10.1001/jamadermatol.2013.4895
52. Schlosser BJ. Practice gaps. Missing genital lichen sclerosis in patients with morphea: don't ask? Don't tell?: comment on "High frequency of genital lichen sclerosis in a prospective series of 76 patients with morphea." *Arch Dermatol*. 2012;148(1):28-29. doi:10.1001/archdermatol.2011.2097
53. Comstock JR, Endo JO, Kornik RI. Adequacy of dermatology and ob-gyn graduate medical education for inflammatory vulvovaginal skin disease: A nationwide needs assessment survey. *Int J Womens Dermatol*. 2020;6(3):182-185. doi:10.1016/j.ijwd.2020.01.008
54. Virgolino A, Roxo L, Alarcão V. Facilitators and Barriers in Sexual History Taking. In: IsHak WW, ed. *The Textbook of Clinical Sexual Medicine*. Springer International Publishing; 2017:53-78. doi:10.1007/978-3-319-52539-6\_5
55. Salazar A, Andrade FF. Gynecologic History and Examination of the Patient. In: Shoupe D, ed. *Handbook of Gynecology*. Springer International Publishing; 2017:11-19. doi:10.1007/978-3-319-17798-4\_15
56. Cabral M, Dillender M. Gender Differences in Medical Evaluations: Evidence from Randomly Assigned Doctors. *American Economic Review*. 2024;114(2):462-499. doi:10.1257/aer.20220349

57. Rose-McCandlish MA, Anastas TM, Miller MM, Hirsh AT. Gender Bias in Pain Care: What Physicians Say Versus What They Do. *The Journal of Pain*. 2024;25(4):66-67. doi:10.1016/j.jpain.2024.01.305
58. Rivera-Izquierdo M, Maes-Carballo M, Jiménez-Moleón JJ, et al. Gender bias in shared decision-making among cancer care guidelines: A systematic review. *Health Expectations*. 2023;26(3):1019-1038. doi:10.1111/hex.13753
59. Chaikof M, Cundiff GW, Mohtashami F, et al. Surgical sexism in Canada: structural bias in reimbursement of surgical care for women. *cjs*. 2023;66(4):E341-E347. doi:10.1503/cjs.022121
60. Watson KL, King LP. Double Discrimination, the Pay Gap in Gynecologic Surgery, and Its Association With Quality of Care. *Obstet Gynecol*. 2021;137(4):657-661. doi:10.1097/AOG.0000000000004309
61. Cooper SM, Gao XH, Powell JJ, Wojnarowska F. Does Treatment of Vulvar Lichen Sclerosus Influence Its Prognosis? *Arch Dermatol*. 2004;140(6). doi:10.1001/archderm.140.6.702
62. Morrel B, Ewing-Graham PC, van der Avoort IAM, Pasmans SGMA, Damman J. Structured analysis of histopathological characteristics of vulvar lichen sclerosus in a juvenile population. *Hum Pathol*. 2020;106:23-31. doi:10.1016/j.humpath.2020.09.003
63. Smith SD, Fischer G. Paediatric vulval lichen sclerosus. *Australas J Dermatol*. 2009;50(4):243-248. doi:10.1111/j.1440-0960.2009.00530.x

# Glossary of anatomic, dermatologic, and dermatopathologic terminology

## Vulvar anatomy

**Anterior commissure** – Where the labia majora meet in the midline at the top

**Anal verge** – The lower edge of the anal canal at the junction of hairless skin and non-keratinized squamous epithelium

**Bartholin's gland openings** – Also known as major vestibular glands, these glands produce mucinous fluid and open at the base of the hymen at 4 o'clock and 8 o'clock

**Base of hymen** – The bottom of the hymen where it connects with the vestibule, an area with robust immune system activity and many gland openings and nerves

**Clitoral frenulum** – Where the lower division of the labia minora join together under the glans clitoris

**Clitoral glans** – The tip of the body of the clitoris, the only visible part of a much larger structure made up of erectile tissue and nerves and covered in hairless skin

**Clitoral hood** – Also called prepuce, a fold of hairless skin that surrounds and protects the glans clitoris, it is formed by the upper division of the labia minora

**Free edge of hymen** – Soft stretchy tissue that delineates the vestibule and vagina, covered in non-keratinized squamous epithelium, may become flattened in some places due to trauma or childbirth

**Fossa navicularis** – A triangular area between the base of the hymen and the posterior fourchette, often looks shiny and pink-red

**Interlabial sulcus** (*plural = interlabial sulci*) – Also called interlabial fold, the area between the labia majora and labia minora, a transition from hairless skin to hair bearing skin

**Labia majora** (*singular = labium majus*) – Two folds of hair bearing skin with fat pads underneath that extend from the mons pubis to the buttock, they meet at the anterior commissure at the top and the perineum (also called the posterior commissure) at the bottom

**Labia minora** (*singular = labium minus*) – Two folds of hairless skin with connective and erectile tissue underneath that protect the vaginal and urethral openings, they divide at the top to form the clitoral hood and clitoral frenulum

**Minor vestibular glands** – Small glands that open at the base of the hymen and produce fluid to lubricate the vestibule

**Mons pubis** – Area of hair bearing skin above the anterior commissure, below the abdomen, and medial to the inguinal fold with a fat pad underneath

**Natal cleft** – The fold between the buttocks

**Perianal** – An adjective signifying the area of hair bearing skin between the anal verge and out to 5cm circumferentially, used to modify nouns like skin, area, or region; the noun perianus is an acceptable although uncommon alternative

**Periclitoral** – An adjective signifying the area around the glans clitoris bounded by the anterior commissure anteriorly, the sulcus between clitoral hood and labia majora, and clitoral frenulum

**Perineum** – The area between the vagina and anus where the labia majora meet at the back, the center is hairless skin and the sides are hair bearing skin

**Periurethral** – An adjective signifying the area within the vestibule bounded by clitoral frenulum anteriorly, suburethral vagina posteriorly, and Hart's line laterally

**Posterior fourchette** – The meeting point of the bottom of the labia minora, may be raised or flat hairless skin

**Skene's gland openings** – These paraurethral glands produce fluid that helps lubricant the vestibule and urethral meatus with gland openings sometimes visible lateral to the urethral meatus

**Superficial sebaceous glands** – Sebum-producing glands located in upper dermis of hairless skin and non-keratinized epithelium over inner and outer labia minora, often visible as cream-yellow micropapules, also called Fordyce spots

**Urethral meatus** – The end of a short muscular tube that transports urine from the bladder, contains a transition between squamous and transitional epithelium

**Vagina** – A muscular canal extending from the hymen to the cervix covered in non-keratinized squamous epithelium

## Dermatologic terminology

### Adapted from:

Lynch PJ, Moyal-Barracco M, Scurry J, Stockdale C. 2011 ISSVD Terminology and classification of vulvar dermatological disorders: an approach to clinical diagnosis. *J Low Genit Tract Dis.* 2012;16(4):339-344. doi:10.1097/LGT.0b013e3182494e8c

Nast A, Griffiths CE, Hay R, Sterry W, Bologna JL. The 2016 International League of Dermatological Societies' revised glossary for the description of cutaneous lesions. *Br J Dermatol.* 2016;174(6):1351-1358. doi:10.1111/bjd.14419

**Adhesion** – Joining of structures that previously were separate, usually due to inflammation or healed injury

**Agglutination** – Process of sealing of previously distinct apposed structures, often applied to the adhesions in the vagina or between the labium minus and interlabial sulcus

**Atrophy** – Thinning of epidermis/epithelium, often due to inflammation or estrogen deficiency

**Bulla** (*plural bullae*) – Also known as blister, a circumscribed lesion >1cm in diameter that contains clear, serous, or hemorrhagic liquid

**Crust** – Dried serum, blood, or pus on the skin surface, usually adherent, yielding a rough skin texture

**Cyst** – A closed cavity lined by epithelium that contains fluid or semisolid material

**Demarcation** – Transition from normal to lesional skin; lesions may be well-, moderately-, or poorly-demarcated

**Depigmentation** – Complete loss of melanocytes, as seen in vitiligo

**Desquamation** – Shedding or peeling off of layers of epidermis or epithelium

**Ecchymosis** (*plural ecchymoses*) – Non-blanching red to purple macules or patches resulting from intradermal hemorrhage

**Edema** – An abnormal infiltration and excess accumulation of serous fluid in connective tissue seen as a poorly marginated area of swelling; edema may be skin-colored, pink, or red

**Erosion** – Shallow defect in the skin surface usually seen as a pink to red shiny well-demarcated lesion; does not breach the dermis/stroma

**Excoriation** – A skin defect caused by scratching or exogenous injury, often linear or angular

**Fissure** – A linear disruption of stratum corneum that may extend into epidermis and dermis

**Fusion** – Joining of structures that previously were separate, often applied to midline adherence of labia minora

**Hyperkeratosis** – Thickening of the stratum corneum usually leading to a rough surface, used clinically to describe white-gray to yellow plaques of variable demarcation

**Hyperpigmentation** – Increased production of melanin or presence of other pigments leading to darker lesional skin

**Hypopigmentation** – Reduced melanocytes causing paler lesional skin

**Lesion** – A visible or palpable abnormality

**Lichenification** – Accentuation of skin markings, often due to rubbing or scratching

**Maceration** – Skin breakdown due to excessive exposure to moisture, prone to sloughing

**Macule** – A flat, circumscribed, nonpalpable lesion that differs in color from the surrounding skin that may be any color or shape, in some jurisdictions this refers to size  $\leq 1$  cm with 'patch' referring to larger lesions

**Modified mucous membranes** – A term encompassing areas of hairless skin and mucocutaneous junction including periclitoral structures, glans clitoris, and labia minora; with reference to the mouth this term describes the lips

**Mucous membranes** – A term encompassing areas of non-keratinized squamous epithelium at the vestibule and the vagina; with reference to the mouth this term describes the oral mucosa

**Nodule** – An elevated, solid, palpable lesion >1cm usually located primarily in the dermis and/or subcutis, often hemispherical or poorly marginated

**Obliteration** – Total loss of anatomic landmarks due to adhesions, often refers to a non-patent vagina or absence of labial and periclitoral structures

**Pallor** – Paler skin color compared to an individual's non-lesional skin

**Papule** – An elevated, solid, palpable lesion  $\leq$  1cm in diameter

**Patch** – A flat, circumscribed, nonpalpable lesion that differs in color from the surrounding skin that may be any color or shape

**Petechiae** – <2mm red-purple or brown non-blanching flat lesions resulting from capillary leakage or thrombocytopenia

**Plaque** – >1cm elevated, palpable, and flat-topped area of variable color

**Pigmented lesion** – Dark skin lesion with color due to melanin, blood, or foreign pigments; categorized into melanocytic or vascular lesions

**Post-inflammatory pigment alteration (*hyper- or hypopigmentation*)** – Increased or decreased production or abnormal accumulation of melanin in the epidermis/epithelium resulting from previous inflammation, may be temporary or persistent

**Purpura** – Red to purple flat or raised lesions resulting from intradermal hemorrhage

**Pustule** – A small elevated area of skin containing pus

**Resorption** – Encompasses both diminution of the labia minora and/or clitoral hood and their adherence to apposed structures producing a flattened appearance of vulvar anatomy

**Scale** – A visible accumulation of keratin, forming a flat plate or flake

**Telangiectasia** – Visible dilated superficial capillaries

**Ulcer** – Skin defect involving full-thickness loss of epidermis/epithelium and at least part of dermis/stroma, may extend into subcutaneous tissue

**Vesicle** – A circumscribed lesion  $\leq$ 1cm in diameter that contains clear, serous, or hemorrhagic fluid

## Dermatopathologic terminology

**Acantholytic tissue reaction** – Tissue reaction pattern characterized by loss of adhesion between keratinocytes relating to a failure of cell junctions; seen in vesiculobullous disorders and some forms of neoplasia



**Acanthosis** – Increased thickness of the epithelium due to proliferation of squamous cells, may be flat or have enlarged rete ridges of variable morphology

**Acanthotic tissue reaction** – Tissue reaction pattern characterized by increased thickness of the epidermis, often with irregular elongation and enlargement of rete ridges

**Basal layer damage** – Evidence of lymphocyte-mediated damage to the bottom layer of epidermis/epithelium seen as apoptotic bodies, vacuolar change, and squamatization

**Basement membrane** – Thin layer of extracellular matrix proteins that sits between the epidermis/epithelium and the dermal/stromal connective tissue

**Dermis** – The connective tissue layer under the epidermis that contains blood vessels, nerves, glands, hair follicles, and other adnexal structures

**Epidermis** – Keratinized epithelium, eg, skin; consists of a basal layer, spiny layer, granular layer, and horny layer (stratum corneum)

**Erosion** – Absence of some or all of the epidermis/epithelium down to the basement membrane with intact dermis/stroma, usually accompanied by intraepithelial neutrophils

**Excoriation** – Loss of epidermis/epithelium and part of dermis/stroma caused by scratching or injury, often linear or angular

**Exocytosis** – Migration of white blood cells into the epidermis/epithelium

**Fibrosis** – Deposition of collagen fibers in thick bundles as occurs in healing wounds or in response to chronic inflammation

**Granulomatous reaction** – Inflammatory reaction pattern containing collections of epithelioid histiocytes due to indigestible antigen (lipoprotein) as may be seen in tuberculosis, fungal infection, Crohn's disease, and foreign body

**Hair bearing skin** – Keratinized skin that contains hair follicles, found at mons pubis, labia majora, lateral perineum, and perianus

**Hairless skin** – Keratinized skin without hair follicles, found at the prepuce, labia minora, central perineum, and anal verge; these areas are also described as modified mucous membranes

**Hematoxylin and eosin (H&E)** – Standard stain of histopathology slides yielding shades of pink and blue

**Hyalinized** – The appearance of closely-packed fine collagen fibers within the dermis/stroma, also described as 'ground glass' or 'sclerosis'

**Hypergranulosis** – Increased thickness of the granular cell layer, usually accompanies hyperkeratosis and acanthosis

**Hypogranulosis** – Reduced thickness or near-absence of the granular cell layer, usually accompanies parakeratosis

**Hyperkeratosis** – Increased thickness of compact keratin of stratum corneum

**Keratin** – Protein filaments within non-viable anucleated keratinocytes, in combination with a lipid matrix comprises the stratum corneum

**Lichenoid dermatitis** – A clinicopathologic term for a dermatosis suggestive of LS or lichen planus (LP) with a biopsy result of lichenoid tissue reaction that lacks specific features of LS or LP

**Lichenoid tissue reaction** – Tissue reaction pattern characterized by basal layer damage accompanied by a band-like closely adherent lymphocytic infiltrate, used interchangeably with ‘interface dermatitis’

**Lichenification** – Increased thickness of the epidermis at all layers accompanied by vertically-oriented papillary dermal fibrosis resulting from chronic scratching or rubbing

**Melanosis** – Clinicopathologic term for brown to black lesion(s), usually at hairless skin and non-keratinized squamous epithelium, often with poorly defined borders and inhomogeneous color, usually due to increased pigment production in the setting of normal numbers of melanocytes

**Mucocutaneous junction** – The transition between hairless skin and non-keratinized squamous epithelium that often shows thin parakeratosis; at the vestibule this corresponds to Hart’s line

**Mycosis** – Skin infection with yeasts (eg *Candida albicans*) or dermatophytes (eg *Trichophyton rubrum*)

**Non-keratinized squamous epithelium** – Present at the vagina and vestibule medial to Hart’s line, also called squamous mucosa or mucous membranes

**Parakeratosis** – Retained nucleation of keratinocytes in the stratum corneum; normal at the mucocutaneous junction but a sign of abnormal maturation at other sites

**Papillary process** – Upwards projection of dermis/stroma that is the inverse to a rete ridge, involved in adherence between skin and underlying connective tissue

**Periodic acid-Schiff (PAS)** – Standard stain of histopathology slides yielding shades of magenta, helpful to assess mycosis, presence of glycogen, and prominence of the basement membrane

**Psoriasisiform tissue reaction** – Tissue reaction pattern characterized by increased thickness of the epidermis, often with regular elongation and enlargement of rete ridges

**Rete ridge** – Downwards projection of epidermis/epithelium that is the inverse to a papillary process, involved in adherence between skin and underlying connective tissue

**Sclerosis** – Closely packed fine collagen fibers yielding a homogeneously pink ‘ground glass’ stromal appearance on H&E staining

**Spongiosis** – Intercellular edema seen as clear spaces between keratinocytes, manifests as increased prominence of desmosomes

**Spongiotic tissue reaction** – Tissue reaction pattern demonstrating intercellular edema, lymphocyte exocytosis, and a perivascular infiltrate, characteristic of dermatitis

**Squamization** – Change from small cuboidal cells of the basal layer to horizontally-oriented cells that have a more mature squamous cell appearance

**Stratum corneum** – The outermost layer of epidermis

**Stroma** – The connective tissue layer under non-keratinized squamous epithelium that contains blood vessels, nerves, glands, and other adnexal structures

**Ulcer** – Skin defect involving loss of full-thickness epidermis/epithelium and underlying dermis/stroma

**Verruciform** – Wart-like appearance due to acanthosis and irregular surface with papilliform projections

