

Alopecia areata update

Part I. Clinical picture, histopathology, and pathogenesis

Abdullah Alkhalifah, MD,^a Adel Alsantali, MD,^a Eddy Wang, BSc,^a Kevin J. McElwee, PhD,^a
and Jerry Shapiro, MD^{a,b}
Vancouver, British Columbia, Canada, and New York, New York

Alopecia areata (AA) is an autoimmune disease that presents as nonscarring hair loss, although the exact pathogenesis of the disease remains to be clarified. Disease prevalence rates from 0.1% to 0.2% have been estimated for the United States. AA can affect any hair-bearing area. It often presents as well demarcated patches of nonscarring alopecia on skin of overtly normal appearance. Recently, newer clinical variants have been described. The presence of AA is associated with a higher frequency of other autoimmune diseases. Controversially, there may also be increased psychiatric morbidity in patients with AA. Although some AA features are known poor prognostic signs, the course of the disease is unpredictable and the response to treatment can be variable. Part one of this two-part series on AA describes the clinical presentation and the associated histopathologic picture. It also proposes a hypothesis for AA development based on the most recent knowledge of disease pathogenesis. (J Am Acad Dermatol 2010;62:177-88.)

Learning objectives: After completing this learning activity, participants should be familiar with the most recent advances in AA pathogenesis, recognize the rare and recently described variants of AA, and be able to distinguish between different histopathologic stages of AA.

Key words: alopecia areata; alopecia totalis; alopecia universalis; nonscarring alopecia; pathology; pathogenesis.

DEMOGRAPHICS

Key point

- Alopecia areata affects all age groups and different ethnicities, with equal sex distribution

Alopecia areata (AA) occurs in populations worldwide. It is a common disease encountered by dermatologists, with a frequency ranging from 0.7% to 3.8% of patients attending dermatology clinics.^{1,2} In the United States, AA was estimated to occur in 0.1% to 0.2% of the general population,³ with a lifetime risk of 1.7%.⁴ Overall, AA likely affects males and females equally.⁵ Some studies show a significant male preponderance in the adult age group, although others identify contrasting results.^{6,7}

From the Department of Dermatology and Skin Science,^a University of British Columbia, Vancouver, and the Department of Dermatology,^b New York University.

Funding sources: None.

Conflicts of interest: Dr Shapiro is a consultant for Johnson and Johnson Inc. Drs Shapiro and McElwee are cofounders of TrichoScience Innovations Inc. The other authors, editors, and peer reviewers have no relevant financial relationships.

Reprint requests: Jerry Shapiro, MD, University of British Columbia Skin Care Center, 835 W 10th Ave, Vancouver, BC, V5Z 4E8, Canada. E-mail: jerry.shapiro@vch.ca.

0190-9622/\$36.00

© 2009 by the American Academy of Dermatology, Inc.

doi:10.1016/j.jaad.2009.10.032

Abbreviations used:

AA:	alopecia areata
APC:	antigen presenting cell
APS:	autoimmune polyglandular syndrome
AT:	alopecia totalis
AU:	alopecia universalis
CD4/8:	cluster of differentiation 4/8
DEBR:	Dundee experimental bald rat
HLA:	human leukocyte antigen
HPA:	hypothalamic-pituitary-adrenal
MHC:	major histocompatibility complex
SCID:	severe combined immunodeficient
TE:	telogen effluvium

Pediatric AA constitutes approximately 20% of AA cases,⁸ and as many as 60% of patients with AA will present with their first patch before 20 years of age.⁹ One study suggests that 85.5% of Asian patients with AA have disease onset before 40 years of age.² The disease prevalence peaks between the second and fourth decades of life.¹⁰

CLINICAL PICTURE

Key points

- AA classically presents as asymptomatic, well defined patches of nonscarring alopecia with no overt epidermal changes

- **Patches can be mildly reddened or peachy in color**
- **Acute diffuse and total alopecia is a new variant of AA with favorable prognosis**

AA can occur on virtually any hair-bearing area, but it affects the scalp in approximately 90% of cases seen in dermatology clinics.⁵ The disease can be classified based on the extent or pattern of the hair loss.^{11,12}

The hair loss can present as single delimited patches of hair loss (most common), multiple patches, or extensive hair loss. Based on the extent of hair loss, the disease is clinically classified as follows: patchy AA, in which there is a partial loss of scalp hair (Fig 1); alopecia totalis (AT), in which 100% of scalp hair is lost (Fig 2); or alopecia universalis (AU), in which there is a 100% loss of all scalp and body hair. Approximately 5% of cases will progress to AT/AU.¹³

The pattern of hair loss observed in AA can vary considerably, and less common presentations can be observed in a minority of patients, including reticular patches of hair loss; ophiasis type, band-like hair loss in parieto-temporo-occipital area (Fig 3); ophiasis inversus (sisapho), very rare band-like hair loss in the fronto-parieto-temporal area (Fig 4); and a diffuse thinning over part or all of the scalp. Another variant that should be considered is acute diffuse and total alopecia, which was first described by Sato-Kawamura et al¹⁴ and was reported more recently by Lew et al¹⁵ in a larger series of patients with similar characteristics. This new variant is characterized by its rapid progression and extensive involvement, along with a favorable prognosis.

Classic AA lesions are well demarcated, round or oval, completely bald, smooth-surfaced patches (Fig 5).¹¹ The skin within the patch is usually normal on the first examination; however, it is not uncommon to see a slightly peachy¹¹ (Fig 6) or reddened¹⁰ color. A characteristic finding that is frequently seen in (or at the border of) the patches is "exclamation mark hairs."⁵ These are short hairs that are tapered proximally and wider distally (Fig 7). In active disease, where alopecia patches are expanding, a hair pull test may be positive at the periphery of lesions.¹¹ An interesting feature of AA is its initial sparing of white hairs in patients with graying hair.¹⁰ However, eventually white hair is also often lost as

the disease duration becomes chronic. Initial hair regrowth, whether spontaneous or induced by treatment, is typically non- or hypopigmented (Fig 8), but the color usually returns with time.¹⁰ The disease is frequently asymptomatic, although a few patients report pruritus, burning sensations, or pain before hair loss begins.¹¹

The use of videodermoscopy with a magnification of 20 to 70 times may be a valuable, noninvasive tool in equivocal AA cases. The presence of numerous yellow dots and short regrowing hairs is suggested to be a characteristic feature.^{16,17} Yellow dots, however, can also be seen in androgenic alopecia.¹⁸ Close examination of the hair shafts at the edge of lesions, particularly exclamation mark hairs, may reveal subtle defects in the structure and cuticle.¹⁹

CAPSULE SUMMARY

- Alopecia areata pathogenesis is not fully understood.
- A new variant of alopecia areata with a favorable prognosis was recently described.
- The histopathologic picture varies depending on the stage of disease and, in the absence of classic inflammation, it can be puzzling to the inexperienced dermatopathologist.

DIFFERENTIAL DIAGNOSIS

Key points

- **Trichotillomania and tinea capitis are the most important differential diagnoses in children**
- **Diffuse AA can be easily misdiagnosed as telogen effluvium**

In children, the most important entities to rule out are tinea capitis and trichotillomania. Tinea capitis can be differentiated by the presence of inflammation or at least mild scaling. Trichotillomania may involve irregular or bizarrely shaped lesions. The presence of broken hairs with varying lengths gives lesions a rough texture, unlike the smooth surface of AA. The differentiation of diffuse AA from telogen effluvium (TE) can be challenging. The patient's history may reveal a triggering factor that may point towards a diagnosis of TE. In diffuse AA, the hair pull test may show some dystrophic anagen hairs compared to the pure telogen hairs found in TE. Ultimately, a scalp biopsy may be required to correctly differentiate diffuse AA and TE. Lupus and secondary syphilis may also be considered in the differential diagnosis of AA and may require serology testing or a scalp biopsy for confirmation. Where a strong family association of universal hair loss is observed, the differential diagnosis may include a rare inherited genetic hair loss condition called congenital atrichia.²⁰

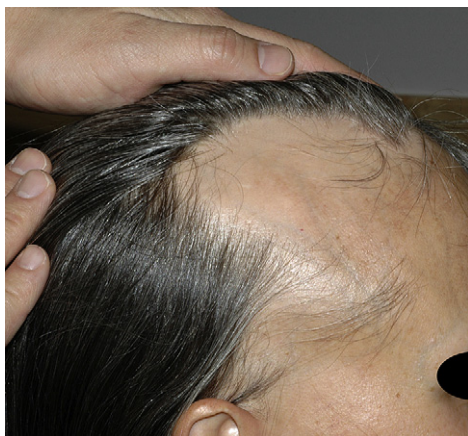

Fig 1. Patchy alopecia areata in the right frontotemporal area. Note eyebrow involvement.

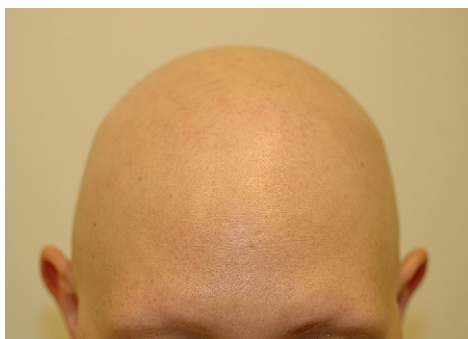

Fig 2. Alopecia totalis with a 100% loss of scalp hair.

PROGNOSIS

Key points

- **The extent of AA involvement is probably the most important prognostic factor**
- **In AT/AU, the chance of full recovery is less than 10%**

The course of AA is unpredictable. Up to 50% of patients will recover within 1 year even without treatment.¹² However, most patients will have more than one episode of hair loss. The most important factors indicating a poor prognosis are the extent of hair loss presentation (extensive AA/AT/AU)²¹ or an ophiasis pattern of hair loss.¹⁵ Other factors associated with a poor prognosis include a long duration of hair loss,¹⁵ atopy, a positive family history, the presence of other autoimmune diseases, nail involvement, and young age of first onset.¹¹ In children, the disease may have a tendency towards worsening with time, even if the initial presentation was mild.²¹ In AT/AU, the chance of full recovery is less than 10%.²²

ASSOCIATED ABNORMALITIES

Key points

- **AA can be associated with nail changes in as many as 66% of patients**

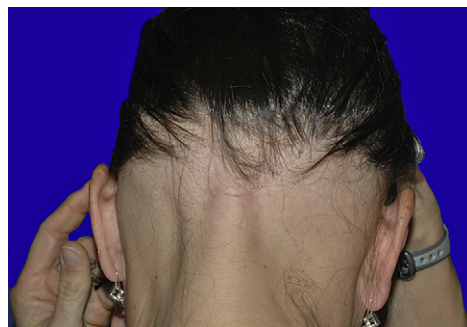

Fig 3. Ophiasis pattern of alopecia areata.

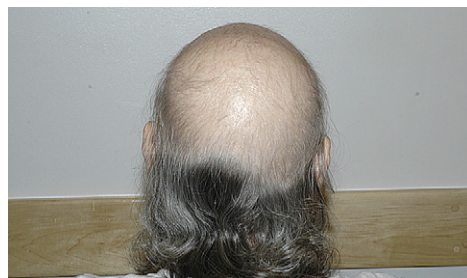

Fig 4. Ophiasis inversus (sisapho), a rare variant that can mimic male pattern hair loss.

- **Autoimmune diseases, particularly thyroiditis, are the most significant association**
- **The presence of such abnormalities is one of the poor prognostic factors**
- **Other reported abnormalities include psychiatric and asymptomatic ophthalmologic changes**

Nail involvement may be observed in AA, with a reported frequency ranging from 7% to 66%.²³ Nail pitting is the most common nail abnormality observed.^{23,24} Other abnormalities include trachyonychia, Beau lines, onychorhexis, thinning or thickening, onychomadesis, koilonychia, punctate or transverse leukonychia, and red spotted lunulae.¹¹ Nails can be affected before, concurrent with, or after the resolution of hair loss. Several studies have suggested that nail abnormalities are associated with more extensive hair loss.^{23,24}

AA can be found in association with other autoimmune diseases. Thyroid autoimmunity is probably the main association, with an incidence between 8% and 28%.²⁵ The presence of thyroid autoantibodies has no clinical correlation with AA severity.²⁶ Vitiligo may be another important association, with a 3% to 8% incidence in AA patients compared to a prevalence of 1% in the US population.²⁷ Atopy is twice as common in AA patients compared with the general population.²⁷ Other diseases and genetic disorders

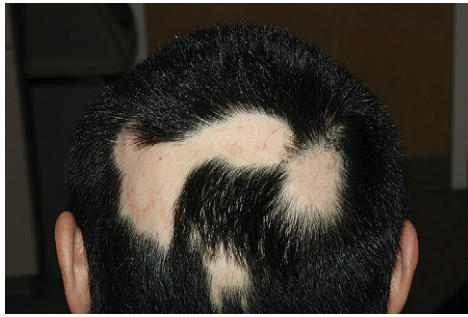

Fig 5. Well-demarcated, smooth-surfaced patches of alopecia areata.

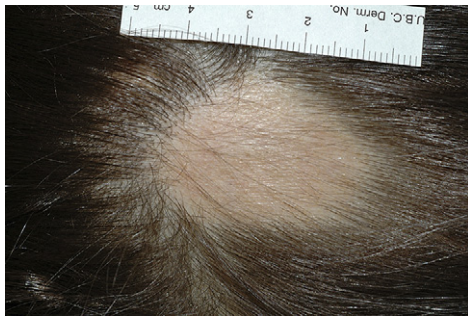

Fig 6. Alopecia areata can present with peach colored patches. Note the color difference between the involved and uninvolved hair bearing scalp.

reported to be associated with AA include Down syndrome, Addison disease, autosomal recessive autoimmune polyglandular syndrome (APS-1) (chronic hypoparathyroidism-mucocutaneous candidiasis-autoimmune adrenal insufficiency), pernicious anemia, psoriasis, lupus, celiac disease, ulcerative colitis, and multiple sclerosis. These less common autoimmune diseases are more likely to be associated with AT/AU.²⁸ There may be an increased risk of type 1 diabetes in family members of AA patients; in contrast, the patients themselves may have a reduced incidence compared to the general population.²⁹

There may be a high psychiatric morbidity in AA, especially anxiety and mood disturbance.³⁰ In one report, ophthalmologic findings such as asymptomatic lens opacities and fundus changes occurred in 51% and 41% of AA patients, respectively.³¹

INVESTIGATIONS

Key point

- **Routine testing is not indicated in AA**

Routine screening for autoimmune disease (thyroid disease in particular) is not generally indicated because of insufficient clinical evidence.³² Older patients, patients with long disease duration,

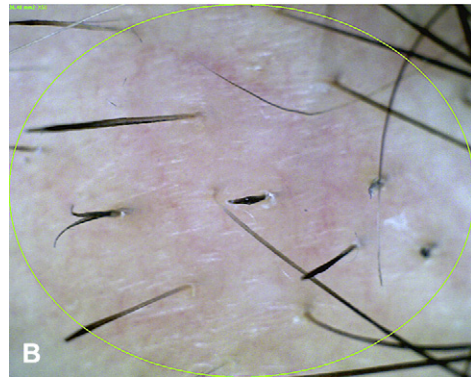
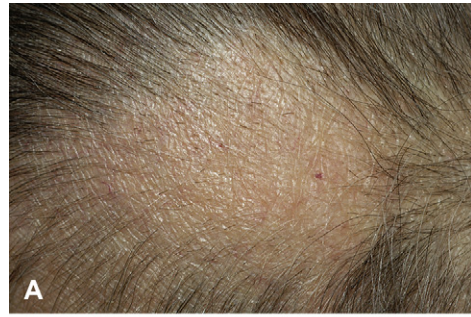
Fig 7. **A,** Close view showing multiple exclamation mark hairs. **B,** Exclamation mark hairs seen under Folliscope examination (Sometch Inc, Seoul, Korea). (Original magnification, $\times 50$.)

females, patients with persistent patchy AA (as compared to transient patchy AA), and patients with AT/AU have been found to more likely have thyroid abnormalities.²⁸ However, because AA severity and thyroid disease are neither correlated nor causal, routine thyroid testing is not recommended at our center.

Potassium hydroxide, fungal culture, lupus serology, syphilitic screening, and a scalp biopsy may be necessary in ambiguous or difficult to diagnose cases. However, most presentations of AA are obvious, and further laboratory tests are not indicated in the vast majority of cases.

PATHOLOGY

Key points

- **The histopathologic picture varies depending on disease duration**
- **A peribulbar lymphocytic infiltrate “swarm of bees” characterizes the acute phase of AA**
- **In subacute cases, large numbers of catagen and telogen hairs will be present**
- **Hair follicle miniaturization with minimal or no inflammation is seen in chronic cases**

There is abnormal hair cycling in AA. Anagen follicles may enter telogen prematurely, or some may survive for some time in a dystrophic anagen state.³³

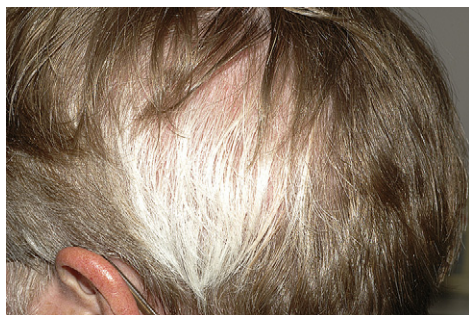

Fig 8. White hair regrowth after one session of intralosomal triamcinolone acetonide.

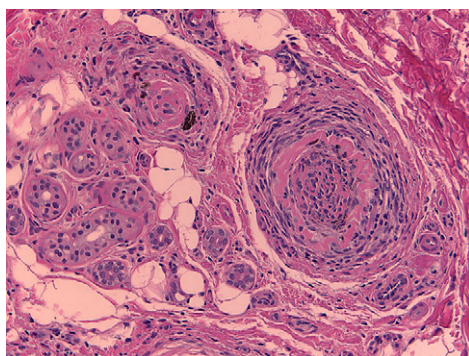


Fig 9. Classic peribulbar "swarm of bees" inflammation in alopecia areata. Some eosinophils are present within the infiltrate. (Hematoxylin–eosin stain; original magnification: $\times 20$.)

Consequently, the histopathologic appearance of AA varies depending on disease duration.³⁴ However, increased numbers of eosinophils can be present in regions of AA affected skin in any stage of AA and are a useful diagnostic feature.^{35,36}

In the acute stage, a peribulbar lymphocytic infiltrate "swarm of bees" preferentially targets anagen stage follicles (Fig 9).³⁴ The infiltrate is composed of both CD4⁺ and CD8⁺ cells with the CD4⁺/CD8⁺ ratio being higher in clinically active disease.³⁷ As a consequence, edema, microvesiculation, apoptosis, necrosis, macrophages, and foreign body giant cells can be seen in and around the affected hair follicles.³⁸ The root sheaths and hair matrix are infiltrated by lymphocytes and there may be hair follicle pigment incontinence, keratinocyte cell necrosis, and vacuolar damage.^{5,39} Focal matrix cell vacuolization and necrosis, a relatively uncommon event, is claimed to be a characteristic feature of AA.⁴⁰ Ultrastructural studies showed that keratinocytic degeneration may affect layers of matrix cells in AA, unlike the apoptosis of scattered outer root sheath cells in normal catagen.⁴¹ Anagen arrest, shortly followed by catagen, weakens the hair shaft and causes breakage at the surface of the skin. As the follicle goes into telogen,

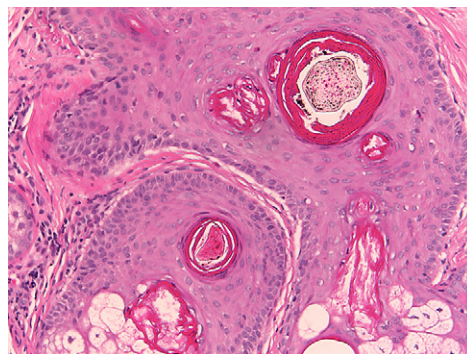


Fig 10. Abnormal hair shaft formation (trichomalacia): a sign of active alopecia areata. (Hematoxylin–eosin stain; original magnification: $\times 20$.)

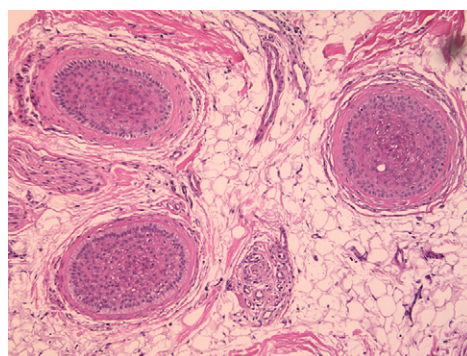


Fig 11. Catagen transformation in subacute alopecia areata. (Hematoxylin–eosin stain; original magnification: $\times 20$.)

the fractured widened tip will further extrude, resulting in the typical exclamation point hair.³⁸ Trichomalacia (Fig 10) with marked narrowing of the hair shafts ("pencil point hair") results in fragile hairs that fall from the scalp in great numbers.⁴⁰

In the subacute stage, large numbers of catagen hairs, followed by telogen hairs, can be observed.³⁸ The percentage of catagen/telogen is markedly increased (Fig 11) and often exceeds 50% of the total follicles.⁴⁰ Some remnant inflammation may persist in or around fibrous streamers as the follicles ascend to telogen level.³⁸

In the chronic stage, there is marked hair follicle miniaturization (Fig 12). The terminal to vellus scalp hair follicle ratio is reduced and is likely to be 1:1.³⁸ These miniaturized anagen follicles are situated slightly deeper than normal vellus follicles.⁴⁰ Chronic lesions are characterized by the presence of nanogen follicles (an intermediate stage between terminal and vellus anagen; Fig 13).⁵ Nonsclerotic fibrous tracts (streamers) extend along the original site of the previous terminal follicles into the subcutis.³⁴ The inflammatory infiltrate, if present, is likely to be in the papillary dermis around miniaturized follicles.³⁸

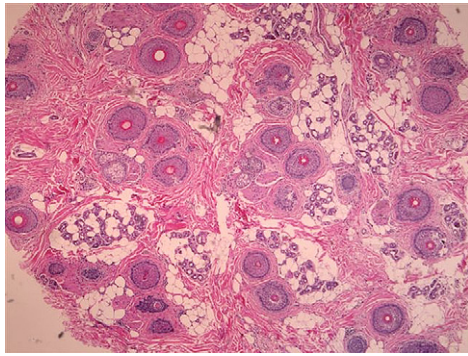


Fig 12. Marked miniaturization: a feature of long-standing alopecia areata. (Hematoxylin–eosin stain; original magnification: $\times 4$.)

In the recovery stage, the terminal to vellus ratio reverts to normal, the percentage of anagen hairs increases, and there is little or no inflammation.³⁸ The total number of follicles are normal or decreased in AA compared to normal scalp.^{40,42}

ALOPECIA AREATA PATHOGENESIS

Key points

- AA is a lymphocyte cell–mediated inflammatory form of hair loss with research evidence suggesting an underlying autoimmune etiopathogenesis
- The development of hair loss involves aberrant modulation of the hair growth cycle, resulting in dystrophic anagen hair follicles and/or increased frequency of telogen state follicles
- Genetic susceptibility to the development of AA involves specific alleles of the HLA region though other non-HLA genes are also likely to be involved
- Susceptibility to the development of AA may be modified by environmental factors, including exposure to proinflammatory agents and possibly other modulators, including stress and diet

Hair follicle growth cycling modulation in alopecia areata

There are three key phases of the hair cycle: the growth phase (anagen), the regression phase (catagen), and the resting phase (telogen).⁴³ The cycling of these phases is finely coordinated by the expression of hormones, cytokines, transcription factors, and their corresponding receptors and is carefully regulated through endocrine, paracrine, and autocrine routes. The disruption of these finely tuned pathways can result in the development of hair diseases. Exogen is a hair follicle cycle event that describes the controlled shedding of club hair fibers.

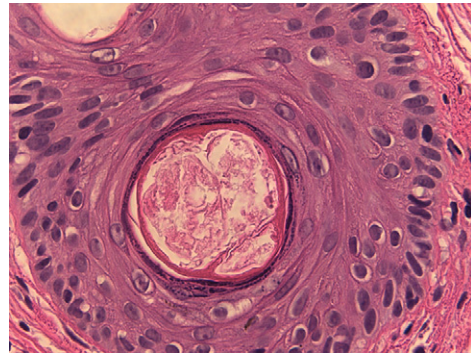


Fig 13. Nanogen follicle (intermediate stage, between terminal and vellus anagen) is very typical of alopecia areata. (Hematoxylin–eosin stain; original magnification: $\times 60$.)

In healthy individuals, shedding normally occurs during the subsequent anagen growth phase as a new hair fiber is produced. In the development of alopecias, exogen occurs in advance of renewed anagen growth, leaving a hair follicle devoid of visible hair fiber—a state called kenogen.⁴⁴

In AA, significant disruption of the hair growth cycle clearly occurs, but different perturbations in hair growth occur depending on the pattern, severity, and duration of AA in each patient. There are several possible presentations of AA. First, the anagen phase of a hair follicle can become inflamed and maintained in a dystrophic anagen state, unable to produce hair fiber of significant size or integrity.⁴⁵ When there is a greater intensity of inflammation, the hair follicles may be forced into a telogen phase and may then cycle through multiple anagen–telogen phases of brief duration. Correspondingly, inflammatory cell infiltration occurs in early anagen follicles without migration to draining lymph nodes as follicles capitate and return to telogen.^{43,45} Finally, when AA is chronic, the hair follicles tend to persist in a prolonged telogen phase without an apparent attempt to return to an anagen growth phase (Fig 14).^{38,43,45}

Autoimmune activity in alopecia areata

The pathogenesis of AA and the molecular mechanisms that lead to hair loss are poorly understood. In the past, AA was believed to be of infectious or neurotrophic origin.⁴⁶ Recent research studies have indicated that AA is an inflammation-driven disease and is likely an autoimmune disorder.^{47–49} Circumstantial evidence in support of an autoimmune mechanism underlying AA comes from several sources. The association of AA with other autoimmune diseases has been reported.²⁵ The presence of inflammatory lymphocytes around and within affected hair follicles and the ability to promote hair regrowth with the use of immunosuppressive agents

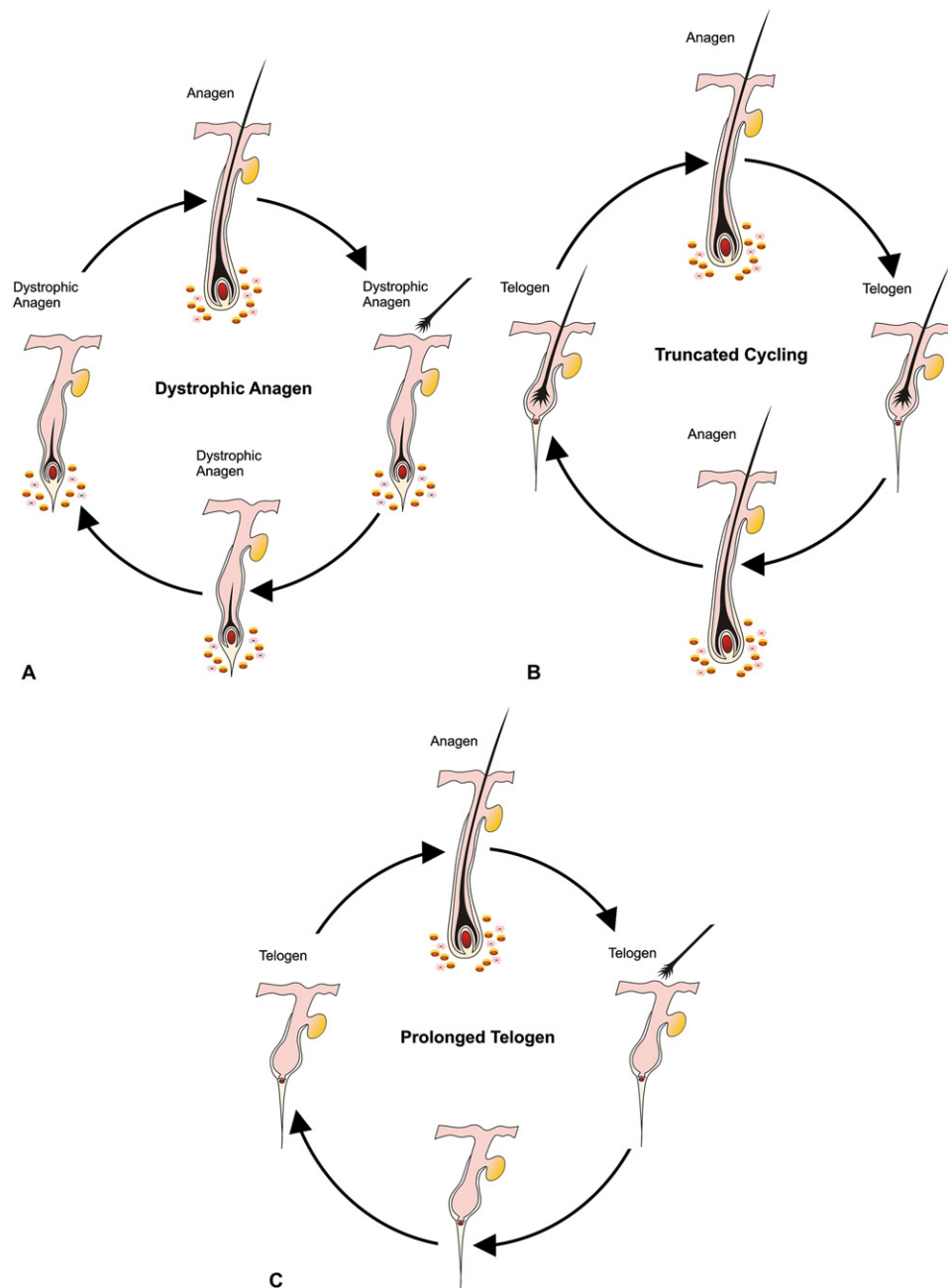


Fig 14. Hair growth cycle patterns in alopecia areata. **A**, Hair follicles held in dystrophic anagen by mild inflammatory insult unable to produce significant hair fiber. **B**, Anagen growth phases truncated by moderate inflammatory insult resulting in rapid cycling and brief hair fiber growth. **C**, Hair follicles enter prolonged telogen dormancy with development of chronic alopecia areata.

is consistent with an autoimmune hypothesis.⁵⁰ The infiltration of antigen presenting cells (APCs) such as macrophages and Langerhans cells both around and within the dystrophic hair follicles has also been observed.⁴⁷ This is potentially consistent with a response to autoantigens within the hair follicles and attraction of these APCs.

A major proinflammatory event in AA is suggested to be the abnormal expression of class I and II major histocompatibility complex antigens in hair follicle epithelia.⁵⁰ There is also an increase in proinflammatory markers such as intercellular cell adhesion molecule and endothelial cell selectin in the blood vessels around the hair follicles. The presence of hair

follicle-specific IgG autoantibodies in the peripheral blood of AA patients also further reinforces the hypothesis that the development of AA could be autoimmune related.⁴⁷

Animal models of alopecia areata

Two inbred rodent models have been developed for use in AA research: the Dundee experimental bald rat (DEBR) and the C3H/HeJ mouse.^{45,51,52} These two models have shown AA to be an autosomal polygenic trait with incomplete penetrance. By studying the breeding patterns of C3H/HeJ mice, it was found that the segregation pattern of the AA phenotype is under the control of one or more dominant gene alleles.⁴⁵ In C3H/HeJ mice, AA develops after 4 months in females and 10 months in males and affects up to 20% of a colony.^{47,53} DEBR females develop AA after 5 to 8 months; DEBR males develop AA in 7 to 10 months. More than 40% of a DEBR colony will be affected, and the condition is more likely to affect females than males with a 3:1 ratio.⁵² Both rodent models express an AA phenotype as multifocal sites of hair loss, often with symmetrical distribution.^{51,52} Histologically, the skin of mice and rats shows an infiltration of CD4⁺ and CD8⁺ T cells, macrophages, and dendritic cells in and around the hair follicles.⁵⁴

Functional studies in animal models further support the notion of AA as an autoimmune disease and provide information on the mechanisms of AA development. AA can be transferred from spontaneously affected mice to healthy mice with an almost 100% success rate by using a skin grafting technique.⁵⁵ This allows the study of AA with predictable onset and progression. The grafting of affected skin promotes an induction of anagen stage hair follicle inflammation in a skin graft recipient. This infiltration is progressive over time and begins several weeks in advance of hair loss onset.⁵⁶ Infiltration of the hair follicles and inhibition of AA onset can be blocked by targeting activated lymphocyte markers or by blocking costimulatory receptors.^{57,58}

When AA affected mouse skin is grafted to severe combined immunodeficient (SCID) mice, in the absence of CD4⁺ and CD8⁺ T cells, hair regrowth is observed in grafted skin and no loss of hair is observed in the host skin.⁵⁵ This is a strong indication that CD4⁺ and CD8⁺ T cells are directly involved in the hair loss promotion mechanism. Further, partial restoration of hair growth is observed by depleting CD4⁺ or CD8⁺ T cell subsets by using monoclonal antibodies in AA affected DEBR and C3H/HeJ mice.^{47,59,60} Most significantly, subcutaneous injection into normal haired mice of lymphocyte cell subsets isolated from AA affected mice shows that

these cells induce the disease. CD8⁺ cells quickly induced localized patches of hair loss. CD4⁺ cells did not induce local hair loss, but they were shown to activate the host's immune system to promote multiple AA patches after several weeks. It was concluded that CD8⁺ cells are the direct modulators of hair loss while CD4⁺ cells play a classic "helper" role in AA onset.⁶¹

A further SCID-human mouse model has been developed. AA affected human skin regrows hair after grafting to SCID mice. Using a cell transfer method, hair loss can be reinduced by injecting patient CD4⁺ and CD8⁺ T cells into the human skin graft.⁶² To successfully reinduce AA, the cells must be previously activated in vitro using antigenic peptides which may or may not reflect the natural in vivo disease mechanism. All of these disease models have significantly helped in understanding the pathogenesis of AA, and they should prove invaluable in the development of new treatments⁶³ and understanding the mechanisms by which current treatments are effective.^{64,65}

Role of genetics in alopecia areata

The genetics of an individual can play a role in the development of AA. That AA can be inherited is based on observations on monozygotic twins; AA in twins can have similar times of onset and patterns of hair loss.^{66,67} Some patients with AA have a strong family history that spans many generations, and this also suggests that AA can be inherited. Between 4% and 28% of patients who have AA will have at least one other affected family member.⁴⁸

Gene association studies have indicated that human leukocyte antigen (HLA) genes play a role in AA and multiple HLA class I (A, B, and C) alleles conferring susceptibility have been identified in different cohorts of AA patients.⁴⁷ MHC (HLA) class I molecules are present on almost all nucleated cells and they present antigens to CD8⁺ T cells. There is an aberrant expression of HLA antigens found within the follicles of AA affected patients.⁵⁰ However, the evidence in support of an association of HLA class I with AA is inconsistent with different susceptibility alleles identified in different cohorts, while some studies were unable to confirm any significant association.⁶⁸

A much more consistent and stronger association between HLA class II alleles and AA development has been observed. HLA class II antigens are constitutively expressed on specific immune cells and may be upregulated on nonimmune cells in response to injury. They are responsible for presenting antigenic peptides to CD4⁺ T cells. HLA class II antigens are aberrantly highly expressed on AA affected hair

follicles. Specific alleles, such as DQB1*03 and DRB1*1104, have been reported as markers for susceptibility to AA.⁶⁹ These findings suggest the importance of specific HLA class II alleles in the onset and progression of AA and imply that antigen presentation to CD4⁺ cells plays a significant role in AA development. Several association studies have investigated non-HLA gene alleles, indicating that multiple genes may contribute to AA susceptibility.⁴⁶

Genome-wide screening for AA susceptibility loci has been challenging. Linkage analysis with the AA mouse model revealed that AA is a complex polygenic trait.⁷⁰ Four intervals (Alaa1, 2, 3, and 4) on mouse chromosomes 17, 9, 8, and 15, respectively, were identified as regions of the genome conferring AA susceptibility.⁷⁰ Mouse gene associations were found comparable to those in humans. In particular, the equivalent MHC region in mice (Alaa1) was strongly associated with AA susceptibility. Studies to identify the specific susceptibility genes within these regions are underway.

A genome-wide study was completed on extended human families with multiple AA patients. Intervals on human chromosomes 6, 10, 16, and 18 were identified as potential AA susceptibility loci.⁷¹ This study further confirmed that the HLA region on human chromosome 6 is associated with genetic susceptibility to AA. However, there was at least one significant genetic determinant of AA found at 6q.23.3 outside of the HLA gene cluster. Large scale, genome-wide screens using the AA registry and DNA bank⁷² are nearing completion and should provide significant new information on the potential gene activity in AA development beyond the HLA region.

Environmental impact on alopecia areata

Environmental factors may also contribute to AA development. Specific gene alleles might provide an innate degree of susceptibility to AA for an individual, but environmental factors likely cumulatively determine the actual onset, hair loss pattern, and severity of the disease.^{47,68} However, the exact environmental stimuli required for AA expression are yet to be determined. Hormonal fluctuation,⁶⁸ infectious agents,⁷³ and vaccinations⁷⁴ have all been cited as possible triggers for AA. In the mouse model, dietary soy oil increases resistance to AA development, suggesting that diet might also play a role in AA susceptibility.⁵⁶ It is likely that there are many potential environmental inputs with different factors involved in AA development for different individuals.

Stress is commonly cited as a cause for AA onset, but controlled clinical studies have been inconclusive.⁷⁵⁻⁷⁷ Some did not find a significant correlation of hair loss onset with stressful life events,⁷⁸⁻⁸⁰ while

others confirm stressful events in AA patients before the onset of disease.^{30,79,81} In contrast, several studies have shown that individuals with AA are more likely to exhibit aberrant psychosocial traits, such as increased anxiety, depression, and aggression.^{76,78,80,82} Investigations on the skin of mice and humans have indicated increased presence of multiple factors associated with stress mediation.^{83,84} In a mouse model study, the development of AA was strongly associated with higher central and peripheral hypothalamic-pituitary-adrenal (HPA) tone.⁸⁵ The AA affected mice had a significantly blunted systemic HPA response to acute physiologic stress and a decreased habituation response to constant psychological stress. Taken together, AA may impact stress responses and HPA activity may be significantly involved in modulating the severity or course of AA.

Hypothesis for alopecia areata development

Although many hypotheses to explain autoimmune disease development have been suggested by immunologists,⁸⁶⁻⁸⁹ most of these scenarios have not been seriously considered in the context of AA. Currently, AA development hypotheses focus on hair follicle immune privilege collapse or the inappropriate presentation of antigens to the immune system during normal hair follicle cycling. Anagen stage hair follicles retain immune privilege, and a breach in immune privilege and exposure of unique hair follicle antigens may result in targeting by the skin immune system.⁹⁰⁻⁹² This popular hypothesis is highly “skin-centric” and largely ignores current immunologic dogma, although it is attractive in its simplicity.

An alternative hypothesis is based on the knowledge that hair follicle immunoprotection is transient, limited to the anagen growth cycle stage. Regression of the hair follicle in catagen involves significant apoptosis⁹³ and immune cell infiltration.⁹⁴⁻⁹⁷ This normal hair follicle cycling event may continuously expose the immune system to low levels of hair follicle-derived antigens. Hair follicle-specific autoantibodies found in humans and animal models in the absence of AA⁹⁸⁻¹⁰⁰ may be a consequence of this constant low level exposure.

Langerhans cells and dendritic cells are capable of presenting cell apoptosis-derived antigens to lymphocytes and stimulating autoimmunity.¹⁰¹⁻¹⁰³ If catagen regression became disordered, the associated immune cell infiltrate might inappropriately coexpress antigenic peptides and costimulatory molecules and induce an immunologic response.^{47,56} Mouse studies have revealed that significant proinflammatory events occur in the lymph nodes in

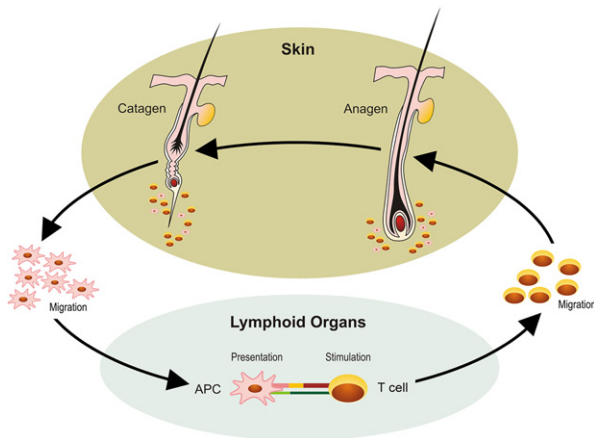


Fig 15. Alopecia areata pathogenesis. Inappropriate excitation of antigen presenting cells during disordered catagen and migration of cells to draining lymph nodes may lead to hair follicle antigen-specific lymphocyte activation, migration, and infiltration of anagen stage hair follicles.

advance of lymphocyte infiltration into the skin and subsequent hair loss onset.^{56,57,104} As such, the onset of AA may be initially triggered during routine catagen because of inappropriate skin immune system signaling (Fig 15).

SUMMARY

Classic AA presents as well defined, completely bald patches without changes in the skin's color or surface. AA is usually a clinical diagnosis and a skin biopsy is generally not required. However, rare patterns and variants can be challenging to diagnose. There is insufficient evidence to support routine blood testing in AA. While there are some prognostic factors, the course of the disease is unpredictable. The histopathologic picture varies according to the stage of AA and can be difficult to recognize. Despite continuing research, the exact pathogenesis of AA is still to be clarified. However, the best available evidence supports an autoimmune targeting of hair follicles.

The authors would like to thank Magdalena Martinka, MD, for providing the histopathologic images.

REFERENCES

- Sharma VK, Dawn G, Kumar B. Profile of alopecia areata in Northern India. *Int J Dermatol* 1996;35:22-7.
- Tan E, Tay YK, Goh CL, Chin Giam Y. The pattern and profile of alopecia areata in Singapore—a study of 219 Asians. *Int J Dermatol* 2002;41:748-53.
- Safavi K. Prevalence of alopecia areata in the First National Health and Nutrition Examination Survey. *Arch Dermatol* 1992;128:702.
- Safavi KH, Muller SA, Suman VJ, Moshell AN, Melton LJ 3rd. Incidence of alopecia areata in Olmsted County, Minnesota, 1975 through 1989. *Mayo Clin Proc* 1995;70:628-33.
- Wasserman D, Guzman-Sanchez DA, Scott K, McMichael A. Alopecia areata. *Int J Dermatol* 2007;46:121-31.
- Kyriakis KP, Paltatzidou K, Kosma E, Sofouri E, Tadros A, Rachioti E. Alopecia areata prevalence by gender and age. *J Eur Acad Dermatol Venereol* 2009;23:572-3.
- Kavak A, Yesildal N, Parlak A, Gokdemir G, Aydogan I, Anul H, et al. Alopecia areata in Turkey: demographic and clinical features. *J Eur Acad Dermatol Venereol* 2008;22:977-81.
- Nanda A, Al-Fouzan AS, Al-Hasawi F. Alopecia areata in children: a clinical profile. *Pediatr Dermatol* 2002;19:482-5.
- Price VH. Alopecia areata: clinical aspects. *J Invest Dermatol* 1991;96:68S.
- de Berker DAR, Messenger AG, Sinclair RD. Disorders of hair. In: Burns DA, Breathnach SM, Cox N, Griffiths CE, editors. *Rook's textbook of dermatology*. Vol. 4. 7th ed Oxford: Wiley-Blackwell; 2004 p. 63.1-63.120.
- Madani S, Shapiro J. Alopecia areata update. *J Am Acad Dermatol* 2000;42:549-66.
- Shapiro J, Madani S. Alopecia areata: diagnosis and management. *Int J Dermatol* 1999;38(suppl 1):19-24.
- Price VH. Therapy of alopecia areata: on the cusp and in the future. *J Invest Dermatol Symp Proc* 2003;8:207-11.
- Sato-Kawamura M, Aiba S, Tagami H. Acute diffuse and total alopecia of the female scalp. A new subtype of diffuse alopecia areata that has a favorable prognosis. *Dermatology* 2002;205:367-73.
- Lew BL, Shin MK, Sim WY. Acute diffuse and total alopecia: a new subtype of alopecia areata with a favorable prognosis. *J Am Acad Dermatol* 2009;60:85-93.
- Tosti A, Whiting D, Iorizzo M, Pazzaglia M, Misciali C, Vincenzi C, et al. The role of scalp dermoscopy in the diagnosis of alopecia areata incognita. *J Am Acad Dermatol* 2008;59:64-7.
- Ross EK, Vincenzi C, Tosti A. Videodermoscopy in the evaluation of hair and scalp disorders. *J Am Acad Dermatol* 2006;55:799-806.
- Rakowska A, Slowinska M, Kowalska-Oledzka E, Olszewska M, Czuwara J, Rudnicka L. Alopecia areata incognita: true or false? *J Am Acad Dermatol* 2009;60:162-3.
- Tobin DJ, Fenton DA, Kendall MD. Ultrastructural study of exclamation-mark hair shafts in alopecia areata. *J Cutan Pathol* 1990;17:348-54.
- Zlotogorski A, Panteleyev AA, Aita VM, Christiano AM. Clinical and molecular diagnostic criteria of congenital atrichia with papular lesions. *J Invest Dermatol* 2002;118:887-90.
- Tosti A, Bellavista S, Iorizzo M. Alopecia areata: a long term follow-up study of 191 patients. *J Am Acad Dermatol* 2006;55:438-41.
- Walker SA, Rothman S. A statistical study and consideration of endocrine influences. *J Invest Dermatol* 1950;14:403-13.
- Gandhi V, Baruah MC, Bhattacharaya SN. Nail changes in alopecia areata: incidence and pattern. *Indian J Dermatol Venereol Leprol* 2003;69:114-5.
- Kasumagic-Halilovic E, Prohic A. Nail changes in alopecia areata: frequency and clinical presentation. *J Eur Acad Dermatol Venereol* 2009;23:240-1.
- Seyrafi H, Akhiani M, Abbasi H, Mirpour S, Gholamrezaezhad A. Evaluation of the profile of alopecia areata and the prevalence of thyroid function test abnormalities and serum auto-antibodies in Iranian patients. *BMC Dermatol* 2005;5:11.
- Kasumagic-Halilovic E. Thyroid autoimmunity in patients with alopecia areata. *Acta Dermatovenerol Croat* 2008;16:123-5.
- Hordinsky M, Ericson M. Autoimmunity: alopecia areata. *J Invest Dermatol Symp Proc* 2004;9:73-8.

28. Goh C, Finkel M, Christos PJ, Sinha AA. Profile of 513 patients with alopecia areata: associations of disease subtypes with atopy, autoimmune disease and positive family history. *J Eur Acad Dermatol Venereol* 2006;20:1055-60.
29. Wang SJ, Shohat T, Vadheim C, Shellow W, Edwards J, Rotter JI. Increased risk for type I (insulin-dependent) diabetes in relatives of patients with alopecia areata (AA). *Am J Med Genet* 1994;51:234-9.
30. Ruiz-Doblado S, Carrizosa A, García-Hernández MJ. Alopecia areata: psychiatric comorbidity and adjustment to illness. *Int J Dermatol* 2003;42:434-7.
31. Recupero SM, Abdolrahimzadeh S, De Dominicis M, Mollo R, Carboni I, Rota L, et al. Ocular alterations in alopecia areata. *Eye* 1999;13(pt 5):643-6.
32. MacDonald Hull SP, Wood ML, Hutchinson PE, Sladden M, Messenger AG. British Association of Dermatologists. Guidelines for the management of alopecia areata. *Br J Dermatol* 2003;149:692-9.
33. Messenger AG, Slater DN, Bleehen SS. Alopecia areata: alterations in the hair growth cycle and correlation with the follicular pathology. *Br J Dermatol* 1986;114:337-47.
34. Weedon D. Diseases of cutaneous appendages. In: Weedon D, editor. *Weedon's skin pathology*. London: Churchill Livingstone; 2002.
35. Elston DM, McCollough ML, Bergfeld WF, Liranzo MO, Heibel M. Eosinophils in fibrous tracts and near hair bulbs: a helpful diagnostic feature of alopecia areata. *J Am Acad Dermatol* 1997;37:101-6.
36. El Darouti M, Marzouk SA, Sharawi E. Eosinophils in fibrous tracts and near hair bulbs: a helpful diagnostic feature of alopecia areata. *J Am Acad Dermatol* 2000;42:305-7.
37. Todes-Taylor N, Turner R, Wood GS, Stratte PT, Morhenn VB. T cell subpopulations in alopecia areata. *J Am Acad Dermatol* 1984;11(2 pt 1):216-23.
38. Whiting DA. Histopathologic features of alopecia areata: a new look. *Arch Dermatol* 2003;139:1555-9.
39. Tobin DJ. Morphological analysis of hair follicles in alopecia areata. *Microsc Res Tech* 1997;38:443-51.
40. Sperling LC. Alopecia areata. In: Sperling LC, editor. *An atlas of hair pathology with clinical correlations*. 1st ed New York: Parthenon Publishing; 2003. pp. 109-38.
41. Tobin DJ, Fenton DA, Kendall MD. Cell degeneration in alopecia areata. An ultrastructural study. *Am J Dermatopathol* 1991;13:248-56.
42. Whiting DA. Histopathology of alopecia areata in horizontal sections of scalp biopsies. *J Invest Dermatol* 1995;104(suppl 5) 26S-7S.
43. Vogt A, McElwee KJ, Blume-Peytavi U. Biology of the hair follicle. In: Whiting DA, Blume-Peytavi U, Tosti A, editors. *Hair growth and disorders*. Berlin: Springer; 2008. pp. 1-22.
44. McElwee KJ, Sinclair R. Hair physiology and its disorders. *Drug Discovery Today: Disease Mechanisms* 2008;5: e163-71.
45. Freyschmidt-Paul P, McElwee KJ, Hoffmann R. Alopecia areata. In: Whiting DA, Blume-Peytavi U, Tosti A, editors. *Hair growth and disorders*. Berlin: Springer; 2008. pp. 311-32.
46. King LE Jr, McElwee KJ, Sundberg JP. Alopecia areata. *Curr Dir Autoimmun* 2008;10:280-312.
47. Lu W, Shapiro J, Yu M, Barekatin A, Lo B, Finner A, et al. Alopecia areata: pathogenesis and potential for therapy. *Expert Rev Mol Med* 2006;8:1-19.
48. McDonagh AJ, Tazi-Ahnni R. Epidemiology and genetics of alopecia areata. *Clin Exp Dermatol* 2002;27:405-9.
49. Paus R, Slominski A, Czarnetzki BM. Is alopecia areata an autoimmune-response against melanogenesis-related proteins, exposed by abnormal MHC class I expression in the anagen hair bulb? *Yale J Biol Med* 1993;66:541-54.
50. McElwee KJ, Tobin DJ, Bystryrn JC, King LE Jr, Sundberg JP. Alopecia areata: an autoimmune disease? *Exp Dermatol* 1999;8:371-9.
51. Sundberg JP, McElwee KJ, Whiting DA, King LE Jr. Alopecia areata: spontaneous and skin graft-induced mouse models. In: Chan LS, editor. *Animal models of human inflammatory skin diseases*. Vol V. Boca Raton, FL: CRC Press; 2003. pp. 429-50.
52. McElwee KJ. Alopecia areata: spontaneous rat model of alopecia areata. In: Chan LS, editor. *Animal models of human inflammatory skin diseases*. Vol V. Boca Raton, FL: CRC Press; 2003. pp. 451-68.
53. Sundberg JP, Cordy WR, King LE Jr. Alopecia areata in aging C3H/HeJ mice. *J Invest Dermatol* 1994;102:847-56.
54. Zhang JG, Oliver RF. Immunohistological study of the development of the cellular infiltrate in the pelage follicles of the DEBR model for alopecia areata. *Br J Dermatol* 1994;130:405-14.
55. McElwee KJ, Boggess D, King LE Jr, Sundberg JP. Experimental induction of alopecia areata-like hair loss in C3H/HeJ mice using full-thickness skin grafts. *J Invest Dermatol* 1998;111: 797-803.
56. McElwee KJ, Silva K, Boggess D, Bechtold L, King LE Jr, Sundberg JP. Alopecia areata in C3H/HeJ mice involves leukocyte-mediated root sheath disruption in advance of overt hair loss. *Vet Pathol* 2003;40:643-50.
57. Carroll JM, McElwee KJ, King LE Jr, Byrne MC, Sundberg JP. Gene array profiling and immunomodulation studies define a cell-mediated immune response underlying the pathogenesis of alopecia areata in a mouse model and humans. *J Invest Dermatol* 2002;119:392-402.
58. Freyschmidt-Paul P, Seiter S, Zoller M, König A, Ziegler A, Sundberg JP, et al. Treatment with an anti-CD44v10-specific antibody inhibits the onset of alopecia areata in C3H/HeJ mice. *J Invest Dermatol* 2000;115:653-7.
59. McElwee KJ, Spiers EM, Oliver RF. Partial restoration of hair growth in the DEBR model for alopecia areata after in vivo depletion of CD4+ T cells. *Br J Dermatol* 1999;140:432-7.
60. McElwee KJ, Spiers EM, Oliver RF. In vivo depletion of CD8+ T cells restores hair growth in the DEBR model for alopecia areata. *Br J Dermatol* 1996;135:211-7.
61. McElwee KJ, Freyschmidt-Paul P, Hoffmann R, Kissling S, Hummel S, Vitacolonna M, et al. Transfer of CD8(+) cells induces localized hair loss whereas CD4(+)/CD25(-) cells promote systemic alopecia areata and CD4(+)/CD25(+) cells blockade disease onset in the C3H/HeJ mouse model. *J Invest Dermatol* 2005;124:947-57.
62. Gilhar A, Landau M, Assy B, Shalaginov R, Serafimovich S, Kalish RS. Mediation of alopecia areata by cooperation between CD4+ and CD8+ T lymphocytes: transfer to human scalp explants on Prkdc(scid) mice. *Arch Dermatol* 2002;138: 916-22.
63. Sun J, Silva KA, McElwee KJ, King LE Jr, Sundberg JP. The C3H/HeJ mouse and DEBR rat models for alopecia areata: review of preclinical drug screening approaches and results. *Exp Dermatol* 2008;17:793-805.
64. Zoller M, Gupta P, Marhaba R, Vitacolonna M, Freyschmidt-Paul P. Anti-CD44-mediated blockade of leukocyte migration in skin-associated immune diseases. *J Leukoc Biol* 2007;82: 57-71.
65. Marhaba R, Vitacolonna M, Hildebrand D, Baniyash M, Freyschmidt-Paul P, Zoller M. The importance of myeloid-derived suppressor cells in the regulation of autoimmune

- effector cells by a chronic contact eczema. *J Immunol* 2007;179:5071-81.
66. Stankler L. Synchronous alopecia areata in two siblings: a possible viral aetiology. *Lancet* 1979;1:1303-4.
 67. Alsaleh QA, Nanda A, al-Hasawi F, el-Kashlan M. Concurrent appearance of alopecia areata in siblings. *Pediatr Dermatol* 1995;12:285-6.
 68. McElwee K, Freyschmidt-Paul P, Ziegler A, Happle R, Hoffmann R. Genetic susceptibility and severity of alopecia areata in human and animal models. *Eur J Dermatol* 2001;11:11-6.
 69. Akar A, Arca E, Erbil H, Akay C, Sayal A, Gur AR. Antioxidant enzymes and lipid peroxidation in the scalp of patients with alopecia areata. *J Dermatol Sci* 2002;29:85-90.
 70. Sundberg JP, Silva KA, Li R, Cox GA, King LE Jr. Adult-onset alopecia areata is a complex polygenic trait in the C3H/HeJ mouse model. *J Invest Dermatol* 2004;123:294-7.
 71. Martinez-Mir A, Zlotogorski A, Gordon D, Petukhova L, Mo J, Gilliam TC, et al. Genomewide scan for linkage reveals evidence of several susceptibility loci for alopecia areata. *Am J Hum Genet* 2007;80:316-28.
 72. Duvic M, Norris D, Christiano A, Hordinsky M, Price V. Alopecia areata registry: an overview. *J Invest Dermatol Symp Proc* 2003;8:219-21.
 73. Rodriguez TA, Duvic M. Onset of alopecia areata after Epstein-Barr virus infectious mononucleosis. *J Am Acad Dermatol* 2008;59:137-9.
 74. Ikeda T. Produced alopecia areata based on the focal infection theory and mental motive theory. *Dermatologica* 1967;134:1-11.
 75. Brauner GJ, Goodheart HP. Dermatologic care behind bars. *J Am Acad Dermatol* 1988;18:1066-73.
 76. Gupta MA, Gupta AK, Watteel GN. Stress and alopecia areata: a psychodermatologic study. *Acta Derm Venereol* 1997;77:296-8.
 77. Perini GI, Veller Fornasa C, Cipriani R, Bettin A, Zecchino F, Peserico A. Life events and alopecia areata. *Psychother Psychosom* 1984;41:48-52.
 78. Brajac I, Tkalic M, Dragojevic DM, Gruber F. Roles of stress, stress perception and trait-anxiety in the onset and course of alopecia areata. *J Dermatol* 2003;30:871-8.
 79. Gulec AT, Tanriverdi N, Duru C, Saray Y, Akcali C. The role of psychological factors in alopecia areata and the impact of the disease on the quality of life. *Int J Dermatol* 2004;43:352-6.
 80. Picardi A, Pasquini P, Cattaruzza MS, Gaetano P, Baliva G, Melchi CF, et al. Psychosomatic factors in first-onset alopecia areata. *Psychosomatics* 2003;44:374-81.
 81. Kakourou T, Karachristou K, Chrousos G. A case series of alopecia areata in children: impact of personal and family history of stress and autoimmunity. *J Eur Acad Dermatol Venereol* 2007;21:356-9.
 82. Liakopoulou M, Alifieraki T, Katideniou A, Kakourou T, Tselalidou E, Tsiantis J, et al. Children with alopecia areata: psychiatric symptomatology and life events. *J Am Acad Child Adolesc Psychiatry* 1997;36:678-84.
 83. Siebenhaar F, Sharov AA, Peters EM, Sharova TY, Syska W, Mardaryev AN, et al. Substance P as an immunomodulatory neuropeptide in a mouse model for autoimmune hair loss (alopecia areata). *J Invest Dermatol* 2007;127:1489-97.
 84. Toyoda M, Makino T, Kagoura M, Morohashi M. Expression of neuropeptide-degrading enzymes in alopecia areata: an immunohistochemical study. *Br J Dermatol* 2001;144:46-54.
 85. Zhang X, Yu M, Yu W, Weinberg J, Shapiro J, McElwee KJ. Development of alopecia areata is associated with higher central and peripheral hypothalamic-pituitary-adrenal tone in the skin graft induced C3H/HeJ mouse model. *J Invest Dermatol* 2009;129:1527-38.
 86. Theofilopoulos AN. The basis of autoimmunity: part II. Genetic predisposition. *Immunol Today* 1995;16:150-9.
 87. Theofilopoulos AN. The basis of autoimmunity: part I. Mechanisms of aberrant self-recognition. *Immunol Today* 1995;16:90-8.
 88. Goodnow CC, Sprent J, Fazekas de St Groth B, Vinuesa CG. Cellular and genetic mechanisms of self tolerance and autoimmunity. *Nature* 2005;435:590-7.
 89. Goodnow CC. Multistep pathogenesis of autoimmune disease. *Cell* 2007;130:25-35.
 90. Paus R, Nickoloff BJ, Ito T. A "hairy" privilege. *Trends Immunol* 2005;26:32-40.
 91. Ito T, Meyer KC, Ito N, Paus R. Immune privilege and the skin. *Curr Dir Autoimmun* 2008;10:27-52.
 92. Ito T, Ito N, Bettermann A, Tokura Y, Takigawa M, Paus R. Collapse and restoration of MHC class-I-dependent immune privilege: exploiting the human hair follicle as a model. *Am J Pathol* 2004;164:623-34.
 93. Botchkareva NV, Ahluwalia G, Shander D. Apoptosis in the hair follicle. *J Invest Dermatol* 2006;126:258-64.
 94. Weedon D, Stratton G. Apoptosis as the mechanism of the involution of hair follicles in catagen transformation. *Acta Derm Venereol* 1981;61:335-9.
 95. Lindner G, Botchkarev VA, Botchkareva NV, Ling G, van der Veen C, Paus R. Analysis of apoptosis during hair follicle regression (catagen). *Am J Pathol* 1997;151:1601-17.
 96. Eichmuller S, van der Veen C, Moll I, Hermes B, Hofmann U, Muller-Rover S, et al. Clusters of perifollicular macrophages in normal murine skin: physiological degeneration of selected hair follicles by programmed organ deletion. *J Histochem Cytochem* 1998;46:361-70.
 97. Parakkal PF. Role of macrophages in collagen resorption during hair growth cycle. *J Ultrastruct Res* 1969;29:210-7.
 98. McElwee KJ, Pickett P, Oliver RF. The DEBR rat, alopecia areata and autoantibodies to the hair follicle. *Br J Dermatol* 1996;134:55-63.
 99. Tobin DJ, Sundberg JP, King LE Jr, Boggess D, Bystryjn JC. Autoantibodies to hair follicles in C3H/HeJ mice with alopecia areata-like hair loss. *J Invest Dermatol* 1997;109:329-33.
 100. Tobin DJ, Orentreich N, Fenton DA, Bystryjn JC. Antibodies to hair follicles in alopecia areata. *J Invest Dermatol* 1994;102:721-4.
 101. Ueno H, Klechevsky E, Morita R, Asford C, Cao T, Matsui T, et al. Dendritic cell subsets in health and disease. *Immunol Rev* 2007;219:118-42.
 102. Albert ML, Sauter B, Bhardwaj N. Dendritic cells acquire antigen from apoptotic cells and induce class I-restricted CTLs. *Nature* 1998;392:86-9.
 103. Mehling A, Beissert S. Dendritic cells under investigation in autoimmune disease. *Crit Rev Biochem Mol Biol* 2003;38:1-21.
 104. Zoller M, McElwee KJ, Engel P, Hoffmann R. Transient CD44 variant isoform expression and reduction in CD4(+)/CD25(+) regulatory T cells in C3H/HeJ mice with alopecia areata. *J Invest Dermatol* 2002;118:983-92.