
Alopecia areata update

Part II. Treatment

Abdullah Alkhalifah, MD,^a Adel Alsantali, MD,^a Eddy Wang, BSc,^a Kevin J. McElwee, PhD,^a
and Jerry Shapiro, MD^{a,b}
Vancouver, British Columbia, Canada, and New York, New York

Various therapeutic agents have been described for the treatment of alopecia areata (AA), but none are curative or preventive. The aim of AA treatment is to suppress the activity of the disease. The high rate of spontaneous remission and the paucity of randomized, double-blind, placebo-controlled studies make the evidence-based assessment of these therapies difficult. The second part of this two-part series on AA discusses treatment options in detail and suggests treatment plans according to specific disease presentation. It also reviews recently reported experimental treatment options and potential directions for future disease management. (J Am Acad Dermatol 2010;62:191-202.)

Learning objectives: After completing this learning activity, participants should be able to compare the efficacy and safety of various treatment options, formulate a treatment plan tailored to individual patients, and recognize recently described treatments and potential therapeutic approaches.

Key words: biologics; corticosteroids; immunotherapy; intralesional; minoxidil; phototherapy.

A Cochrane review has shown that few therapies for alopecia areata (AA) have been comprehensively evaluated in randomized controlled trials.¹ The lack of good evidence-based data for therapeutic approaches is a challenge to the dermatologist in choosing efficacious AA treatments. Indeed, the Cochrane review concluded that there were no validated treatments for AA. However, it is notable that the Cochrane review considered intra-control “half-head” topical treatment studies as unable to fit the current criteria for high quality evidence-based medicine and discounted many studies of this type. We suggest that such trials can provide good evidence in support of a treatment with appropriate randomization, blinding, and objective evaluation of hair growth responses.

Abbreviations used:

AA:	alopecia areata
AT:	alopecia totalis
AU:	alopecia universalis
DNCB:	dinitrochlorobenzene
DPCP:	diphenylcyclopropenone
IFN- γ :	interferon gamma
IL:	interleukin
ILCS:	intralesional corticosteroids
NAAF:	National Alopecia Areata Foundation
PUVA:	psoralen plus ultraviolet A light phototherapy
SADBE:	squaric acid dibutylester
SALT:	Severity of Alopecia Tool
SP:	substance P
SSRI:	selective serotonin reuptake inhibitor
TNF:	tumor necrosis factor

The precise definition of a good response to treatment in AA is variable between trials and omitted in others. In order to increase the reliability, objectivity, and comparability of AA clinical trials, investigational assessment guidelines have been recommended by a group of leading investigators/clinicians experienced in clinical trials and/or in the clinical care of patients with AA.² As a primary endpoint, the Severity of Alopecia Tool (SALT) score seems to be ideal for investigators, subjects, and expert review panels to use. Patient assessments of the outcomes and a quality of life scale may also be useful and give additional information on subject appreciation of the efficacy of any treatment for AA. Most recently, software for the analysis of digital

From the Department of Dermatology and Skin Science,^a University of British Columbia, Vancouver, and the Department of Dermatology,^b New York University.

Funding sources: None.

Conflicts of interest: Dr Shapiro is a consultant for Johnson and Johnson Inc. Drs Shapiro and McElwee are cofounders of TrichoScience Innovations Inc. The other authors, editors, and peer reviewers have no relevant financial relationships.

Reprint requests: Jerry Shapiro, MD, University of British Columbia Skin Care Center, 835 W 10th Ave, Vancouver, BC, V5Z 4E8, Canada. E-mail: jerry.shapiro@vch.ca.

0190-9622/\$36.00

© 2009 by the American Academy of Dermatology, Inc.

doi:10.1016/j.jaad.2009.10.031

dermatoscopic images has been developed that allows for objective measurements of hair growth caliber and density. These new tools could significantly improve our evaluation of hair loss treatments.

INTRALESIONAL CORTICOSTEROIDS

Key points

- **Intralesional corticosteroids are the treatment of choice for adults**
- **The authors' preference is triamcinolone acetate 5mg/mL to the scalp and 2.5mg/mL to the face every 4 to 6 weeks**
- **Treatment should be stopped if there is no improvement after 6 months**

Although intralesional corticosteroids (ILCSs) have been used in the treatment of AA for about 50 years, there are no published randomized controlled trials.^{1,3} Hair regrowth has been reported in 71% of patients with subtotal AA treated by triamcinolone acetate injections three times every 2 weeks, and in 7% of control subjects injected with isotonic saline.⁴ Porter and Burton⁵ showed that hair regrowth was possible in 64% and 97% of AA sites treated by intralesional injections of triamcinolone acetate and its less soluble derivative triamcinolone hexacetonide, respectively.

For adult patients with less than 50% scalp involvement, ILCSs, preferably triamcinolone acetate, are considered first-line therapy. Concentrations of 2.5 to 10 mg/mL may be used, but 5 mg/mL (maximum volume, 3 mL) is the preferred concentration used by the authors. For the eyebrows and face, 2.5 mg/mL can be used (0.5 mL to each eyebrow). Every 4 to 6 weeks, triamcinolone acetate is injected intradermally with a 0.5-in long 30-gauge needle as multiple 0.1-mL injections at 1-cm intervals.

Side effects include transient atrophy and telangiectasia, which can be prevented by the use of smaller volumes, minimizing the number of injections per site, and avoiding too superficial (intraepidermal) injections. Optional topical anesthetic can be applied 30 to 60 minutes before treatment to minimize pain from the injections. This is particularly useful when treating the pediatric population. If there is no

improvement after 6 months of treatment, ILCSs should be stopped. The decreased expression of thioredoxin reductase 1 in the outer root sheath may be the cause for glucocorticoid resistance in some AA patients.⁶

TOPICAL CORTICOSTEROIDS

Key points

- **Topical midpotent corticosteroids are the treatment of choice in children**
- **The authors combine topical corticosteroids with minoxidil 5%**

Different forms of topical corticosteroids have been used to treat AA, with varying degrees of efficacy. In a randomized, double-blinded, placebo-controlled trial using desoximetasone cream 0.25%, the complete regrowth rates in the active and control groups were 57.6% and 39.2%, respectively.⁷ These results were not statistically significant when compared with placebo.

For mild to moderate AA (<26% hair loss), a multicenter prospective, randomized, controlled, investigator-blinded trial showed a more than 75% hair regrowth rate in 61% of patients using 0.1% betamethasone valerate foam in comparison with 27% in the 0.05% betamethasone dipropionate lotion group.⁸

In a study of unilateral application of 0.05% clobetasol propionate ointment under occlusion in alopecia totalis (AT)/alopecia universalis (AU) patients, Tosti et al⁹ showed that 28.5% of patients had almost complete hair regrowth and 17.8% of patient had long-term benefit on the treated side. In another randomized, double-blind, placebo-controlled trial, 47% of 0.05% clobetasol propionate foam-treated patients had greater than 25% hair regrowth, and 25% of participants had hair regrowth greater than 50%.¹⁰

Folliculitis was observed in 39% of clobetasol propionate ointment-treated patients in comparison to 6% of patients treated with 0.05% clobetasol propionate foam. Telangiectasia and skin atrophy rarely developed. The relapse rate varies from 37% to 63% after topical corticosteroid treatment has stopped and even with continuation of therapy.^{9,11}

CAPSULE SUMMARY

- The management of alopecia areata varies widely among dermatologists.
- There is a paucity of randomized, double-blind, placebo-controlled trials for alopecia areata treatment.
- No treatment has been shown to alter the course of the disease or to have a significant long-term benefit compared to placebo according to evidence-based assessment.
- Intracontrol half-head studies indicate that contact sensitizing agents are effective for the management of extensive alopecia areata.
- This article suggests a practical approach to alopecia areata management based on the best available evidence.

Minoxidil

Key point

- **Minoxidil 5% is mainly used as adjuvant treatment to conventional therapy**

Minoxidil (2, 4-diamino-6-piperidinopyrimidine-3-oxide) was initially developed as an antihypertensive therapy. Although minoxidil has been used as a hair regrowing treatment for more than 20 years, its mode of action is not fully understood. Many mechanisms of action have been proposed, including vasodilatation,^{12,13} angiogenesis,¹⁴ enhanced cell proliferation,^{15,16} and potassium channel opening.^{17,18} There are some reports indicating that minoxidil also has some immunosuppressive effects.^{19,20}

In a double-blind, placebo-controlled trial of 3% topical minoxidil in extensive AA, Price et al²¹ showed hair regrowth in 63.6% and 35.7% in the treated and placebo groups, respectively. However, cosmetically acceptable hair growth was seen only in 27.3% of the minoxidil-treated subjects. A dose-response efficacy was shown in a study comparing 1% and 5% topical minoxidil in the treatment of patients with extensive AA (hair loss >75%). The response rates were 38% and 81% with 1% and 5% topical minoxidil, respectively.²² Topical minoxidil is far less effective in AT and AU.^{22,23} At the University of British Columbia Hair Clinic, 5% topical minoxidil is frequently combined with other therapeutic options as an adjunctive treatment.

Contact dermatitis can occur in 6% of patients using 5% minoxidil solution.²⁴ Because minoxidil 5% foam does not contain propylene glycol (a potential irritant), the incidence of pruritus with it is much reduced compared to the 5% minoxidil solution (1.1% vs 6%).²⁵ Hypertrichosis (facial hair growth) has been a reported side effect in 3% of patients.²⁶

Anthralin

Key points

- **Anthralin 0.5% to 1% short contact therapy is used as alternative treatment**
- **Mild irritation should develop in order for it to work**
- **Anthralin should not be combined with corticosteroids**
- **Treatment may be stopped if there is no improvement after 3 months**

There are a few uncontrolled case series assessing anthralin efficacy in the treatment of AA. Schmoeckel et al²⁷ showed response rates of 75% in patchy AA patients and 25% in AT patients. However, other trials have shown less successful results. Others report that 25% of patients achieved a cosmetic response with 0.5% to 1% anthralin cream.²⁸

The mechanism of anthralin action is unknown, but in mouse studies anthralin has been shown to decrease the expression of tumor necrosis factor- α (TNF- α) and - β (TNF- β) in the treated area in comparison to vehicle-treated sites.²⁹ Anthralin 1% cream can be applied as a short contact therapy initially for 20 to 30 minutes daily; the contact time is then increased gradually by 10 minutes at 2-week intervals up to 1 hour or until a low grade dermatitis reaction develops. Then the daily therapy at this exposure time is continued for 3 months. Anthralin should produce a mild irritant reaction in order to be effective.³⁰ If there is no response by 3 months, treatment most likely will be unsuccessful and may be stopped.^{28,31}

Adverse effects to anthralin include severe irritation, folliculitis, regional lymphadenopathy, and staining of skin, clothes, and fair hair.^{27,31,32} Patients should avoid eye contact with this chemical and the treated area should be protected from the sun.

TOPICAL IMMUNOTHERAPY

Key points

- **Diphenylcyclopropenone (DPCP) is the treatment of choice for adults with more than 50% scalp involvement**
- **Sensitization with DPCP 2% is followed by weekly application of the lowest concentration that can cause mild irritation**
- **Squaric acid dibutylester is an alternative in patients who do not develop allergic reaction to DPCP**
- **Treatment should be stopped if there is no improvement after 6 months**
- **The success rate is 50% to 60%, with a relapse rate up to 62% at a median period of 2 and a half years**

Contact sensitizers that have been used in the treatment of AA include dinitrochlorobenzene (DNCB), squaric acid dibutylester (SADBE), and diphenylcyclopropenone (DPCP). DNCB is not generally used today because it has been shown to be mutagenic in the Ames test.^{33,34} DPCP is the topical sensitizer of choice because SADBE is not stable in acetone.^{3,35,36} Because DPCP is very light sensitive, it should be stored in amber bottles to protect it from exposure to ultraviolet light.³⁵ The most important negative prognostic factors in the treatment of AA with DPCP are disease severity, duration of AA before therapy, and presence of nail changes.^{37,38} Other factors include age at onset, atopy, and a family history of AA.³⁹⁻⁴³ Full information regarding therapy should be given to the patient, and signed informed consent should be obtained from the patient before beginning treatment.

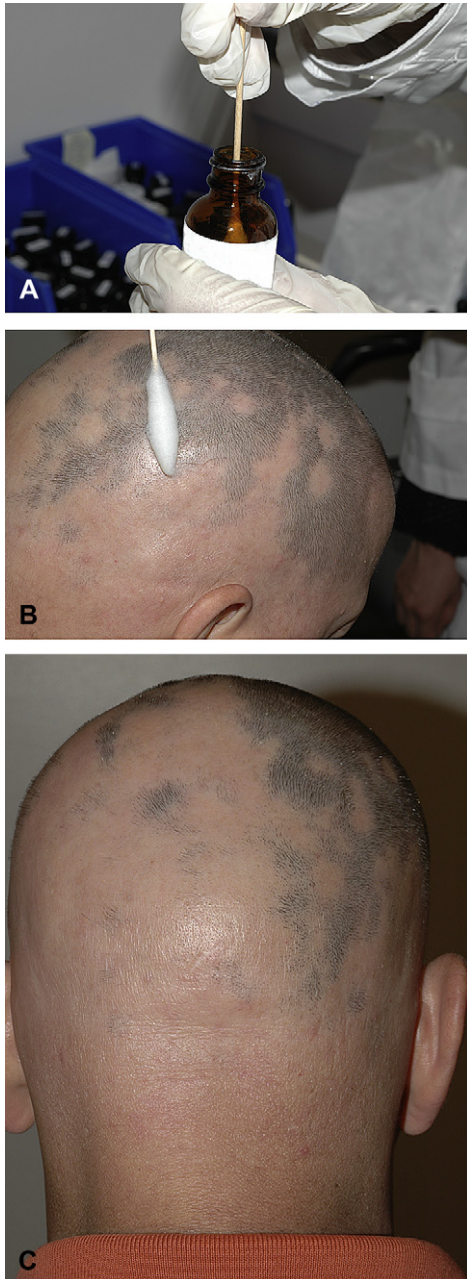


Fig 1. Diphenylcyclopropenone application. **A**, A cotton swab is dipped directly into the bottle. **B**, One side of the scalp is painted with two diphenylcyclopropenone coatings (anteroposterior and lateral). **C**, Hair growth improvement in the treated side. Note that some patches are refractory to treatment.

Initially, 2% DPCP in acetone is applied to a 4- × 4-cm circular area of the scalp to sensitize the patient. Two weeks later, a 0.001% DPCP solution is applied to the same half of the scalp (Fig 1). The concentration of DPCP is increased gradually each week until a mild dermatitis reaction is obtained. The goal is to achieve a low-grade erythema and mild pruritus on

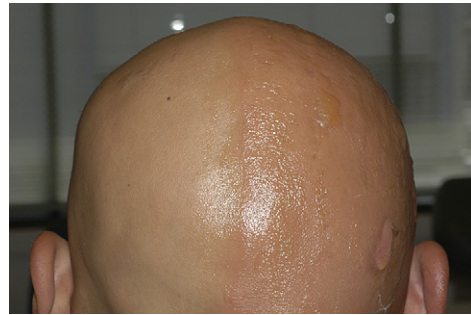

Fig 2. Vesiculobullous reaction on the treated side that occurred after increasing diphenylcyclopropenone concentration.

the treated area for 24 to 36 hours after application.⁴⁴ After establishing the appropriate concentration for the patient, therapy should be continued on a weekly basis. DPCP should be left on the scalp for 48 hours and then washed off. Patients should not expose the treated area to the sun during this time.

Treatment of both sides is recommended only after achieving a trichogenic response on the treated side. Usually, there is a lag of approximately 3 months from initiation of therapy to the initial hair regrowth, and up to 12 months to see cosmetically acceptable results.³⁸ For practical purposes, if there is no improvement at 6 months, DPCP is less likely to be successful. If the patient does not develop an allergic reaction to 2% DPCP, SADBE can be tried.^{45,46}

A mild eczematous reaction is intrinsic to therapy, but a vesicular or bullous reaction is one of the undesired adverse effects of topical sensitizers (Fig 2).^{38,47} If this reaction develops, the patient should wash off the contact sensitizer and a topical corticosteroid should be applied to the affected area. Other adverse effects include cervical and occipital lymphadenopathy,^{41,48} facial and scalp edema, contact urticaria,⁴⁹⁻⁵¹ flu-like symptoms, erythema multiforme-like reactions,^{41,52} and pigmentary disturbances (hyperpigmentation, hypopigmentation, dyschromia in confetti, and even vitiligo).^{48,53,54} Darker skinned patients are more predisposed to these pigmentary changes. Although DPCP has not been shown to be teratogenic, as a precaution, pregnant women should not use it. At the University of British Columbia Hair Clinic, six women have become pregnant while on treatment despite the fact that they were warned and signed an informed consent. However, all babies were normal.

Although there are no randomized controlled trials with DNCB or DPCP, unilateral scalp hair regrowth on the treated side argues against hair regrowth related to spontaneous remission. The success rate of DPCP and SADBE is about 50% to 60% (range, 9-87%).⁵⁵ However, the response rate of

AT/AU patients was 17.4% in the largest published DPCP trial.³⁸ The relapse rate was 62%, with median time to relapse being 2 and a half years.³⁸ Thirty-eight percent of patients maintained good hair regrowth at mean follow-up period of 31 months in two long-term studies.^{38,41}

Many theories have been suggested for the mechanism of action of topical sensitizers. These include antigenic competition,⁵⁶ perifollicular lymphocytes apoptosis,⁵⁷ and changes in the peribular CD4/CD8 lymphocyte ratio (4:1 in untreated progressive AA to 1:1 in DPCP-responding patients).^{58,59} Hoffman et al⁶⁰ hypothesized that interleukin-10 (IL-10) secretion from basal keratinocytes or lesional T cells after DPCP application results in an inhibitory effect on lesional T lymphocytes.⁶⁰ Recent studies with rodent models of AA have indicated significant, specific changes to the immune system response after contact sensitization (see part I of this review).

SYSTEMIC THERAPY

Systemic corticosteroids

Key points

- **Daily, weekly, and monthly pulse corticosteroids have been used with varying success**
- **The use of systemic corticosteroids is limited by their side effect profile and a higher rate of relapse**

Several forms of systemic corticosteroids have been described in the literature with better success rates in multifocal AA and less favorable results with ophiasis and universalis AA.⁶¹ In a placebo-controlled trial of oral prednisolone 200 mg once weekly for 3 months, it was shown that a moderate regrowth of hair (31-60%) was possible in 30% of prednisolone patients.⁶² Ten percent of treated patients had a greater than 60% regrowth rate compared to none of those on the placebo arm. The relapse rate was 25% at the end of the 3-month observation period. In another trial, the long-term benefit of prednisone was not thought to be substantial after a 15-month follow-up period.⁶³ Other ways of administering systemic corticosteroids include alternating daily doses of prednisone,⁶³ oral prednisolone 300 mg once monthly,⁶⁴ tapering of 40 mg prednisone over 6 weeks,⁶⁵ intravenous prednisolone 2 g as single dose,⁶⁶ intravenous methylprednisolone 250 mg twice a day for 3 days,⁶¹ and dexamethasone 5 mg twice weekly for a minimum period of 12 weeks.⁶⁷

Drawbacks to systemic corticosteroids include their adverse effect profile and the high relapse rate after reduction of the dose necessitating a maintenance regimen to preserve the achieved hair

regrowth. The addition of 2% topical minoxidil three times daily may alleviate post-steroid relapse.⁶⁵ The side effects of systemic steroids include hyperglycemia, osteoporosis, cataracts, immunosuppression, obesity, dysmenorrhea, acne, and Cushing syndrome.^{62,68,69} Corticosteroid pulse therapy seems to have less of a side effect profile than daily or alternate day oral regimens.^{61,68}

Photochemotherapy

Key points

- **Systemic and topical psoralen plus ultraviolet A light phototherapy have been used with limited success**
- **Long-term safety, side effects, and a high relapse rate have curtailed the use of psoralen plus ultraviolet A light phototherapy**

The response rates for oral or topical psoralen plus ultraviolet A light (PUVA) phototherapy differ widely, ranging from less than 15% to more than 70% in uncontrolled trials.^{70,71} Two large retrospective studies showed that the response rate is no better than the spontaneous remission rate.^{70,72} Because of the high relapse rates, lack of randomized controlled trials, and the increased risk of skin malignancies with PUVA, this line of therapy has become a less favored treatment option.

Other phototherapies

Key points

- **Excimer laser may be helpful in limited patchy AA**
- **Infrared irradiation as monotherapy or adjunctive to conventional therapy showed some success**
- **Photodynamic therapy is ineffective**

A few case series have shown successful results with 308-nm excimer laser in treating patchy AA.⁷³⁻⁷⁶ The initial fluences were 50 mJ/cm² less than the minimal erythema dose. Fluences were then increased by 50 mJ/cm² every two sessions. Each patch was treated twice a week for a maximum of 24 sessions. Hair regrowth has been shown in 41.5% of patches.⁷⁶ No regrowth of hair was observed in the control patches. Poor results were achieved with AU or AT patients.⁷³ Further randomized controlled studies are required to evaluate the effectiveness of 308-nm excimer laser.

Infrared irradiation using different protocols as monotherapy⁷⁷ or adjunctive to conventional therapy⁷⁸ was tried with some success. Larger randomized controlled trials are needed to confirm its efficacy.

Photodynamic therapy was shown to be ineffective in the treatment of AA patients.^{79,80}

MISCELLANEOUS

Cyclosporine

Key points

- **Cyclosporine has been used alone or in conjunction with corticosteroids with a success rate up to 76.6%**
- **Cyclosporine use is limited by its side effects and high relapse rate**

Cyclosporine is an immunosuppressant agent that inhibits helper T-cell activation and suppresses interferon gamma (IFN- γ) production. Success rates with oral cyclosporine range from 25% in some trials⁸¹ to 76.7% in others if combined with methylprednisolone.⁸² Notably, however, AA has been reported in several organ transplant patients who were taking cyclosporine.⁸³⁻⁸⁶ Because of its adverse effect profile (especially nephrotoxicity, immune suppression, and hypertension), high relapse rate, and the need for long-term treatment, its use is not generally recommended.

Although no beneficial response has been observed by using topical cyclosporine in humans,^{87,88} Verma et al⁸⁹ showed good hair regrowth and reduced inflammation in the Dundee experimental bald rat model using cyclosporine specially formulated in lipid vesicles.⁸⁹ No response was noted in the Dundee experimental bald rat group treated with cyclosporine in ethanol, but further studies in humans are needed to assess the efficacy and safety of this specific formulation.

Methotrexate

Key point

- **Methotrexate in conjunction with low-dose prednisone showed success in 64% of patients with AT/AU in one study**

In a retrospective uncontrolled trial of weekly 20- to 25-mg methotrexate combined with 20 mg/d oral prednisone in 22 AT/AU patients, total recovery occurred in 14 patients (64%).⁹⁰ These results need to be confirmed in randomized controlled studies.

Biologics

Key point

- **Several reports of multiple biologics, including etanercept, efalizumab, adalimumab, and infliximab failed to show improvement in AA**

Because AA is considered a T-cell mediated autoimmune disease, several biologic drugs have been investigated in the treatment of AA. In a

prospective, open-label pilot study, Strober et al⁹¹ showed that etanercept, a TNF- α inhibitor, is not effective in treating moderate to severe AA. A placebo-controlled trial of subcutaneous efalizumab, an anti-CD11a antibody, in 62 patients for 3 to 6 months did not show statistical differences between the efalizumab and placebo groups.⁹² There are a few reported cases that have shown either development of AA or complete failure to respond to different TNF- α antibodies, including adalimumab,⁹³⁻⁹⁶ infliximab,^{97,98} and etanercept.⁹⁹⁻¹⁰¹ Higher doses, longer therapy periods, or longer follow-up may be needed.

Sulfasalazine

Key points

- **Sulfasalazine up to 1.5 g twice daily is successful in about quarter of the patients**
- **The relapse rate is 45.5%**
- **One in three patients may have side effects**

Sulfasalazine has both immunomodulatory and immunosuppressive actions, including inhibition of T cell proliferation, natural killer cell activity, and antibody production. Sulfasalazine also inhibits the T cell cytokines IL-2 and IFN- γ and the monocyte/macrophage cytokines IL-1, TNF- α , and IL-6.¹⁰² A few case series have shown some improvement of AA after using sulfasalazine. Ellis et al¹⁰³ reported cosmetically acceptable hair regrowth in 23% of patients in a retrospective study. In an uncontrolled open-label study of sulfasalazine in 22 patients with severe AA, complete hair regrowth was shown in 27.3%.¹⁰⁴ Sulfasalazine was started at 0.5 g twice daily for 1 month, 1 g twice daily for 1 month, and then 1.5 g twice daily for 4 months. The relapse rate was 45.5%. Thirty-two percent of patients suffered from adverse effects, which included gastrointestinal distress, rash, headache, and laboratory abnormalities. A similar response rate (25.6%) was shown in another uncontrolled trial of 39 AA patients.¹⁰⁵

Prostaglandin analogues

Key point

- **Prostaglandin analogues failed to show hair regrowth in AA**

Latanoprost, a prostaglandin F 2α analogue, and bimatoprost, a synthetic prostamide F 2α analogue, are used to reduce intraocular pressure in open angle glaucoma patients. Eyelash hypertrichosis is a common adverse effect of their use that has been confirmed in murine hair follicle studies.¹⁰⁶⁻¹⁰⁹ Prostaglandin F 2α and its analogue showed stimulatory effects on murine hair follicles and follicular

melanocytes in telogen and anagen phases and enhanced the conversion from the telogen to the anagen stage.¹¹⁰

In December 2008, bimatoprost ophthalmic solution (Latisse; Allergan, Inc, Irvine, CA) received approval from the US Food and Drug Administration for the treatment of hypotrichosis of the eyelashes. Unfortunately, a blinded, randomized controlled trial of 11 AA patients with more than 50% bilateral eyelash loss did not reveal appreciable eyelash growth with either topical latanoprost or with bimatoprost ophthalmic solutions.¹¹¹ The lack of efficacy of topical latanoprost was shown in another 16-week randomized, right-left, investigator-blinded study of eight patients with severe eyebrow AA.¹¹² Higher concentrations, increased application frequency, prolongation of treatment duration, and change of vehicle may be tried in large groups of patients to evaluate the efficacy of these new drugs. Treatment is well tolerated apart from mild erythema and itching in a few patients.¹¹¹

Topical calcineurin inhibitors

Key point

- **The use of topical calcineurin inhibitors in AA was unsuccessful**

Topical tacrolimus and pimecrolimus have been tried in several case series in the treatment of AA, but the results have not been encouraging.¹¹³⁻¹¹⁷ Treatment failure with topical tacrolimus 0.1% may be caused by insufficient depth of penetration of the ointment formulation and less than optimal patient selection. Higher concentrations of tacrolimus ointment and large scale randomized controlled trials are needed.

Bexarotene

Key points

- **In a single recently published study, bexarotene 1% gel resulted in a 26% hair regrowth rate**
- **Dermal irritation is a common side effect**

Bexarotene 1% gel treatment on half head was evaluated in a single blinded study involving 42 patients with AA.¹¹⁸ Five patients (12%) had 50% or more partial regrowth on the treated side, and six patients (14%) had a response on both sides.¹¹⁸ Some degree of dermal irritation was experienced by 73% of the patients.¹¹⁸ The mechanism of action is thought to be through immunomodulation and induction of T-cell apoptosis.¹¹⁸ The efficacy of bexarotene needs to be confirmed in randomized, placebo-controlled trials.

Capsaicin

Key points

- **Capsaicin was previously shown to induce vellus hair regrowth in AA**
- **More recently, a study showed that topical capsaicin and clobetasol 0.05% are comparable**

The idea of using capsaicin in AA emerged from the theory of nervous system and neuropeptide role in the development of the disease. Capsaicin can release substance P (SP) and calcitonin gene-related peptide (CGRP), and after repeated application, it depletes neurons of SP.¹¹⁹ Capsaicin cream 0.075% resulted in vellus hair regrowth in two patients after 3 weeks of treatment.¹²⁰ Both patients had burning pain sensation with treatment.¹²⁰ In a recent non-blinded study, 50 patients with patchy AA were randomized to receive treatment with capsaicin ointment or clobetasol 0.05% ointment for 6 weeks. Vellus hair regrowth was noted as early as the second week of treatment, and a cosmetically acceptable regrowth was seen in 9.5% of patients at week 12 in both groups.¹¹⁹ Only one patient experienced an eczematous reaction from the capsaicin ointment.¹¹⁹ These results should be supported by randomized, placebo-controlled trials before capsaicin use is added to our AA therapeutic armamentarium.

Fractional photothermolysis laser

Key point

- **Complete hair regrowth in one patient who was not responding to conventional therapy has been reported**

A single case report of a 35-year-old male patient who had AA for 2 years and who was nonresponsive to treatment with minoxidil, topical corticosteroids, and ILCs had complete regrowth after multiple sessions with fractional Er:Glass laser.¹²¹ Hair growth was noted as early as 1 month, and complete regrowth was achieved at 6 months.¹²¹ No hair loss was reported in the 6-month follow-up period.¹²¹ No side effects were reported.¹²¹ The mechanism of action is thought to involve the induction of T-cell apoptosis and direct enhancement of hair growth.¹²¹ This report sheds some light on, and stimulates the research of, the role of this fairly new technology in AA treatment.

Psychosocial support

Key points

- **There is a need for larger randomized controlled trials to evaluate the use of antidepressants in AA**

- **Support groups are invaluable in helping patients coping with their disease and achieving a better quality of life**

AA is associated with high psychiatric comorbidities (mainly adjustment disorder, generalized anxiety disorder, and depressive disorders).¹²² The efficacy of antidepressants in AA treatment has not been evaluated by large-scale randomized control trials. In a small trial of eight AA patients treated with 20 mg paroxetine, a selective serotonin reuptake inhibitor (SSRI), and five patients with placebo for 3 months, complete hair regrowth was observed in two patients in the paroxetine group versus one patient in the placebo arm. Four patients in the paroxetine group showed partial hair regrowth.¹²³ Willemssen et al¹²⁴ showed 75% to 100% hair regrowth in 12 of 21 patients with extensive AA after three to eight sessions of hypnotherapy. In the follow-up period (ranging from 4 months to 4 years), the relapse rate was 42%.¹²⁴ The small sample size and less than optimum hair regrowth assessment make the evaluation of some trials of antidepressants difficult.

Support groups that involve regular meetings of AA patients and family members can be an invaluable resource for them. Patients can derive emotional support and information that can help them develop positive coping strategies, overall improved quality of life, and increased treatment compliance. The National Alopecia Areata Foundation (www.naaf.org) provides patients and physicians with brochures, research updates, bimonthly newsletters, a pen pal program, sources for scalp prostheses, and many patient conferences. Also, the NAAF supports research and research workshops that add to the scientific knowledge about AA.

MANAGEMENT PLAN

At the patient's first visit, a careful medical history and a good physical examination should be carried out, including an examination of all hair-bearing areas and nails. Full information about his or her disease, including the relapsing nature of AA, prognosis, and risk/benefit ratio of treatment options, should be provided. It is important that the physician spends enough time with the patient to answer his or her questions and to address the psychosocial effects of AA, because this affects a physician's selection of treatment options.

Because of the possibility of spontaneous remission in 34% to 50% of patients within 1 year,³⁰ no single treatment is an option to offer to all patients. However, most AA patients are highly motivated and want treatment. Treatment options are offered according to a patient's age and extent of the disease (Fig 3).

For children less than 10 years of age, a combination of 5% minoxidil solution twice daily with a midpotent topical corticosteroid is the first line of therapy. If there is no response after 6 months, short-contact anthralin can be tried. For patients older than 10 years of age with less than 50% scalp involvement, intralesional injections of triamcinolone acetonide is the authors' first option for therapy. If there is no improvement after 6 months, other therapeutic options can be offered, including 5% topical minoxidil twice a day, potent topical corticosteroid under occlusion at night, and short-contact anthralin.

For those with more than 50% scalp involvement, topical immunotherapy with DPCP is the treatment of choice. For those patients who only partially respond, intralesional triamcinolone acetonide injections are used to treat the resistant alopecic patches. DPCP may be discontinued if there is no response by 6 months of treatment. Alternative remedies include 5% minoxidil solution, topical clobetasol propionate nightly under occlusion, or short-contact anthralin. Minoxidil 5% solution with or without intralesional injections of triamcinolone acetonide 2.5 mg/cc (maximum, 1 cc) can be administered to AA of the eyebrows. Dermatography or medical tattooing of the eyebrows may be suggested to AA patients with prolonged eyebrow loss. Scalp prostheses, such as wigs, hairpieces, or other scalp coverings, may be valuable options for AA patients during treatment or when treatment fails.⁴

FUTURE DIRECTIONS

Vitamin D

1, 25-dihydroxycholecalciferol [1, 25(OH)₂D₃] is the biologic active form of the vitamin D₃.¹²⁵ Vitamin D has a multitude of biologic effects interacting with the innate and adaptive immune system, mainly leading to its downregulation.¹²⁶ It regulates the differentiation of B cells, T cells, dendritic cells, and the expression of Toll-like receptors.¹²⁶ There is growing evidence that vitamin D may help in several autoimmune diseases like multiple sclerosis and type I diabetes mellitus,¹²⁷ lupus,¹²⁸ and rheumatoid arthritis.¹²⁹ The relation between vitamin D levels and the development of AA and whether vitamin D supplementation helps in the treatment of AA represent an attractive area of research, the results of which may prove that vitamin D is a safe and helpful choice in AA treatment.

Immunomodulators from parasites

The incidence of allergic and autoimmune diseases is increasing in developed countries compared to developing ones where there is a higher rate of nematode parasitic infections.¹³⁰ Human infection

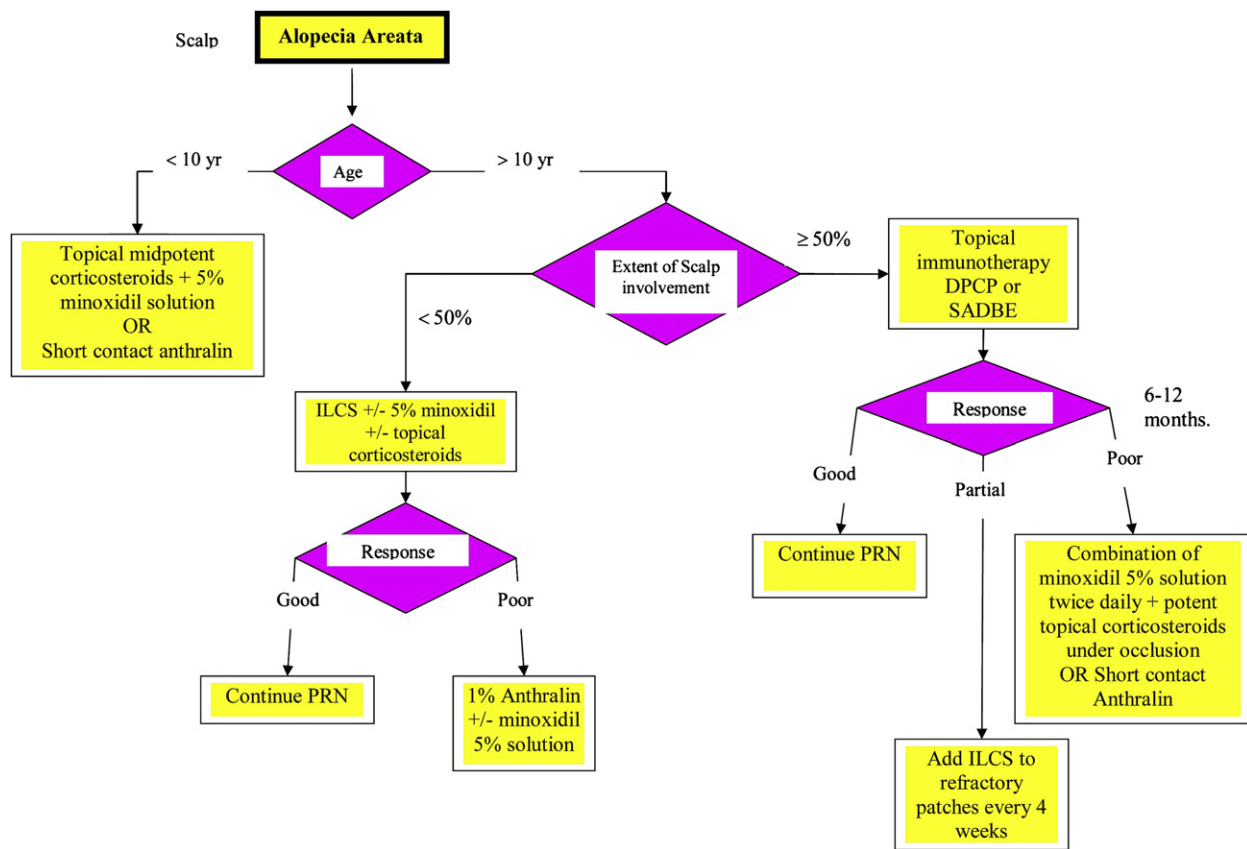


Fig 3. Treatment algorithm for alopecia areata involving the scalp. *DPCP*, Diphenylcyclopropenone; *ILCS*, intralesional corticosteroids; *PRN*, as needed; *SADBE*, squaric acid dibutylester.

results in decreased production of the cytokine IFN- γ , but increased production of the cytokines IL-4 and IL-10 and the antibody type IgG4, a type 2 T-helper (T_H2) cell response.¹³⁰ This shift may change the susceptibility to T_H1 -associated immune responses, such as cell-mediated autoimmune diseases.¹³⁰ The production of harmless nematode antigen that is able to elicit such a response may have some value in treating autoimmune diseases, including AA.

Ustekinumab

Ustekinumab is a fully human monoclonal antibody to the shared p40 subunit of IL-12 and IL-23.¹³¹ IL-12 is the key effector cytokine in commitment to a T_H1 response.¹³¹ IL-23 is a newly discovered cytokine that is thought to play an important role in linking the innate and adaptive arms of the immune response.¹³¹ Ustekinumab was proven to be efficacious in plaque psoriasis, and studies are ongoing to assess the long-term efficacy and safety.¹³¹ Ustekinumab may be tried on AA patients in the future.

There are many potential immunoregulatory treatments being developed that may be adapted for the treatment of AA.

SUMMARY

There has been little progress in the treatment of AA in the past decade, and ILCSs are still the preferred method of treatment for most patients. Newer topical and systemic agents (eg, biologics) have been tried, but the outcomes have been unattractive. We are still in need of developing treatment options for refractory cases and for specific hair-bearing sites (ie, eyelashes) where treatment choices are almost nonexistent. Because of higher psychiatric morbidity in patients with AA, psychosocial support is a valuable tool in any management plan.

REFERENCES

1. Delamere FM, Sladden MM, Dobbins HM, Leonardi-Bee J. Interventions for alopecia areata. *Cochrane Database Syst Rev* 2008;2: CD004413.
2. Olsen EA, Hordinsky MK, Price VH, Roberts JL, Shapiro J, Canfield D, et al. Alopecia areata investigational assessment guidelines—part II. National Alopecia Areata Foundation. *J Am Acad Dermatol* 2004;51:440-7.
3. Garg S, Messenger AG. Alopecia areata: evidence-based treatments. *Semin Cutan Med Surg* 2009;28:15-8.
4. Abell E, Munro DD. Intralesional treatment of alopecia areata with triamcinolone acetonide by jet injector. *Br J Dermatol* 1973;88:55-9.

5. Porter D, Burton JL. A comparison of intra-lesional triamcinolone hexacetonide and triamcinolone acetonide in alopecia areata. *Br J Dermatol* 1971;85:272-3.
6. Sohn KC, Jang S, Choi DK, Lee YS, Yoon TJ, Jeon EK, et al. Effect of thioredoxin reductase 1 on glucocorticoid receptor activity in human outer root sheath cells. *Biochem Biophys Res Commun* 2007;356:810-5.
7. Charuwichitratana S, Wattanakrai P, Tanrattanakorn S. Randomized double-blind placebo-controlled trial in the treatment of alopecia areata with 0.25% desoximetasone cream. *Arch Dermatol* 2000;136:1276-7.
8. Mancuso G, Balducci A, Casadio C, Farina P, Staffa M, Valenti L, et al. Efficacy of betamethasone valerate foam formulation in comparison with betamethasone dipropionate lotion in the treatment of mild-to-moderate alopecia areata: a multicenter, prospective, randomized, controlled, investigator-blinded trial. *Int J Dermatol* 2003;42:572-5.
9. Tosti A, Piraccini BM, Pazzaglia M, Vincenzi C. Clobetasol propionate 0.05% under occlusion in the treatment of alopecia totalis/universalis. *J Am Acad Dermatol* 2003;49:96-8.
10. Tosti A, Iorizzo M, Botta GL, Milani M. Efficacy and safety of a new clobetasol propionate 0.05% foam in alopecia areata: a randomized, double-blind placebo-controlled trial. *J Eur Acad Dermatol Venereol* 2006;20:1243-7.
11. Pascher F, Kurtin S, Andrade R. Assay of 0.2 percent fluocinolone acetonide cream for alopecia areata and totalis. Efficacy and side effects including histologic study of the ensuing localized acneiform response. *Dermatologica* 1970;141:193-202.
12. Wester RC, Maibach HI, Guy RH, Novak E. Minoxidil stimulates cutaneous blood flow in human balding scalps: pharmacodynamics measured by laser Doppler velocimetry and photopulse plethysmography. *J Invest Dermatol* 1984;82:515-7.
13. Bunker CB, Dowd PM. Alterations in scalp blood flow after the epicutaneous application of 3% minoxidil and 0.1% hexyl nicotinate in alopecia. *Br J Dermatol* 1987;117:668-9.
14. Lachgar S, Charveron M, Gall Y, Bonafe JL. Minoxidil upregulates the expression of vascular endothelial growth factor in human hair dermal papilla cells. *Br J Dermatol* 1998;138:407-11.
15. Uno H, Capps A, Brigham P. Action of topical minoxidil in the bald stump-tailed macaque. *J Am Acad Dermatol* 1987;16:657-68.
16. Mori O, Uno H. The effect of topical minoxidil on hair follicular cycles of rats. *J Dermatol* 1990;17:276-81.
17. Buhl AE, Waldon DJ, Conrad SJ, Mulholland MJ, Shull KL, Kubicek MF, et al. Potassium channel conductance: a mechanism affecting hair growth both in vitro and in vivo. *J Invest Dermatol* 1992;98:315-9.
18. Messenger AG, Rundegren J. Minoxidil: mechanisms of action on hair growth. *Br J Dermatol* 2004;150:186-94.
19. Galbraith GM, Thiers BH. In vitro suppression of human lymphocyte activity by minoxidil. *Int J Dermatol* 1985;24:249-51.
20. Fiedler-Weiss VC. Potential mechanisms of minoxidil-induced hair growth in alopecia areata. *J Am Acad Dermatol* 1987;16:653-6.
21. Price VH. Double-blind, placebo-controlled evaluation of topical minoxidil in extensive alopecia areata. *J Am Acad Dermatol* 1987;16:730-6.
22. Fiedler-Weiss VC. Topical minoxidil solution (1% and 5%) in the treatment of alopecia areata. *J Am Acad Dermatol* 1987;16:745-8.
23. Price VH. Topical minoxidil (3%) in extensive alopecia areata, including long-term efficacy. *J Am Acad Dermatol* 1987;16:737-44.
24. Olsen EA, Dunlap FE, Funicella T, Koperski JA, Swinehart JM, Tschen EH, et al. A randomized clinical trial of 5% topical minoxidil versus 2% topical minoxidil and placebo in the treatment of androgenetic alopecia in men. *J Am Acad Dermatol* 2002;47:377-85.
25. Olsen EA, Whiting D, Bergfeld W, Miller J, Hordinsky M, Wanser R, et al. A multicenter, randomized, placebo-controlled, double-blind clinical trial of a novel formulation of 5% minoxidil topical foam versus placebo in the treatment of androgenetic alopecia in men. *J Am Acad Dermatol* 2007;57:767-74.
26. Lucky AW, Piacquadio DJ, Ditre CM, Dunlap F, Kantor I, Pandya AG, et al. A randomized, placebo-controlled trial of 5% and 2% topical minoxidil solutions in the treatment of female pattern hair loss. *J Am Acad Dermatol* 2004;50:541-53.
27. Schmoeckel C, Weissmann I, Plewig G, Braun-Falco O. Treatment of alopecia areata by anthralin-induced dermatitis. *Arch Dermatol* 1979;115:1254-5.
28. Fiedler-Weiss VC, Buys CM. Evaluation of anthralin in the treatment of alopecia areata. *Arch Dermatol* 1987;123:1491-3.
29. Tang L, Cao L, Sundberg JP, Lui H, Shapiro J. Restoration of hair growth in mice with an alopecia areata-like disease using topical anthralin. *Exp Dermatol* 2004;13:5-10.
30. MacDonald Hull SP, Wood ML, Hutchinson PE, Sladden M, Messenger AG. Guidelines for the management of alopecia areata. *Br J Dermatol* 2003;149:692-9.
31. Fiedler VC, Wendrow A, Szpunar GJ, Metzler C, DeVillez RL. Treatment-resistant alopecia areata. Response to combination therapy with minoxidil plus anthralin. *Arch Dermatol* 1990;126:756-9.
32. Sasmaz S, Arican O. Comparison of azelaic acid and anthralin for the therapy of patchy alopecia areata: a pilot study. *Am J Clin Dermatol* 2005;6:403-6.
33. Strobel R, Rohrborn G. Mutagenic and cell transforming activities of 1-chloro-2,4-dinitrobenzene (DNCB) and squaric acid-dibutylester (SADBE). *Arch Toxicol* 1980;45:307-14.
34. Summer KH, Goggelmann W. 1-chloro-2,4-dinitrobenzene depletes glutathione in rat skin and is mutagenic in *Salmonella typhimurium*. *Mutat Res* 1980;77:91-3.
35. Wilkerson MG, Henkin J, Wilkin JK. Diphenylcyclopropenone: examination for potential contaminants, mechanisms of sensitization, and photochemical stability. *J Am Acad Dermatol* 1984;11:802-7.
36. Wilkerson MG, Henkin J, Wilkin JK, Smith RG. Squaric acid and esters: analysis for contaminants and stability in solvents. *J Am Acad Dermatol* 1985;13:229-34.
37. van der Steen PH, van Baar HM, Happle R, Boezeman JB, Perret CM. Prognostic factors in the treatment of alopecia areata with diphenylcyclopropenone. *J Am Acad Dermatol* 1991;24:227-30.
38. Wiseman MC, Shapiro J, MacDonald N, Lui H. Predictive model for immunotherapy of alopecia areata with diphenylcyclopropenone. *Arch Dermatol* 2001;137:1063-8.
39. Weise K, Kretzschmar L, John SM, Hamm H. Topical immunotherapy in alopecia areata: anamnestic and clinical criteria of prognostic significance. *Dermatology* 1996;192:129-33.
40. Galadari I, Rubaie S, Alkaabi J, Galadari H. Diphenylcyclopropenone (diphencyprone, DPCP) in the treatment of chronic severe alopecia areata (AA). *Eur Ann Allergy Clin Immunol* 2003;35:397-401.
41. Gordon PM, Aldrige RD, McVittie E, Hunter JA. Topical diphenylcyclopropenone for alopecia areata: evaluation of 48 cases after 30 months' follow-up. *Br J Dermatol* 1996;134:869-71.
42. Tosti A, Bellavista S, Iorizzo M. Alopecia areata: a long term follow-up study of 191 patients. *J Am Acad Dermatol* 2006;55:438-41.
43. McElwee K, Freyschmidt-Paul P, Ziegler A, Happle R, Hoffmann R. Genetic susceptibility and severity of alopecia areata in human and animal models. *Eur J Dermatol* 2001;11:11-6.

44. Orecchia G, Perfetti L. Alopecia areata and topical sensitizers: allergic response is necessary but irritation is not. *Br J Dermatol* 1991;124:509.
45. Orecchia G, Malagoli P, Santagostino L. Treatment of severe alopecia areata with squaric acid dibutylester in pediatric patients. *Pediatr Dermatol* 1994;11:65-8.
46. Dall'oglio F, Nasca MR, Musumeci ML, La Torre G, Ricciardi G, Potenza C, et al. Topical immunomodulator therapy with squaric acid dibutylester (SADBE) is effective treatment for severe alopecia areata (AA): results of an open-label, paired-comparison, clinical trial. *J Dermatolog Treat* 2005;16:10-4.
47. Aghaei S. Topical immunotherapy of severe alopecia areata with diphenylcyclopropenone (DPCP): experience in an Iranian population. *BMC Dermatol* 2005;5:6.
48. Sotiriadis D, Patsatsi A, Lazaridou E, Kastanis A, Vakirlis E, Chrysomallis F. Topical immunotherapy with diphenylcyclopropenone in the treatment of chronic extensive alopecia areata. *Clin Exp Dermatol* 2007;32:48-51.
49. Francomano M, Seidenari S. Urticaria after topical immunotherapy with diphenylcyclopropenone. *Contact Dermatitis* 2002;47:310-1.
50. Alam M, Gross EA, Savin RC. Severe urticarial reaction to diphenylcyclopropenone therapy for alopecia areata. *J Am Acad Dermatol* 1999;40:110-2.
51. Tosti A, Guerra L, Bardazzi F. Contact urticaria during topical immunotherapy. *Contact Dermatitis* 1989;21:196-7.
52. Perret CM, Steijlen PM, Zaun H, Happle R. Erythema multiforme—like eruptions: a rare side effect of topical immunotherapy with diphenylcyclopropenone. *Dermatologica* 1990;180:5-7.
53. Pan JY, Theng C, Lee J, Goh BK. Vitiligo as an adverse reaction to topical diphenylcyclopropenone. *Ann Acad Med Singapore* 2009;38:276-7.
54. Henderson CA, Ilchshyn A. Vitiligo complicating diphenylcyclopropenone sensitization therapy for alopecia universalis. *Br J Dermatol* 1995;133:496-7.
55. Rokhsar CK, Shupack JL, Vafai JJ, Washenik K. Efficacy of topical sensitizers in the treatment of alopecia areata. *J Am Acad Dermatol* 1998;39:751-61.
56. Happle R. Antigenic competition as a therapeutic concept for alopecia areata. *Arch Dermatol Res* 1980;267:109-14.
57. Herbst V, Zoller M, Kissling S, Wenzel E, Stutz N, Freyschmidt-Paul P. Diphenylcyclopropenone treatment of alopecia areata induces apoptosis of perifollicular lymphocytes. *Eur J Dermatol* 2006;16:537-42.
58. Happle R, Klein HM, Macher E. Topical immunotherapy changes the composition of the peribulbar infiltrate in alopecia areata. *Arch Dermatol Res* 1986;278:214-8.
59. Wasylszyn T, Kozlowski W, Zabielski SL. Changes in distribution pattern of CD8 lymphocytes in the scalp in alopecia areata during treatment with diphenylcyclopropenone. *Arch Dermatol Res* 2007;299:231-7.
60. Hoffmann R, Wenzel E, Huth A, van der Steen P, Schaufele M, Henninger HP, et al. Cytokine mRNA levels in Alopecia areata before and after treatment with the contact allergen diphenylcyclopropenone. *J Invest Dermatol* 1994;103:530-3.
61. Friedli A, Labarthe MP, Engelhardt E, Feldmann R, Salomon D, Saurat JH. Pulse methylprednisolone therapy for severe alopecia areata: an open prospective study of 45 patients. *J Am Acad Dermatol* 1998;39:597-602.
62. Kar BR, Handa S, Dogra S, Kumar B. Placebo-controlled oral pulse prednisolone therapy in alopecia areata. *J Am Acad Dermatol* 2005;52:287-90.
63. Winter RJ, Kern F, Blizzard RM. Prednisone therapy for alopecia areata. A follow-up report. *Arch Dermatol* 1976;112:1549-52.
64. Sharma VK. Pulsed administration of corticosteroids in the treatment of alopecia areata. *Int J Dermatol* 1996;35:133-6.
65. Olsen EA, Carson SC, Turney EA. Systemic steroids with or without 2% topical minoxidil in the treatment of alopecia areata. *Arch Dermatol* 1992;128:1467-73.
66. Burton JL, Shuster S. Large doses of glucocorticoid in the treatment of alopecia areata. *Acta Derm Venereol* 1975;55:493-6.
67. Sharma VK, Gupta S. Twice weekly 5 mg dexamethasone oral pulse in the treatment of extensive alopecia areata. *J Dermatol* 1999;26:562-5.
68. Kurosawa M, Nakagawa S, Mizuashi M, Sasaki Y, Kawamura M, Saito M, et al. A comparison of the efficacy, relapse rate and side effects among three modalities of systemic corticosteroid therapy for alopecia areata. *Dermatology* 2006;212:361-5.
69. Lester RS, Knowles SR, Shear NH. The risks of systemic corticosteroid use. *Dermatol Clin* 1998;16:277-88.
70. Taylor CR, Hawk JL. PUVA treatment of alopecia areata partialis, totalis and universalis: audit of 10 years' experience at St John's Institute of Dermatology. *Br J Dermatol* 1995;133:914-8.
71. Mohamed Z, Bhouri A, Jallouli A, Faza'a B, Kamoun MR, Mokhtar I. Alopecia areata treatment with a phototoxic dose of UVA and topical 8-methoxypsoralen. *J Eur Acad Dermatol Venereol* 2005;19:552-5.
72. Healy E, Rogers S. PUVA treatment for alopecia areata—does it work? A retrospective review of 102 cases. *Br J Dermatol* 1993;129:42-4.
73. Zakaria W, Passeron T, Ostovari N, Lacour JP, Ortonne JP. 308-nm excimer laser therapy in alopecia areata. *J Am Acad Dermatol* 2004;51:837-8.
74. Raulin C, Gundogan C, Greve B, Gebert S. Excimer laser therapy of alopecia areata—side-by-side evaluation of a representative area [in German]. *J Dtsch Dermatol Ges* 2005;3:524-6.
75. Gundogan C, Greve B, Raulin C. Treatment of alopecia areata with the 308-nm xenon chloride excimer laser: case report of two successful treatments with the excimer laser. *Lasers Surg Med* 2004;34:86-90.
76. Al-Mutairi N. 308-nm excimer laser for the treatment of alopecia areata. *Dermatol Surg* 2007;33:1483-7.
77. Yamazaki M, Miura Y, Tsuboi R, Ogawa H. Linear polarized infrared irradiation using Super Lizer is an effective treatment for multiple-type alopecia areata. *Int J Dermatol* 2003;42:738-40.
78. Tzung TY, Chen CY, Tzung TY, Kao FJ, Chen WC. Infrared irradiation as an adjuvant therapy in recalcitrant alopecia areata. *Dermatol Surg* 2009;35:721-3.
79. Bissonnette R, Shapiro J, Zeng H, McLean DI, Lui H. Topical photodynamic therapy with 5-aminolevulinic acid does not induce hair regrowth in patients with extensive alopecia areata. *Br J Dermatol* 2000;143:1032-5.
80. Fernández-Guarino M, Harto A, García-Morales I, Pérez-García B, Arrazola JM, Jaén P. Failure to treat alopecia areata with photodynamic therapy. *Clin Exp Dermatol* 2008;33:585-7.
81. Shapiro J, Lui H, Tron V, Ho V. Systemic cyclosporine and low-dose prednisone in the treatment of chronic severe alopecia areata: a clinical and immunopathologic evaluation. *J Am Acad Dermatol* 1997;36:114-7.
82. Kim BJ, Min SU, Park KY, Choi JW, Park SW, Youn SW, et al. Combination therapy of cyclosporine and methylprednisolone on severe alopecia areata. *J Dermatolog Treat* 2008;19:216-20.
83. Phillips MA, Graves JE, Nunley JR. Alopecia areata presenting in 2 kidney-pancreas transplant recipients taking cyclosporine. *J Am Acad Dermatol* 2005;53(5 suppl. 1):S252-5.
84. Dyll-Smith D. Alopecia areata in a renal transplant recipient on cyclosporin. *Australas J Dermatol* 1996;37:226-7.
85. Cerottini JP, Panizzon RG, de Viragh PA. Multifocal alopecia areata during systemic cyclosporine A therapy. *Dermatology* 1999;198:415-7.

86. Davies MG, Bowers PW. Alopecia areata arising in patients receiving cyclosporin immunosuppression. *Br J Dermatol* 1995;132:835-6.
87. Gilhar A, Pillar T, Etzioni A. Topical cyclosporin A in alopecia areata. *Acta Derm Venereol* 1989;69:252-3.
88. Mauduit G, Lenvers P, Barthelemy H, Thivolet J. Treatment of severe alopecia areata with topical applications of cyclosporin A [in French]. *Ann Dermatol Venereol* 1987;114:507-10.
89. Verma DD, Verma S, McElwee KJ, Freyschmidt-Paul P, Hoffman R, Fahr A. Treatment of alopecia areata in the DEBR model using cyclosporin A lipid vesicles. *Eur J Dermatol* 2004;14:332-8.
90. Joly P. The use of methotrexate alone or in combination with low doses of oral corticosteroids in the treatment of alopecia totalis or universalis. *J Am Acad Dermatol* 2006;55:632-6.
91. Strober BE, Siu K, Alexis AF, Kim G, Washenik K, Sinha A, et al. Etanercept does not effectively treat moderate to severe alopecia areata: an open-label study. *J Am Acad Dermatol* 2005;52:1082-4.
92. Price VH, Hordinsky MK, Olsen EA, Roberts JL, Siegfried EC, Rafal ES, et al. Subcutaneous efalizumab is not effective in the treatment of alopecia areata. *J Am Acad Dermatol* 2008;58:395-402.
93. Garcia Bartels N, Lee HH, Worm M, Burmester GR, Sterry W, Blume-Peytavi U. Development of alopecia areata universalis in a patient receiving adalimumab. *Arch Dermatol* 2006;142:1654-5.
94. Kirshen C, Kanigsberg N. Alopecia areata following adalimumab. *J Cutan Med Surg* 2009;13:48-50.
95. Chaves Y, Duarte G, Ben-Said B, Tebib J, Berard F, Nicolas JF. Alopecia areata universalis during treatment of rheumatoid arthritis with anti-TNF-alpha antibody (adalimumab). *Dermatology* 2008;217:380.
96. Pelivani N, Hassan AS, Braathen LR, Hunger RE, Yawalkar N. Alopecia areata universalis elicited during treatment with adalimumab. *Dermatology* 2008;216:320-3.
97. Etefagh L, Nedorost S, Mirmirani P. Alopecia areata in a patient using infliximab: new insights into the role of tumor necrosis factor on human hair follicles. *Arch Dermatol* 2004;140:1012.
98. Fabre C, Dereure O. Worsening alopecia areata and de novo occurrence of multiple halo nevi in a patient receiving infliximab. *Dermatology* 2008;216:185-6.
99. Posten W, Swan J. Recurrence of alopecia areata in a patient receiving etanercept injections. *Arch Dermatol* 2005;141:759-60.
100. Abramovits W, Losornio M. Failure of two TNF-alpha blockers to influence the course of alopecia areata. *Skinmed* 2006;5:177-81.
101. Pan Y, Rao NA. Alopecia areata during etanercept therapy. *Ocul Immunol Inflamm* 2009;17:127-9.
102. Ranganath VK, Furst DE. Disease-modifying antirheumatic drug use in the elderly rheumatoid arthritis patient. *Rheum Dis Clin North Am* 2007;33:197-217.
103. Ellis CN, Brown MF, Voorhees JJ. Sulfasalazine for alopecia areata. *J Am Acad Dermatol* 2002;46:541-4.
104. Aghaei S. An uncontrolled, open label study of sulfasalazine in severe alopecia areata. *Indian J Dermatol Venereol Leprol* 2008;74:611-3.
105. Rashidi T, Mahd AA. Treatment of persistent alopecia areata with sulfasalazine. *Int J Dermatol* 2008;47:850-2.
106. Bearden W, Anderson R. Trichiasis associated with prostaglandin analog use. *Ophthalm Plast Reconstr Surg* 2004;20:320-2.
107. Tosti A, Pazzaglia M, Voudouris S, Tosti G. Hypertrichosis of the eyelashes caused by bimatoprost. *J Am Acad Dermatol* 2004;51(5 suppl):S149-50.
108. Hart J, Shafranov G. Hypertrichosis of vellus hairs of the malar region after unilateral treatment with bimatoprost. *Am J Ophthalmol* 2004;137:756-7.
109. Herane MI, Urbina F. Acquired trichomegaly of the eyelashes and hypertrichosis induced by bimatoprost. *J Eur Acad Dermatol Venereol* 2004;18:644-5.
110. Sasaki S, Hozumi Y, Kondo S. Influence of prostaglandin F2alpha and its analogues on hair regrowth and follicular melanogenesis in a murine model. *Exp Dermatol* 2005;14:323-8.
111. Roseborough I, Lee H, Chwalek J, Stamper RL, Price VH. Lack of efficacy of topical latanoprost and bimatoprost ophthalmic solutions in promoting eyelash growth in patients with alopecia areata. *J Am Acad Dermatol* 2009;60:705-6.
112. Ross EK, Bolduc C, Lui H, Shapiro J. Lack of efficacy of topical latanoprost in the treatment of eyebrow alopecia areata. *J Am Acad Dermatol* 2005;53:1095-6.
113. Price VH, Willey A, Chen BK. Topical tacrolimus in alopecia areata. *J Am Acad Dermatol* 2005;52:138-9.
114. Thiers BH. Topical tacrolimus: treatment failure in a patient with alopecia areata. *Arch Dermatol* 2000;136:124.
115. Rigopoulos D, Gregoriou S, Korfitis C, Gintzou C, Vergou T, Katrinaki A, et al. Lack of response of alopecia areata to pimecrolimus cream. *Clin Exp Dermatol* 2007;32:456-7.
116. Feldmann KA, Kunte C, Wollenberg A, Wolfe H. Is topical tacrolimus effective in alopecia areata universalis? *Br J Dermatol* 2002;147:1031-2.
117. Park SW, Kim JW, Wang HY. Topical tacrolimus (FK506): treatment failure in four cases of alopecia universalis. *Acta Derm Venereol* 2002;82:387-8.
118. Talpur R, Vu J, Bassett R, Stevens V, Duvic M. Phase I/II randomized bilateral half-head comparison of topical bexarotene 1% gel for alopecia areata. *J Am Acad Dermatol* 2009;61:592.e1-9.
119. Ehsani A, Toosi S, Seirafi H, Akhyani M, Hosseini M, Azadi R, et al. Capsaicin vs. clobetasol for the treatment of localized alopecia areata. *J Eur Acad Dermatol Venereol* 2009 Mar 5 [Epub ahead of print].
120. Hordinsky M, Ericson M. Autoimmunity: alopecia areata. *J Investig Dermatol Symp Proc* 2004;9:73-8.
121. Yoo KH, Kim MN, Kim BJ, Kim CW. Treatment of alopecia areata with fractional photothermolysis laser. *Int J Dermatol* 2009 Jul 13 [Epub ahead of print].
122. Ruiz-Doblado S, Carrizosa A, Garcia-Hernandez MJ. Alopecia areata: psychiatric comorbidity and adjustment to illness. *Int J Dermatol* 2003;42:434-7.
123. Cipriani R, Perini GI, Rampinelli S. Paroxetine in alopecia areata. *Int J Dermatol* 2001;40:600-1.
124. Willemsen R, Vanderlinden J, Deconinck A, Roseeuw D. Hypnotherapeutic management of alopecia areata. *J Am Acad Dermatol* 2006;55:233-7.
125. Meroni P, Tincani A, Alarcon-Riquelme M, Shoenfeld Y, Borghi M. European Forum on Antiphospholipid Antibodies: research in progress. *Lupus* 2009;18:924-9.
126. Nancy AL, Yehuda S. Prediction and prevention of autoimmune skin disorders. *Arch Dermatol Res* 2009;301:57-64.
127. Arnson Y, Amital H, Shoenfeld Y. Vitamin D and autoimmunity: new aetiological and therapeutic considerations. *Ann Rheum Dis* 2007;66:1137-42.
128. Kamen D, Aranow C. Vitamin D in systemic lupus erythematosus. *Curr Opin Rheumatol* 2008;20:532-7.
129. Cutolo M, Otsa K, Uprus M, Paolino S, Seriola B. Vitamin D in rheumatoid arthritis. *Autoimmun Rev* 2007;7:59-64.
130. Harnett W, Harnett MM. Therapeutic immunomodulators from nematode parasites. *Expert Rev Mol Med* 2008;10:e18.
131. O'Neill JL, Kalb RE. Ustekinumab in the therapy of chronic plaque psoriasis. *Biologics* 2009;3:159-68.